

Characteristics of Extra Thoracic Sarcoidosis: A Retrospective Study from Morocco

Boucaid Abdelhalim^{1*}, Baziaa Sara¹, Grine Ali², Belghiti Amine², Balkhi Hicham², Rhorfi Abderahmane Ismail¹

¹Department of Pulmonology, Military Hospital Mohamed V Rabat, Morocco

²Department of Reanimation, Military Hospital Mohamed V Rabat, Morocco

DOI: <https://doi.org/10.36347/sjmcr.2024.v12i12.026>

| Received: 09.11.2024 | Accepted: 12.12.2024 | Published: 17.12.2024

*Corresponding author: Boucaid Abdelhalim

Department of Pulmonology, Military Hospital Mohamed V Rabat, Morocco

Abstract

Original Research Article

Background: Sarcoidosis is a multisystem granulomatous disorder with diverse extra thoracic manifestations requiring systematic evaluation. **Objectives:** To analyse the characteristics and outcomes of extra thoracic manifestations in sarcoidosis patients at Mohamed V Military Hospital, Rabat. **Methods:** Retrospective study of 54 sarcoidosis patients from January 2021 to January 2024. Clinical, biological, radiological, and therapeutic data were analysed. **Results:** Extra thoracic involvement occurred in 16 patients (30%), predominantly female (sex ratio 1/3), mean age 41 ± 7 years. Type II radiographic sarcoidosis was most common (50%). Main manifestations were ocular (16.6%), peripheral lymph nodes (9.25%), and cutaneous (7.4%). Biological findings included elevated ACE (20.4%), leukopenia with lymphopenia (7.4%), and hypercalcemia (3.7%). Treatment comprised corticosteroids (75%), immunosuppressants (12.5%), and antimalarial drugs (12.5%). **Conclusion:** Extra thoracic sarcoidosis presents diverse manifestations requiring vigilant screening. Treatment strategies primarily rely on corticosteroids, with favourable outcomes in most cases.

Keywords: Sarcoidosis, Extra thoracic manifestations, Corticosteroids, Retrospective study.

Copyright © 2024 The Author(s): This is an open-access article distributed under the terms of the Creative Commons Attribution 4.0 International License (CC BY-NC 4.0) which permits unrestricted use, distribution, and reproduction in any medium for non-commercial use provided the original author and source are credited.

INTRODUCTION

While pulmonary involvement predominates in sarcoidosis, extra thoracic manifestations present significant diagnostic and therapeutic challenges. The skin, eyes, and liver comprise the most frequent extra thoracic sites, while cardiac and neurologic involvement carry the highest mortality risk. Recent advances in imaging modalities, particularly gadolinium-enhanced MRI, perfusion scanning, and positron emission tomography, have enhanced detection of cardiac and musculoskeletal involvement [1].

The disease presents in two primary patterns: acute Löfgren's syndrome, characterized by arthritis, mediastinal adenopathy, and erythema nodosum, which typically resolves spontaneously with favourable prognosis; and a chronic form with variable progression. Pulmonary involvement accompanies 80-90% of extrapulmonary cases. Systemic symptoms, including fever, night sweats, weight loss, fatigue, and musculoskeletal complaints, frequently accompany extra thoracic manifestations [2, 3].

The aim of our work is to study the particularities of these extra thoracic manifestations during sarcoidosis.

MATERIAL AND METHOD

This is a retrospective study conducted using data collected over a period of 3 years, from January 2021 to January 2024, 54 patients treated for sarcoidosis in the pneumology department of the Mohamed V military hospital in Rabat, 16 of them had extra-thoracic involvement.

The diagnosis was based on a combination of clinical, biological and radiological factors. Anatomopathological confirmation was performed in 90% of cases.

Extra thoracic manifestations were found in 16 patients (30%), 12 were women and 4 men, i.e. a sex ratio of 1/3, the average age was 41 ± 7 years, 8(50%) patients had type II thoracic sarcoidosis, 4(25%) had type I, 2(12,5%) had type III and 2(12,5%) had type IV (Figure 1).

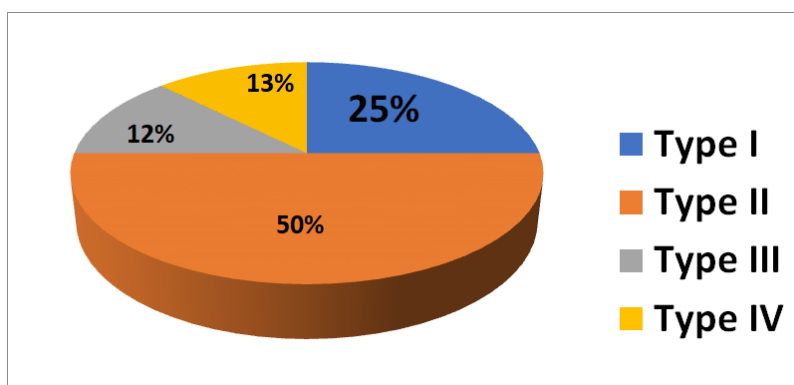


Figure 1: Distribution of patients by radiographic type

The extra thoracic manifestations found were: ocular in 9(16,6%) patients (6 had anterior uveitis, 3 patients had macular oedema); cutaneous in 4(7,4%) cases (3 patients had erythema nodosum and one patient had a subcutaneous nodule); peripheral lymph node in

5(9,25%) cases (cervical in 3 cases, inguinal in 2 cases); accessory salivary glands in 4(7,4%) cases; splenic in 2(3,7%) cases; hepatic in 2(3,7%) cases; prostatic in one(1,85%) case, no Musculo-skeletal, neurologic or cardiac manifestation were found (Table 1).

Figure 1: Extra thoracic manifestations of sarcoidosis in our series

Extra thoracic manifestations	Number of cases (n=54)
Ocular	9(16,6%)
anterior uveitis	6(11,11%)
macular oedema	3(5,55%)
Cutaneous	4(7,4%)
erythema nodosum	3(5,55%)
subcutaneous nodule	1(1,85%)
Peripheral lymph node	5(9,25%)
cervical	3(5,55%)
inguinal	2(3,7%)
Accessory salivary glands	4(7,4%)
Splenic	2(3,7%)
Hepatic	2(3,7%)
Prostatic	1(1,85%)

These extra thoracic locations contributed to the anatomopathological diagnosis of sarcoidosis in 10(18,5%) patients, like lymph node biopsy, liver biopsy, skin biopsy and accessory salivary gland biopsy.

Biologically, we noted leukopenia with lymphopenia in 04 (7,4%) patients, hypercalcaemia in 02(3,7%) patients, and elevated ACE in 11(20,4%) cases.

For those cases with extra thoracic manifestation of sarcoidosis, Treatment was based on corticosteroids in 12(75%) cases, immunosuppressants in 2(12,5%) cases and antimalarial drugs in 2(12,5%) cases. The majority of cases had a favourable outcome.

DISCUSSION

Sarcoidosis is a systemic disease of unknown cause, characterised by the formation of immune granulomas in the affected organs, with a predilection for the lung and lymphatic system [4].

While sarcoidosis predominantly manifests with mediastinal and pulmonary involvement in 90% of cases, the disease can affect multiple organs, these extra-thoracic disorders may be isolated or revelatory, or on the contrary may occur at a later stage, sometimes several years after the onset of sarcoidosis. In our series, ophthalmological, dermatological and peripheral lymph node involvement were the most frequent extrapulmonary localisations [5].

In his study, M. Jebri *et al.*, showed that extra thoracic manifestations were found in 90% vs 30% in our case, superficial adenopathy: 57.8% vs 9,25% in our case, skin involvement was observed in 30.4% vs 7,4% in our case, ophthalmological manifestations were found in 26% vs 16,6% in our case, leukopenia with lymphopenia in 13% vs 7,4% in our case, elevation of angiotensin converting enzyme in 6.5% vs 20,4% in our case [6].

Cardiac and neurologic manifestations represent the most serious extra thoracic complications of sarcoidosis. Cardiac sarcoidosis can present with

conduction abnormalities, arrhythmias, heart failure, or sudden cardiac death, with granulomas potentially affecting any part of the heart. Neuro-sarcoidosis occurs in 5-15% of cases, manifesting as cranial neuropathies (particularly facial nerve palsy), meningitis, hydrocephalus, or mass lesions. Both conditions require aggressive immunosuppression and close monitoring due to their significant morbidity and mortality, in our case no one had cardiac and neurologic manifestation [7, 8].

Diagnostic delays in sarcoidosis frequently stem from its nonspecific initial presentation mimicking common conditions. While chest radiography often proves crucial for diagnosis, patients typically undergo multiple medical consultations over several months before reaching a definitive diagnosis, with an average delay of 7 months in documented cases. This delay underscores the importance of maintaining clinical suspicion for sarcoidosis when evaluating patients with persistent, unexplained symptoms [9].

Sarcoidosis exhibits variable progression, with spontaneous resolution occurring in over 50% of cases within three years. Disease severity manifests through involvement of critical organs (CNS, optic nerve, larynx, heart), intense granulomatous inflammation, fibrotic progression, systemic deterioration, severe hypercalcemia (>3 mmol/l), or treatment resistance. Despite these potential complications, most patients achieve favourable outcomes [10].

Corticosteroid therapy, the standard treatment, and various immunosuppressive treatments usually enable the disease to be controlled thanks to their impact on the granulomatous component of the disease [12, 13].

Treatments only have a suspensory effect, with rebounds in the event of early reduction or interruption. Various organ treatments (oxygen therapy, implantable defibrillator, ventricular bypass, etc.) may be necessary. Lung or other organ transplants may be an option for some patients [14, 15].

CONCLUSION

Extrapulmonary sarcoidosis requires vigilant screening and monitoring due to potentially life-threatening cardiac, neurologic, and renal manifestations. Annual surveillance should include ECG, echocardiogram, ophthalmologic examination, and laboratory monitoring of creatinine and calcium levels.

Clinicians must consider sarcoidosis in the differential diagnosis when evaluating patients presenting with primary cardiac, neurologic, or ocular symptoms, even without known sarcoidosis. Definitive diagnosis requires tissue biopsy demonstrating noncaseating granulomas and exclusion of infectious aetiologies.

Treatment primarily consists of corticosteroids, with demonstrated efficacy in extrapulmonary disease. Immunomodulatory agents serve as alternative therapeutic options for refractory cases.

REFERENCES

- Hunninghake, G. W. (1999). American thoracic society; Statement on sarcoidosis. *Am J Respir Crit Med.*, 160(2), 736-755.
- Judson, M. (2007). Extrapulmonary sarcoidosis. *Semin Respir Crit Care Med*, 28, 83-101.
- Baughman, R. P., Teirstein, A. S., Judson, M. A., Rossman, M. D., Yeager Jr, H., Bresnitz, E. A., ... & GROUP, A. C. C. E. S. O. S. A. R. (2001). Clinical characteristics of patients in a case control study of sarcoidosis. *American journal of respiratory and critical care medicine*, 164(10), 1885-1889.
- Chapelon-Abric, C., de Zuttere, D., Duhaut, P., Veyssier, P., Wechsler, B., de Gennes, C., ... & Piette, J. C. (2004). Cardiac sarcoidosis: a retrospective study of 41 cases. *Medicine*, 83(6), 315-334.
- Hours, S., Nunes, H., Kambouchner, M., Uzunhan, Y., Brauner, M. W., Valeyre, D., & Brillet, P. Y. (2008). Pulmonary cavitary sarcoidosis: clinico-radiologic characteristics and natural history of a rare form of sarcoidosis. *Medicine*, 87(3), 142-151. doi: 10.1097/MD.0b013e3181775a73
- Iannuzzi, M. C., Rybicki, B. A., & Teirstein, A. S. (2007). Medical progress. *Sarcoidosis. N Eng J Med*, 357, 2153-2165. doi: 10.1056/NEJMra071714
- Jebri, M., Kechaou, I., Boukhris, I., Hariz, A., Cherif, E., Azzabi, S., ... & Khalfallah, N. (2016). Les manifestations extrathoraciques au cours de la sarcoïdose. *La Revue de Médecine Interne*, 37, A203. doi:10.1016/j.revmed.2016.10.257
- Birnie, D. H., Sauer, W. H., Bogun, F., Cooper, J. M., Culver, D. A., Duvernoy, C. S., ... & Soejima, K. (2014). HRS expert consensus statement on the diagnosis and management of arrhythmias associated with cardiac sarcoidosis. *Heart rhythm*, 11(7), 1304-1323.
- Stern, B. J. (2018). Neurosarcoidosis: Clinical manifestations, diagnosis, and treatment. *Curr Treat Options Neurol*, 20(6), 19.
- Judson, M. A. (2008). The diagnosis of sarcoidosis. *Clin Chest Med*, 29(3), 415-427.
- Dominique, V., Antje, P., Hilario, N., Yurdagul, U., Pierre-Yves, B., & Müller-Quernheim, J. (2014). Sarcoidosis. *Lancet*, 383(9923), 1155-1167. Epub 2013 Oct 1. doi: 10.1016/S0140-6736(13)60680-7
- Gerke, A. K., & Hunninghake, G. (2008). The immunology of sarcoidosis. *Clinics in chest medicine*, 29(3), 379-390. Doi: 10.1016/j.ccm.2008.03.014
- Baughman, R. P., & Nunes, H. (2012). Therapy for sarcoidosis: evidence-based recommendations. *Expert review of clinical immunology*, 8(1), 95-103. doi: 10.1586/eci.11.84

14. Dominique, V., Antje, P., Hilario, N., Yurdagul, U., Pierre-Yves, B., & Müller-Quernheim, J. (2014). Sarcoidosis, *Lancet*, 383(9923), 1155-1167. Epub 2013 Oct 1. doi: 10.1016/S0140-6736(13)60680-7
15. Baughman, R. P., & Nunes, H. (2012). Therapy for sarcoidosis: evidence-based recommendations. *Expert review of clinical immunology*, 8(1), 95-103. doi: 10.1586/eci.11.84