

## Dedifferentiated Liposarcoma of Kidney: A Rare Entity

M. Tbouda<sup>1\*</sup>, A. Mery<sup>2</sup>, H. Aggouri<sup>1</sup>, Z. Toufga<sup>3</sup>, O. Jendouzi<sup>4</sup>, S. Abbaoui<sup>2</sup>

<sup>1</sup>Department of Pathology, Oued Eddahab Military Hospital, Morocco

<sup>2</sup>Department of Pathology, Mohamed VI Oujda University Hospital Center, Morocco

<sup>3</sup>Department of Radiology, Oued Eddahab Military Hospital, Morocco

<sup>4</sup>Department of Urology, Oued Eddahab Military Hospital, Morocco

DOI: <https://doi.org/10.36347/sjmcr.2024.v12i12.031>

| Received: 08.11.2024 | Accepted: 15.12.2024 | Published: 18.12.2024

\*Corresponding author: M. Tbouda

Department of Pathology, Oued Eddahab Military Hospital, Morocco

### Abstract

### Case Report

Liposarcoma is an uncommon mesenchymal tumor. There are several histological variants. Dedifferentiated liposarcoma is often located retroperitoneally. Renal localization is exceptional. In this article, we report a case of primary renal dedifferentiated liposarcoma treated by radical total nephrectomy. Imaging assessment suspected a malignant tumor. It was the histological examination with an immunohistochemical complement that confirmed the diagnosis of dedifferentiated renal liposarcoma. The prognosis remains poor.

**Keywords:** Dedifferentiated liposarcoma, Renal localization, Sarcoma, Immunohistochemistry, Radical nephrectomy.

Copyright © 2024 The Author(s): This is an open-access article distributed under the terms of the Creative Commons Attribution 4.0 International License (CC BY-NC 4.0) which permits unrestricted use, distribution, and reproduction in any medium for non-commercial use provided the original author and source are credited.

## INTRODUCTION

Sarcomas are rare malignant tumors. They are located in soft tissues in more than 50% of cases [1]. Soft tissue sarcomas (STS) represent 1% of soft tissue tumors and less than 1% of all adult cancers. Renal sarcomas are extremely rare. Dedifferentiated liposarcomas often occur in the retroperitoneum [2].

The diagnosis is histological and requires a morphological study, often with recourse to immunohistochemical or molecular studies.

Treatment is based on wide surgical excision with healthy margins. The prognosis of these tumors remains unfavorable in relation to a high rate of locoregional recurrences, high comorbidity and mortality. In order to optimize the therapeutic results of these rare tumors, multidisciplinary management is mandatory.

In this article, we report the case of a dedifferentiated liposarcoma of renal localization in order to specify, through a review of the literature, the histological and immunophenotypic aspects of this type of tumor.

## OBSERVATION

This is a 65-year-old chronic smoker patient being treated for benign prostatic hypertrophy,

hypertensive on a calcium channel blocker who has had back pain for 2 months with a notion of pollakiuria without other associated urinary signs. On clinical examination: palpation reveals a large mass at the level of the renal lodge, mobile with bumpy contours, firm consistency and smooth surface. The rest of the somatic examination is without anomaly.

The abdominal scan objectifying a right lower polar renal solid mass with mixed tissue, fat and fluid components, lobulated, heterogeneously enhanced after injection with infiltration of homolateral perirenal fat (Figure 1).

A total nephrectomy was performed. The specimen was sent to the pathology laboratory.

### On Macroscopic Examination:

It is a poorly defined tumor lesion, yellowish-white in color with well-developed vascularization on the surface. On section, we noted the presence of an enormous yellowish-white tumor that pushes back and crushes the kidney on the periphery. It measures 22x8.5x6cm, with an adrenal reduced to a border of 2x2x0.3cm. The ureter identified measures 7cm long.

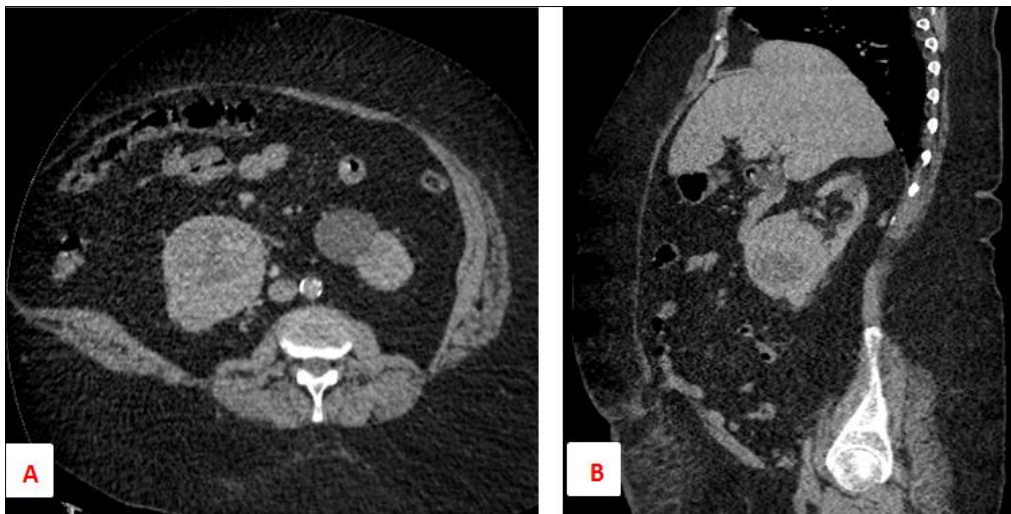
The morphological study of the different samples taken from the tumor shows a tumor proliferation of variable cell density. There are rich territories made of bundles of cells with elongated or

rounded nuclei with dense chromatin. The nuclei are hyperchromatic with moderate dyskaryosis. In places, we note monstrous cells with very irregular large nuclei, or multinucleated nuclei with granular chromatin with the presence of several micro-vacuoles notching the nucleus having strongly expressed the PS 100 antibody (figure 3). The process described above infiltrates the renal capsule and parenchyma. The excretory tract, the vessels and the adrenal gland are not invaded. The external capsule of the renal lodge is intact.

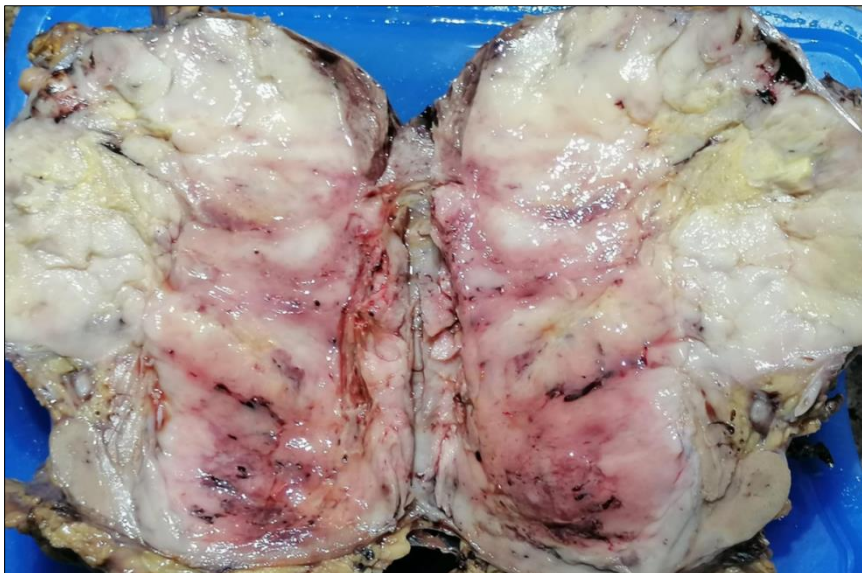- The tumor proliferation strongly expressed the MDM2 antibody.

- In conclusion, the morphological and immunohistochemical appearance of a dedifferentiated liposarcoma.
- The tumor excision is complete.
- No adjuvant therapy was deemed necessary.

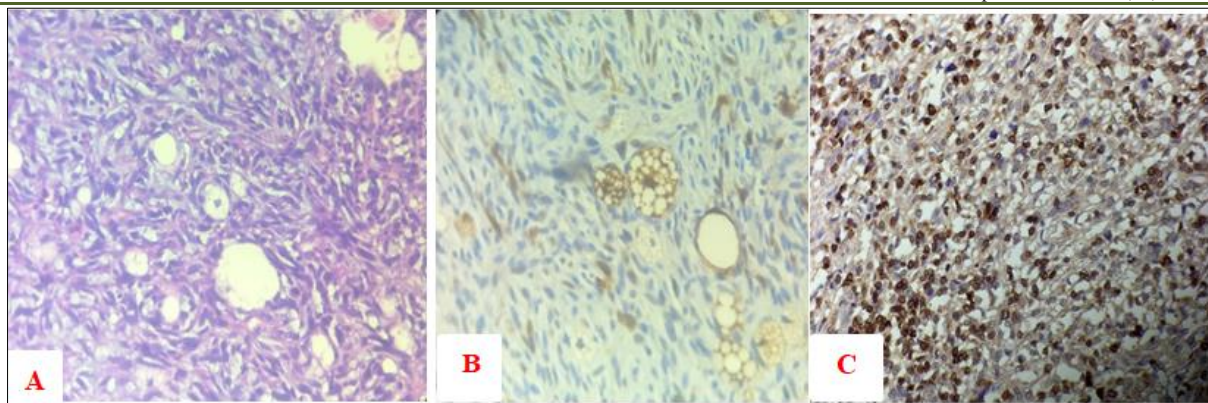
The patient is followed regularly according to a rhythm of a clinical examination every 4 months and an abdominopelvic CT scan every 6 months. The follow-up is 14 months without signs of detectable recurrence.



**Figure 1 : Axial (A) and sagittal (B) sections of an abdominal CT scan with iodinated contrast medium injection objectifying a right lower polar renal solid mass with mixed tissue, fat and fluid components.**



**Figure 2 : Gross specimen : poorly demarcated heterogeneous mass with a peripheral border of the renal parenchyma**



**Figure 3 : Mesenchymal tumor proliferation with the presence of some lipoblastic cells (A) expressing PS 100 (B). Overexpression of MDM2 by proliferation (C).**

## DISCUSSION

Renal liposarcomas are extremely rare neoplasms described in case reports. Literature reviews have reported 17 cases (14.3%) out of 119 reported cases of kidney sarcomas [3]. The risk factors of renal cancer include family history, hypertension, smoking or hereditary kidney disease [4]. Our patient has hypertension and smoking habit.

Most published cases of liposarcoma of the kidney had reported well differentiated tumours, with an average tumour size of 5 cm and the reported symptoms had included: pain, abdominal mass (most frequent), weight loss and haematuria (rare presentation) [5]. The most frequent haematogenous metastases have been reported in the lungs, lymph nodes and liver [6].

Imaging examinations allow a morphological assessment of the renal tumor. The reference examination is computed tomography which sometimes shows an associated fatty component.

The diagnosis of certainty is anatomopathological based on a histological study and a complementary immunohistochemical study. The use of molecular biology data is sometimes necessary.

Histologically, it is a sarcomatous tumor proliferation made of long and short bundles of large cells with very atypical nuclei with the presence of numerous mitotic figures.

On immunohistochemical study, the tumor proliferation expresses vimentin, PS 100. The CKAE1-AE3, CD 34, PAX 8 and STAT 6 antibodies are negative.

This type of tumor strongly expresses the MDM2 antibody which confirms the adipocyte nature of the tumor proliferation.

Molecularly, these tumors show an amplification of the MDM2 gene.

Our case shows strong expression of PS100 and MDM2 antibodies.

The differential diagnoses of primary liposarcoma of the kidney include: angiomyolipomas (their main one since both are large lesions with fat content), dedifferentiated pleomorphic sarcoma, pleomorphic liposarcoma and myxoid liposarcoma, all of which lack the differentiated liposarcoma component and do not express MDM2. Another one is well-differentiated liposarcoma, however mitotic activity in these tumors is usually low or absent and histologically smooth with conspicuous lipoblasts, and also do not express MDM2 [7].

The standard treatment is based on complete surgery with healthy surgical margins. Few cases have reported the use of adjuvant treatment (chemotherapy or radiotherapy) in the management of primary liposarcoma of the kidney with discordant results.

Chemotherapy is used in liposarcoma of kidney tumors that cannot be completely resected, in recurrent disease or in distant metastases.

However, its benefit is minimal and not many studies have been undertaken. Perez *et al.*, [8], reported that chemotherapy agents such as doxorubicin and ifosfamide demonstrated activity on both retroperitoneal and truncal liposarcoma but have not demonstrated differences in survival (69 months median survival for truncal versus 78 months for retroperitoneal liposarcomas,  $p = 0.668$ ).

The most important prognostic factors for survival are the histologic subtype or grade and completeness of resection. In the report by Wang *et al.*, [5], the overall 1-year, 3-year, and 5-year survival rates were 86%, 41%, and 15%, respectively. The median survival was 28 months. The median survival with metastases or after recurrence was 8–10 months. There was no local recurrence in our patient during the 14 month follow-up [9].

## CONCLUSION

Primary renal liposarcoma is extremely rare. It is a rapidly developing mesenchymal tumor. The diagnosis is essentially anatomopathological, based on a morphological study followed by an immunohistochemical study, sometimes requiring the use of molecular biology.

The standard treatment is surgery. A widened total nephrectomy with healthy margins is necessary, followed by regular monitoring.

The prognosis remains poor despite therapeutic progress.

**Conflicts of Interest:** None.

## REFERENCES

1. Tahri, R., Gamra, L., & El Otmany, A. (2018). Liposarcome de la loge rénale: à propos de deux cas avec revue de la littérature. *Pan African Medical Journal*, 29(1), 1-12.
2. Rioja, P., Valencia, G., Centurión-Rodríguez, C., Morante, Z., Bravo, M., Huanca, L., & Morante, C. (2021). Renal liposarcoma: case report and review of systemic treatment. *ecancermedicalscience*, 15.
3. Öztürk, H. (2015). Prognostic features of renal sarcomas. *Oncology Letters*, 9(3), 1034-1038.
4. Chiao-Ching, Li., Chiao-Zhu, Li., & Chin-Yu, L. (2018). Dedifferentiated liposarcoma of the left kidney: A rare case report. *Urology Case Reports*, 24–26
5. Bader, D. A., Peres, L. A., & Bader, S. L. (2004). Renal liposarcoma. *Int Braz J Urol*, 30(3), 214–215
6. Matsushita, M., Ito A., & Ishidoya, S. (2007). Intravenous extended liposarcoma arising from renal sinus. *Int J Urol*, 14(8) 769–770.
7. Wang, L. J., Wong, Y. C., & Chen, C. J. (2002). Computerized tomography characteristics that differentiate angiomyolipomas from liposarcomas in the perinephric space *J Urol*, 167(2), 490–493.
8. Perez, E. A., Gutierrez, J. C., Moffat, F. L., Franceschi, D., Livingstone, A. S., Spector, S. A., ... & Koniaris, L. G. (2007). Retroperitoneal and truncal sarcomas: prognosis depends upon type not location. *Annals of surgical oncology*, 14, 1114-1122.
9. Wang, X., Xu, R., Yan, L., Zhuang, J., Wei, B., Kang, D., ... & Lu, Y. (2011). Adult renal sarcoma: clinical features and survival in a series of patients treated at a high-volume institution. *Urology*, 77(4), 836-841.