

## Intramuscular *Diectophyme renale* Surgically Removed from Dog – Rare Case Report

Pâmela Caye<sup>1\*</sup>, Vanessa Milech<sup>2</sup>, Charles Silva de Lima<sup>3</sup>, Fabrício de Vargas Arigony Braga<sup>4</sup>, Marlete Brum Cleff<sup>4</sup>, Josaine Cristina da Silva Rappeti<sup>4</sup>, Guilherme Albuquerque de Oliveira Cavalcanti<sup>4</sup>

<sup>1</sup>Hospital of Veterinary Clinics at Federal University of Pelotas, Pelotas, RS, Brazil

<sup>2</sup>Federal University of Santa Maria, Santa Maria, RS, Brazil

<sup>3</sup>University of Franca, Franca, SP, Brazil

<sup>4</sup>Department of Veterinary Clinics at Federal University of Pelotas, Pelotas, RS, Brazil

### Case Report

#### \*Corresponding author

Pâmela Caye

#### Article History

Received: 11.04.2018

Accepted: 23.04.2018

Published: 30.05.2018

#### DOI:

10.36347/sjavs.2018.v05i05.001



**Abstract:** *Diectophyme renale* is a nematode that affects mainly the right kidney of carnivores, but can also be found ectopically. A five-year-old dog was admitted at the Hospital of Veterinary Clinics at Federal University of Pelotas, presenting a swelling at the base of the penis and testicles. By ultrasonographic evaluation, the dog was diagnosed with diectophymatosis at the lateral area of the penis in the abdominal cavity. This study was aimed to report a *Diectophyme renale* case that was solved with a surgical procedure, which resulted in the removal of a 50-centimeter-long parasite from the rectus abdominis muscle of the patient. Even though no case of *Diectophyme renale* on skeletal muscle of dogs has been reported before, it was concluded that the parasite can survive on muscular tissue of dogs.

**Keywords:** dog; kidney; muscle; diectophymatosis; surgery; nematode.

### INTRODUCTION

Diectophymatosis is a disease caused by the parasite *Diectophyme renale*, acknowledged like this since 1989 according to the International Commission on Zoological Nomenclature, according to Pedrassani and Nascimento in a literature review [1]. The helminth presents red-blood color, where the female may achieve 100 centimeters long and the male 45 centimetres long, which is also identified through bell-shaped muscular bag at the posterior end [1, 2]. The parasite mainly affects the right kidney of carnivores, feeding on renal parenchyma and blood, destroying the renal parenchyma, transforming the organ into a fibrous capsule [1-5].

Lipolytic and proteolytic enzymes of parasite esophageal origin cause coagulation necrosis in the parasitized sites [1]. The disease is classified as a zoonosis, and the contamination of animals and man occurs through the ingestion of larvae present in the intermediate host, the aquatic oligochaete annelid *Lumbriculus variegatus*, or by ingestion of raw or underdone meat from paratennial hosts infected with larvae, such as fish and frog [1-3, 5].

In the definitive host, after ingestion of the larval form of *Diectophyme renale*, there is a tendency of migration to the right kidney [1, 3, 6]. This migration has several theories, none of which is considered definitive, such as: migration by proximity of the duodenum to the right kidney [1, 2, 4, 6], the parasite's own tropism by the organ and also, the displacement of the larvae to the liver, hepatic circulation, followed by the right kidney due to the proximity of the two organs [3, 7]. However, there are several reports of ectopic parasitism by *Diectophyme renale* in dogs, which can

be found in several organs [3, 7-9] and free in the abdominal cavity [2].

In the majority of time the disease is asymptomatic, since affecting one of the kidneys, the contralateral kidney undergoes compensatory hypertrophy and the animal shows no signs of renal insufficiency [6, 10, 11]. In the presence of clinical signs, weight loss, apathy, dorsal arching and gait are observed [1, 6]. The diagnosis for parasitism by *Diectophyme renale* can be performed through examination of urinary sediment when there is renal involvement, and through the visualization of double, elliptical, brown and thick-bark eggs [6, 11, 12]. The identification of the parasite can also be performed by ultrasonography [1, 8], an efficient method that allows the visualization of tubular structures with hyperechogenic borders and a hypoechogenic center [1, 5]; besides surgeries, necropsy [1] and computed tomography [13]. The increase of acute phase proteins

in the evaluation of patients' biochemical profile also serves as an indication of parasitosis [14].

No chemical therapy is effective for the treatment of infection by *Diocotophyme renale*, since the surgical removal of the parasite is the only way to resolve the disease [2, 6, 10]. The present study is aimed to describe a case of diocotophymatosis in a dog's rectus abdominis muscle, diagnosed and surgically treated at Hospital of Veterinary Clinics at Federal University of Pelotas.

## CASE REPORT

A dog from a region of high social vulnerability in the city of Pelotas, Rio Grande do Sul, Brazil, was attended at the Veterinary Clinical Hospital of the Federal University of Pelotas (HCV- UFPel) showing increased volume in the testicles and at the base of the penis. It was found during anamnesis that the patient was a male, with no defined breed, with five years old and weighting 21 kilos, demonstrating palpation discomfort and local edema. The patient did not show any other clinically visible changes, having normal appetite and water intake, pink mucous

membranes and lymph nodes with a physiological pattern.

Blood and urine collection were performed. The blood count showed a mild anemia (hematocrit 35.2%, hemoglobin 10.1g/dl), leukopenia (total leukocytes 4800/ $\mu$ l) and lymphopenia (lymphocytes 480/ $\mu$ l), and serum biochemistry (ALT, creatinine, urea and albumin) showed no changes. Urinalysis indicated moderate bacteriuria, with presence of various cells, without presence of *Diocotophyme renale* eggs. It was instituted antibiotic therapy based on 150mg of enrofloxacin every 24 hours and lavage of the urinary vesicle with warm sterile physiological solution until resolution of bacteriuria. To reduce discomfort, 500mg of dipyrone was prescribed every 8 hours. The patient was submitted to an ultrasound examination, where tubular structures with thin hyperechogenic walls compatible with the presence of *Diocotophyme renale*, located laterally to the penis, were found in the abdominal wall, close to the inguinal region. Surgical treatment was determined for parasite removal. The patient was hospitalized and monitored until they were sent to the operating room.

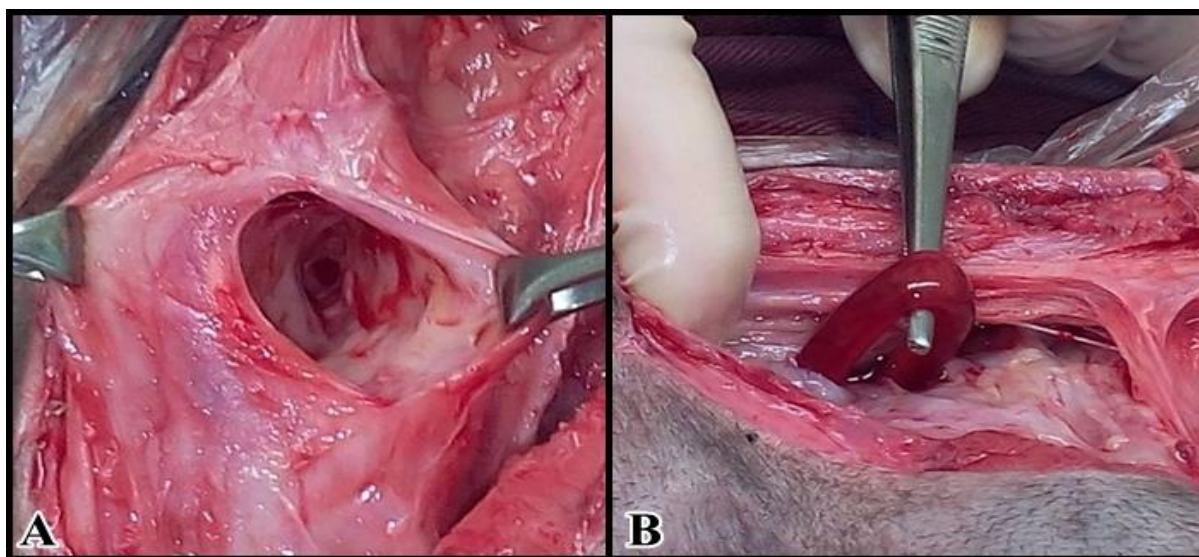


Fig-1: Transoperative of a dog presenting muscular diocotophymatosis. A) Gallery formed by migration of *Diocotophyme renale* in the rectus abdominis muscle of a dog. B) Removal of *Diocotophyme renale* from the rectus abdominis muscle.

Six days after the first hematological examination, the evaluation was repeated. The second analysis revealed a fall in hematocrit to 33.1% and hemoglobin remained stable. Leukopenia was reversed (total leukocytes 10.100/ $\mu$ l) and lymphocytes represented 1.313/ $\mu$ l. After preoperative preparation and routine anesthetic procedures, the surgical procedure was started in search of the parasite, which was not located in the region indicated by the ultrasound examination. With the perception of an increase in the volume of the rectus abdominis muscle, the site was researched, since nothing was found, also, in the exploratory laparotomy. Muscle dissection was

performed, and galleries were visualized, which allowed the localization and subsequent removal of the parasite (Figure-1).

The procedure resulted in the removal of one specimen of *Diocotophyme renale* measuring 50 centimetres. After exploring all the organs and confirming that there were no more copies of the parasite, the muscle was debrided and the abdominal wall sutured as usual. Immediately after the surgical procedure, the patient received 4mg/kg of tramadol hydrochloride and 0.2mg/kg of meloxicam, both for pain and inflammation management, as well as

30mg/kg of cefalotin as antibiotic therapy. On the seventh day after the surgical procedure, the stitches were removed, and the patient was fine.

## DISCUSSION AND CONCLUSION

The patient was taken to a veterinarian's appointment because of an increase in volume in the penile region and palpation discomfort, causing a suspicion of local tumor mass. Ultrasonographic, hematological, and urinary exams were performed to determine the diagnosis. Ultrasonography showed compatible structures as reported by the literature for the diagnosis of dirotyphmatosis [1, 5, 8]. Although computed tomography is as effective as ultrasonography in the diagnosis of dirotyphmatosis [13], it is a hardly accessible and onerous examination, therefore, it was not performed.

Anemia is a frequent finding in these patients, since a single parasite is capable of causing complete Destruction of the kidney, leading to blood loss and decreased production of erythropoietin [1]. The reported dog did not receive a balanced diet, which, in association with the blood spoliation performed by the parasite, possibly led to the development of anemia. Since there are no reported cases of muscular dirotyphmatosis, it is not possible to determine the main cause of anemia in the present patient. There is no evidence that dirotyphmatosis is related to the development of leukopenia and lymphopenia, which may have secondary causes in the patient, as a response to glucocorticoids, acute systemic infection and the occurrence of lymphomas [15]. Investigation of acute phase proteins was not performed, which is indicative of parasitosis [14].

Bacteriuria diagnosed by urinalysis is also not related to the case of muscular dirotyphmatosis, since the parasite did not affect the kidneys nor the urinary vesicle. Examination of urinary sediment of affected patients usually counts on the presence of parasite's eggs, however, this fact only occurs when there are females parasitizing one kidney, or both [1, 12]. In the case of urinalysis of the treated patient, there were no eggs of *Dirotyphma renale*, since the parasitosis was caused by a specimen that was not located in the kidneys, nor in the urinary tract.

The increase in volume in the inguinal region lateral to the penis was perceptible and palpable hours before the patient entered the surgical block, but during the surgery the volume increase was not observed. The parasite was not located in the subcutaneous tissue nor in the scrotum, since the patient also underwent an orchiectomy, at the tutor's request. Thus, it was verified that *Dirotyphma renale* was not parasitizing the subcutaneous tissue nor had it migrated to the scrotum, justifying an exploratory laparotomy. This technique allowed the removal of a nematode of the genus *Dirotyphma renale* found inside galleries, formed by

its migration through the musculature. The penetration power in the tissues is due to the capacity of the esophageal glands of the nematode to produce proteolytic and lipolytic enzymes that, in contact with tissues, cause coagulation necrosis [1, 16]. It is the migration capacity that justifies the finding of the nematode in a different location than indicated during the ultrasound and explains the need to change the surgical approach.

Although dirotyphmatosis is frequently associated with the right kidney, there are several reports of ectopic locations of *Dirotyphma renale*, such as in a gestational sac in the right uterine horn [3], in the inguinal region, in a breast tumor [7], in the mesenteric lymph node, lobes of the liver, in the left kidney [8], between the intestinal [9] and free loops in the abdominal cavity [2]. However, to date, no reports of *Dirotyphma renale* in the muscle tissue of dogs have been found in the literature.

The prognosis becomes relative to the affected site, the parasite load and the time of infection. Considering that there are no other reports of dirotyphmatosis in dog muscle, it is not possible to draw a comparative profile of the evolution of the disease. Thus, it is only possible to analyze this isolated case, with rapid resolution, where *Dirotyphma renale* migrated from the lateral tissue to the penis to the rectus abdominal muscle. Hence, it can be concluded that *Dirotyphma renale* has the capacity to parasite the skeletal muscle of dogs, and this may be the first report of dirotyphmatosis in registered muscle tissue.

## REFERENCES

1. Pedrassani D, Nascimento AA. Verme gigante renal. Revista Portuguesa de Ciências Veterinárias. 2015;110(593594):30-7.
2. Amaral LCD, Polizer KA, Sant'ana TM, Neves MF. *Dirotyphma renale*. Revista Científica Eletrônica de Medicina Veterinária. 2008;10.
3. Veiga CCP, Oliveira PC, Ferreira AMR, Azevedo FD, Vieiras SL. Dirotyfomose em útero gravídico em cão – relato de caso. Revista Brasileira de Medicina Veterinária. 2012; 34(3):188-191.
4. Zardo KM, dos Santos DR, Babicsak VR, Belotta AF, de Oliveira HS, Estanislau CA, Mamprim MJ, Brandão CV. Aspecto ultrassonográfico da dirotyfomose renal canina. Veterinária e Zootecnia. 2012 Jan 1;19(1):57-60.
5. Cottar BH, Dittrich G, Ferreira AA, Carvalho ACP, Albernaz VG, da Luz MT, Tasqueti UI. Achados ultrassonográficos de cães parasitados por *Dirotyphma renale*-estudo retrospectivo. Veterinária e Zootecnia. 2012 Jan 1;19(1):8-11.
6. Alvez GC, Silva DT, Neves MF. *Dirotyphma renale*: O parasita gigante do rim. Revista Científica Eletrônica de Medicina Veterinária. 2007; 4(8).

7. Sousa AAR, Sousa AAS, Coelho MCOC, Quessada AM, Freitas MVM, Moraes RFN. Dioctofimose em cães. *Acta Scientiae Veterinariae*. 2011;39(3).
8. Leite LC, Círio SM, Diniz JM, Luz E, Navarro-Silva MA, Silva AW, Leite SC, Zadorosnei AC, Musiat KC, Veronesi EM, Pereira CC. Lesões anatomopatológicas presentes na infecção por *dioctophyma renale* (goetze, 1782) em cães domésticos (*canis familiaris*,) linnaeus, 1758. *Archives of Veterinary Science*. 2005 Jun 30;10(1).
9. Lemos LS, dos Santos ASO, Rodrigues ABF, Goulart MLVS, Almeida LG, Silveira LS. Extra-renal lesion caused by *Dioctophyma renale* eggs in an erratic cycle in a dog. *Int. J. Morphol*. 2010;28(4):1031-4.
10. Brun MV, de Castro Beck CA, Mariano MB, Antunes R. Nefrectomia laparoscópica em cão parasitado por *Dioctophyma renale*—relato de caso. *Arquivos de Ciências Veterinárias e Zoologia da UNIPAR*. 2002;5(1):145-52.
11. Ferreira VL, Medeiros FP, July JR, Raso TF. *Dioctophyma renale* in a dog: Clinical diagnosis and surgical treatment. *Veterinary Parasitology*. 2010; 168:151-155.
12. Silveira CS, Diefenbach A, Mistieri ML, Machado IRL, Anjos BL. *Dioctophyma renale* em 28 cães: aspectos clinicopatológicos e ultrassonográficos. *Pesquisa Veterinária Brasileira*. 2015; 35:899-905.
13. Rahal SC, Mamprim MJ, Oliveira HS, Mesquita LR, Faria LG, Takahira RK, Matsubara LM, Agostinho FS. Ultrasonographic, computed tomographic, and operative findings in dogs infested with giant kidney worms (*Dioctophyme renale*). *Journal of the American Veterinary Medical Association*. 2014; 244:555-558.
14. Schmidt EMS, Kjelgaard-Hansen M, Thomas F, Tvarijonavičiute A, Cerón JJ, Eckersall D. Acute phase proteins in dogs naturally infected with the giant kidney worm (*Dioctophyme renale*). *Veterinary Clinical Pathology*. 2016; 45:1-8.
15. Biondo AW. Interpretação do leucograma. In: *Anais do II Simpósio de Patologia Clínica Veterinária da Região Sul do Brasil; 2005, Porto Alegre. Porto Alegre: Universidade Federal do Rio Grande do Sul; 2005. p.29-35.*
16. Pedrassani D, Pilati C, Wendt SBT, Machado RZ, Nascimento AA. Diagnóstico ultrassonográfico de infecção intensa por *Dioctophyma renale* em rim esquerdo de cão – relato de caso. *Clínica Veterinária*. 2010; 85:74-80.