

## Predictive Factors of the No Reflow Phenomenon during ST-Elevation Myocardial Infarction: Case Reports and Literature Review

Hicham Faliouni<sup>1\*</sup>, Achraf Zaimi<sup>2</sup>, Malki Mohammed<sup>2</sup>, Driss Britel<sup>1</sup>, Zouhai Lakhel<sup>1</sup>, Aatif Benyass<sup>2</sup>

<sup>1</sup>Intensive Care Unit Department, Cardiology Center, Military Hospital of Rabat, Morocco

<sup>2</sup>Clinical Cardiology Department, Cardiology Center, Military Hospital of Rabat, Morocco

DOI: <https://doi.org/10.36347/sjmcr.2024.v12i12.035>

| Received: 14.11.2024 | Accepted: 21.12.2024 | Published: 24.12.2024

\*Corresponding author: Hicham Faliouni

Intensive Care Unit Department, Cardiology Center, Military Hospital of Rabat, Morocco

### Abstract

### Case Report

The no-reflow phenomenon, defined as inadequate myocardial perfusion despite successful coronary recanalization, remains a significant complication following primary angioplasty for STEMI. This retrospective study analyzes 10 clinical cases, highlighting predictive factors such as high thrombotic burden (70% of cases), significant comorbidities (diabetes 50%, hypertension 40%, smoking 60%), persistent left ventricular dysfunction (average LVEF 40%), and prolonged revascularization delays (>6 hours in 50% of cases). The observations emphasize the central role of microvascular dysfunction and the complexity of no-reflow pathophysiology. Compared to the existing literature, our findings underscore the importance of targeted preventive strategies and innovative therapeutic approaches to improve clinical outcomes. Prospective validation in larger cohorts is needed to confirm these results.

**Keywords:** No Reflow, ST Elevation Myocardial Infarction, Percutaneous Coronary Intervention.

**Copyright © 2024 The Author(s):** This is an open-access article distributed under the terms of the Creative Commons Attribution 4.0 International License (CC BY-NC 4.0) which permits unrestricted use, distribution, and reproduction in any medium for non-commercial use provided the original author and source are credited.

## INTRODUCTION

Despite significant advances in primary percutaneous coronary interventions, the phenomenon of no-reflow continues to challenge clinicians.

No-reflow is defined as a lack of adequate restoration of myocardial perfusion, despite successful mechanical recanalization of the guilty coronary artery. This complex phenomenon is attributable to multiple mechanisms, including distal embolism, microvascular obstruction, and ischemia-reperfusion injury. Risk factors include patient characteristics (diabetes, smoking, left ventricular dysfunction), coronary anatomy (high thrombotic load, low TIMI flow), and revascularization delays.

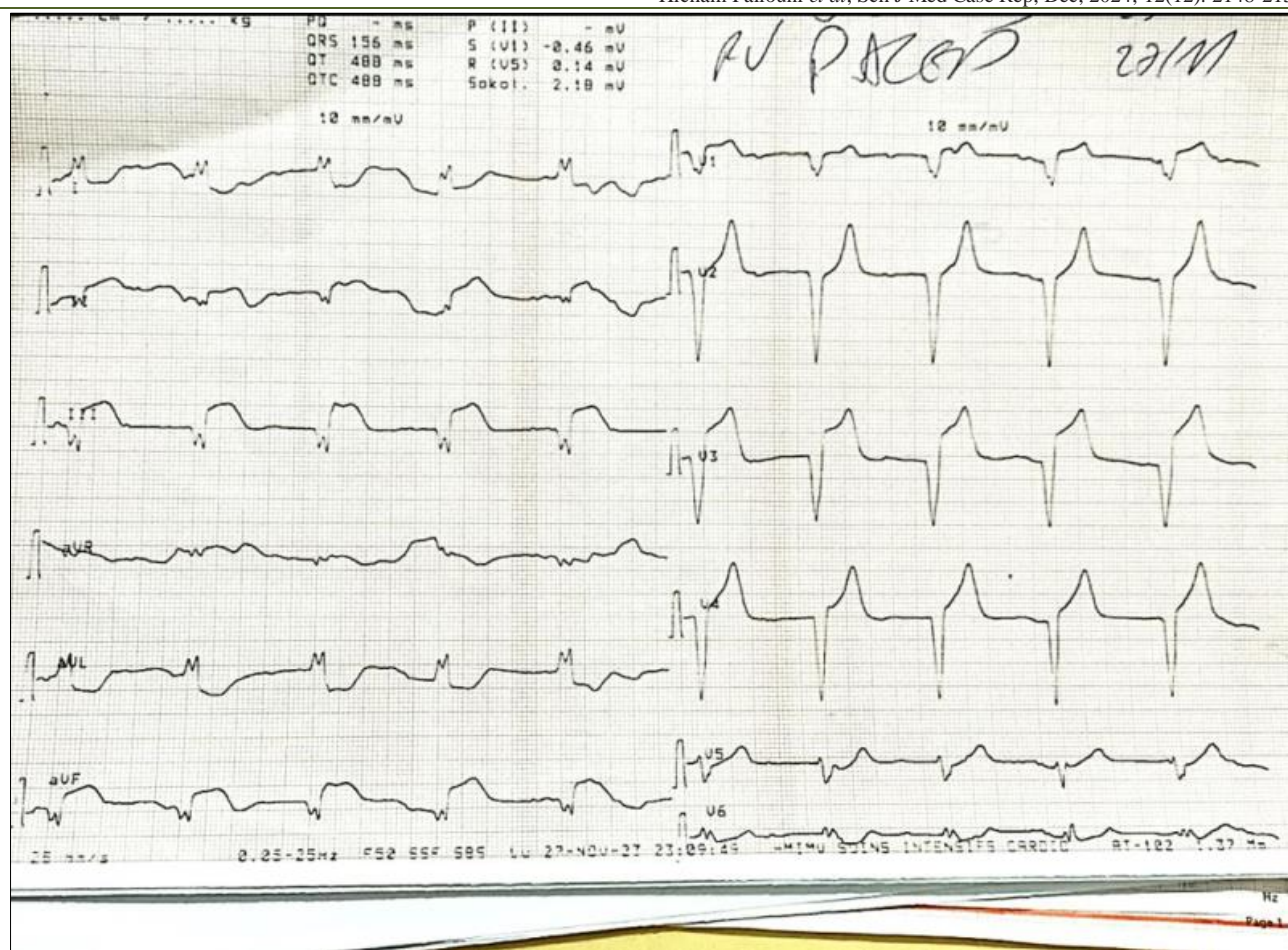
This article aims to analyze the predictors of no-reflow from ten selected clinical cases. Based on these

observations, we explore the underlying mechanisms and put our findings into perspective against existing data in the literature. These elements contribute to a better understanding of this phenomenon and open up prospects for its detection and management.

## CASE PRESENTATION

### 1. CASE 1

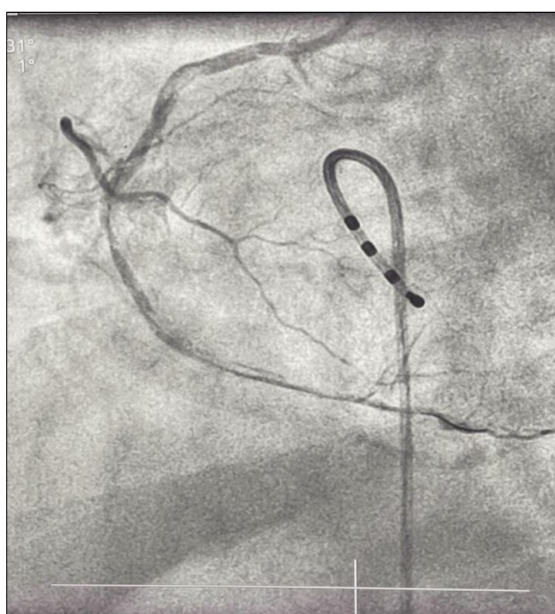
A 70-year-old patient presented with uncontrolled hypertension for 4 years, chronic smoking history of 30 pack-years, and poorly managed type 2 diabetes, which had resulted in the amputation of the right lower limb. The patient reported acute chest pain that had started 6 hours before admission. An electrocardiogram (ECG) revealed ST-segment elevation in the inferior leads and a first-degree atrioventricular block (Figure 1).



**Figure 1: Q wave and ST segment elevation in inferior leads**

Coronary angiography showed an occlusion of the middle right coronary artery with a TIMI flow grade of 1.

The procedure involved balloon dilation, which resulted in an improvement of flow to TIMI grade 2. However, distal embolization persisted, accompanied by a significant thrombotic burden (Figure 2).



**Figure 2: Restoration of TIMI 2 flow in the right coronary artery after balloon angioplasty**

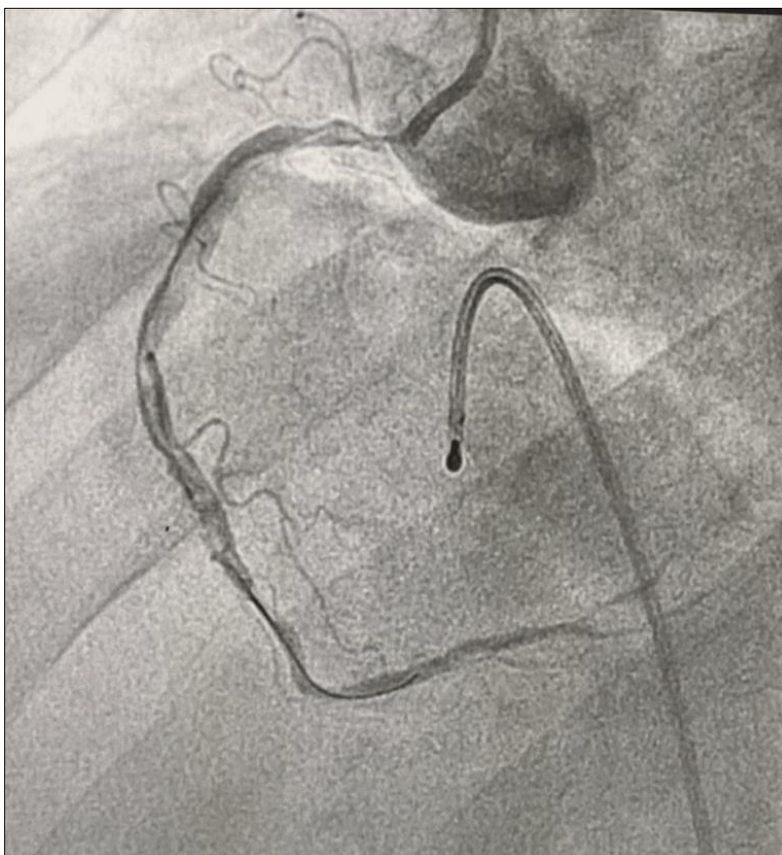
Post-procedure, the left ventricular ejection fraction (LVEF) was reduced to 35%. Despite the intervention, ST-segment elevation persisted, and there was no functional improvement in left ventricular performance. The patient received intensive treatment, including tirofiban, unfractionated heparin (UFH), clopidogrel, aspirin, and atorvastatin. Despite these measures, the no-reflow phenomenon persisted, indicating a poor response to both mechanical and pharmacological interventions.

## 2. CASE2

An 84-year-old patient with a history of type 2 diabetes mellitus managed with oral antidiabetic drugs

and a history of smoking cessation presented with acute chest pain that began 5 hours prior to admission. An electrocardiogram (ECG) revealed inferior ST-segment elevation and a complete atrioventricular block.

Coronary angiography showed an acute thrombotic occlusion of the proximal right coronary artery, with a TIMI flow grade of 0. The procedure involved thrombo-aspiration and balloon dilation; however, despite these interventions, the TIMI flow only improved to grade 1, and a significant thrombotic burden persisted (Figure 3).



**Figure 3: Restoration of TIMI 2 flow in the right coronary artery after balloon angioplasty of the ostium and thromboaspiration**

The clinical course was marked by hemodynamic instability, and the patient unfortunately died within 48 hours. Intensive treatment was administered, including tirofiban, unfractionated heparin (UFH), and dual antiplatelet therapy. Despite these efforts, the patient succumbed to complications, highlighting the critical impact of the significant thrombotic load and the challenges of managing no-reflow in such cases.

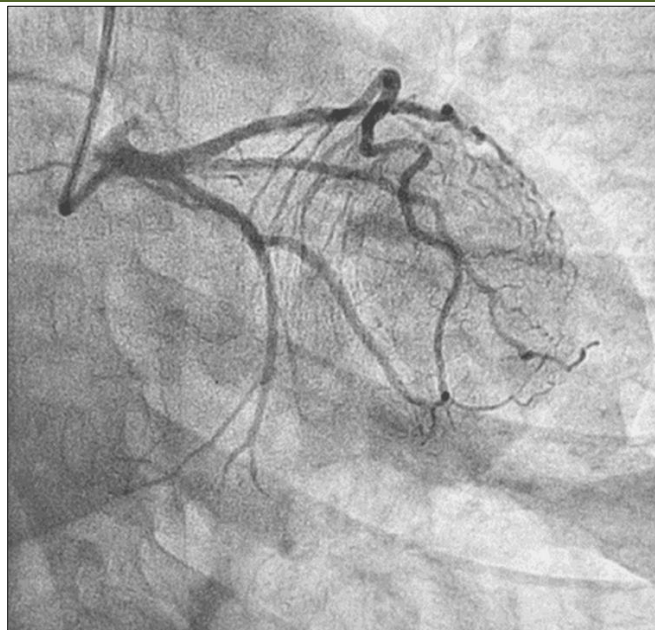
## 3. Case 3

A 57-year-old patient with a history of untreated hypertension and a chronic smoking habit of

10 pack-years, which had ceased 15 years prior, presented with acute chest pain that began 3 hours before admission. An electrocardiogram (EKG) revealed ST-segment elevation in the inferior leads.

Coronary angiography demonstrated an acute occlusion of the proximal circumflex artery with a TIMI flow grade of 0.

The intervention involved angioplasty with the placement of an active stent; however, despite the procedure, the TIMI flow only improved to grade 1, indicating persistent no-reflow (Figure 4).



**Figure 4: Restoration of TIMI 1 flow after angioplasty of the proximal circumflex artery with implantation of a RESOLUTE ONXY active stent 2.5 × 15 mm**

The clinical course was characterized by the absence of ischemic recurrence, but the no-reflow phenomenon persisted at a TIMI flow grade of 1. The patient was treated with tirofiban, clopidogrel, aspirin, statins, and ACE inhibitors. Despite these therapeutic efforts, suboptimal myocardial perfusion remained a significant challenge, underscoring the persistence of no-reflow.

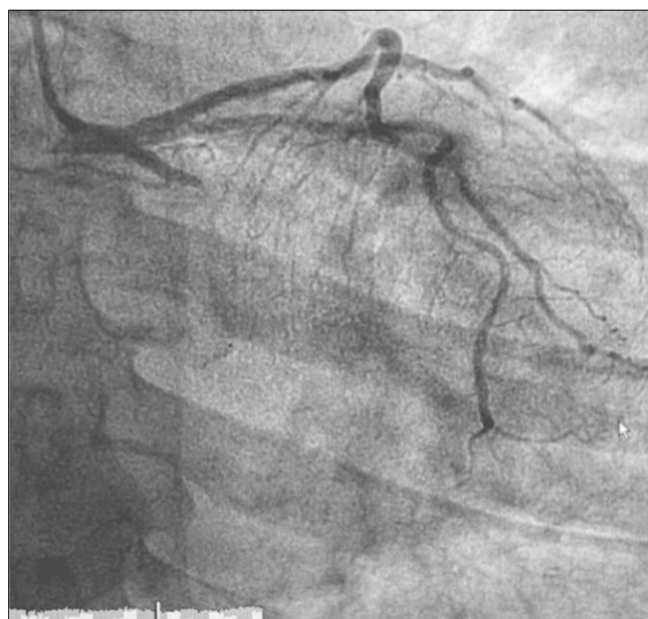
#### 4. Case 4

A 69-year-old patient presented with a history of hypertension, type 2 diabetes, and obesity. The patient

reported prolonged acute chest pain and was admitted 7 hours after symptom onset. An electrocardiogram (ECG) showed anterior ST-segment elevation.

Coronary angiography revealed an occlusion of the middle interventricular artery with a TIMI flow grade of 0.

The procedure involved balloon dilation, achieving a TIMI flow grade of 2, but a thrombus persisted (Figure 5).



**Figure 5: Restoration of TIMI 2 flow after angioplasty using BALLOON alone (SOLARICE 2.5 × 12 mm) at the level of the occlusion of the artery**

Post-procedure, the patient had moderate left ventricular dysfunction with an ejection fraction (LVEF) of 40% and persistent ST-segment elevation. The treatment included tirofiban, clopidogrel, aspirin, and statins. Despite these interventions, the no-reflow phenomenon persisted.

#### 5. Case 5

A 37-year-old patient with a history of active smoking presented with acute chest pain that began 3 hours before admission. An ECG revealed anterior ST-segment elevation.

Coronary angiography showed occlusion of the proximal interventricular artery with TIMI flow grade 0. The procedure involved the placement of an active stent, achieving a TIMI flow grade of 2.

The clinical course was marked by mild ventricular dysfunction and persistent ST-segment elevation. The patient received treatment with ticagrelor, unfractionated heparin (UFH), aspirin, and statins. Despite achieving TIMI 2 flow, no-reflow persisted.

#### 6. Case 6

A 68-year-old patient with hypertension, poorly controlled diabetes, and dyslipidemia presented with prolonged retrosternal chest pain that began 4 hours before admission. The ECG showed extensive ST-segment elevation.

Coronary angiography identified an occlusion of the middle interventricular artery with a TIMI flow grade of 0. The procedure involved balloon dilation, resulting in a TIMI flow grade of 1.

The patient experienced hemodynamic complications but stabilized after 48 hours. Treatment included tirofiban, heparin (UFH), clopidogrel, and ACE inhibitors. Despite these measures, the TIMI flow grade of 1 persisted, indicating continued no-reflow.

#### 7. Case 7

A 63-year-old patient with a history of dyslipidemia presented with acute retrosternal chest pain that began 2 hours before admission. An ECG showed inferior ST-segment elevation.

Coronary angiography revealed thrombotic occlusion of the middle right coronary artery with TIMI flow grade 0. The procedure included balloon dilation, resulting in a TIMI flow grade of 2.

The patient experienced partial symptom regression but continued to exhibit no-reflow. Treatment included tirofiban, UFH, ticagrelor, and statins. Despite clinical improvement, no-reflow persisted.

#### 8. Case 8

A 40-year-old patient with a history of active smoking (10 pack-years) presented with intense chest pain beginning 3 hours before admission. An ECG showed anterior ST-segment elevation.

Coronary angiography demonstrated proximal stenosis of the anterior interventricular artery with a TIMI flow grade of 1.

The procedure involved the placement of an active stent, improving TIMI flow to grade 2.

The clinical course included partial symptom regression and minor ventricular dysfunction. Treatment involved ticagrelor, UFH, and statins. Despite the TIMI 2 flow, moderate no-reflow persisted.

#### 9. Case 9

A 75-year-old patient with insulin-dependent type 2 diabetes, dyslipidemia, and a history of hypertension presented with prolonged chest pain starting 8 hours before admission. The ECG revealed anterior ST-segment elevation with sinus bradycardia.

Coronary angiography showed proximal occlusion of the anterior interventricular artery with TIMI flow grade 0. The procedure involved thrombo-aspiration and stent placement, achieving a TIMI flow grade of 1.

The patient experienced hemodynamic instability, requiring an intra-aortic counterpulsation balloon. The LVEF was reduced to 30%, and the ST-segment elevation persisted. Treatment included tirofiban, UFH, dual antiplatelet therapy, and statins. Despite intensive management, severe no-reflow persisted.

#### 10. Case 10

A 62-year-old patient with active smoking history (40 pack-years), obesity, and metabolic syndrome presented with acute chest pain that began 3 hours prior to admission. The ECG showed inferior ST-segment depression with Q waves.

Coronary angiography revealed subocclusive stenosis of the middle right coronary artery with TIMI flow grade 1. The procedure involved balloon dilation followed by active stent placement, achieving a TIMI flow grade of 2.

The clinical course included an LVEF of 45% post-intervention, persistent ST-segment elevation, and anginal recurrence within 24 hours. Treatment involved ticagrelor, UFH, statins, and ACE inhibitors. Moderate no-reflow was observed alongside early anginal recurrence.

## DISCUSSION

Our study identified several major predictors of the no-reflow phenomenon following primary angioplasty in STEMI patients. Key factors included a significant thrombotic load present in 70% of cases, persistent microvascular impairment with TIMI flow  $\leq 2$  in 80% of cases despite optimal revascularization, significant comorbidities such as diabetes (50%), hypertension (40%), and active or past smoking (60%), as well as persistent left ventricular dysfunction with an average ejection fraction (LVEF) of 40%. These findings reinforce the concept that no-reflow is a multifactorial complication influenced by clinical, angiographic, and microvascular parameters.

### Comparison with Literature

#### ➤ Persistent Thrombotic Load

In our cohort, 70% of patients exhibited a significant thrombotic load, confirming its role as a major predictor of no-reflow. This finding is consistent with Ndrepepa *et al.*, [1], who demonstrated that thrombotic load independently predicts no-reflow due to distal embolization and microvascular occlusion. Similarly, Gibson *et al.*, [2], highlighted the strong correlation between TIMI thrombotic grade and no-reflow risk, emphasizing the importance of thrombus reduction strategies, such as thromboaspiration or intracoronary fibrinolytic agents.

However, the universal effectiveness of thromboaspiration remains debated. Burzotta *et al.*, [3], suggested its selective use in cases of significant thrombotic load, a perspective partially supported by our findings. While thromboaspiration was applied in our cohort, the outcomes varied, underlining the complexity of achieving consistent improvements.

#### ➤ Cardiovascular Comorbidities

Comorbidities, including diabetes (50%) and hypertension (40%), were strongly associated with no-reflow in our study. Niccoli *et al.*, [4], linked diabetes to exacerbated ischemia-reperfusion injury via endothelial dysfunction and chronic inflammation, while hypertension increases microvascular rigidity, worsening microvascular obstruction.

Interestingly, 60% of our patients had a history of smoking, a factor that correlated with no-reflow. However, studies such as Halkin *et al.*, [5], propose a “tobacco paradox,” suggesting that smokers may experience fewer complications post-angioplasty. This discrepancy could result from variations in biological interactions, such as the pro-thrombotic state observed in smokers.

#### ➤ Microvascular and Ventricular Dysfunction

In 80% of our cases, LVEF was  $<40\%$ , highlighting significant myocardial involvement. Kloner *et al.*, [6], described microvascular dysfunction as central to the no-reflow phenomenon, driven by

ischemia-reperfusion injury, endothelial edema, and cell necrosis. Despite optimal interventions, recovery to TIMI grade 3 flow remained elusive, underscoring the critical role of microcirculation.

Our findings align with Reffelmann *et al.*, [7], who emphasized that microvascular perfusion abnormalities persist even after successful angioplasty. This underscores the need for therapeutic approaches specifically targeting microvascular dysfunction.

#### ➤ Delay in Revascularization

In our cohort, 50% of patients experienced a symptom-to-revascularization time exceeding 6 hours, a factor significantly associated with no-reflow. Stone *et al.*, [8], highlighted that prolonged delays lead to irreversible myocardial damage, increasing no-reflow risk. However, De Luca *et al.*, [9], pointed out that even timely interventions cannot fully prevent no-reflow in patients with pre-existing microvascular disease. Our results emphasize the importance of optimizing coronary flow regardless of revascularization delays.

### Summary of Convergences and Divergences

Our observations align with existing literature, confirming thrombotic load, comorbidities, and microvascular dysfunction as key determinants of no-reflow. However, divergences exist regarding the paradoxical role of smoking and the optimal management of thrombus. These differences reflect the complexity of this phenomenon and highlight the necessity for further research to clarify the interactions between contributing factors.

Our results highlight several practical implications:

#### 1. Preventive Strategies:

Identification of patients with significant thrombotic load and major comorbidities.

Use of preventive strategies such as systematic thrombo-aspiration and intracoronary injection of vasodilating agents (e.g., adenosine, nitroprusside).

#### 2. Optimization of Care:

Reduced time from symptom onset to revascularization. Aggressive management of cardiovascular risk factors (glycemic control, hypertension).

#### 3. Innovative Therapeutic Approaches:

Exploring treatments targeting microvascular obstruction, such as complement inhibitors or anti-inflammatory agents.

### Limitations of the Study

**Sample Size:** The small number of patients limits the statistical scope of the findings.

**Retrospective Design:** Some data may be biased or incomplete.

**Absence of a Control Group:** Comparing patients with TIMI 3 flow would have made it possible to better characterize the differences related to no-reflow.

## CONCLUSIONS

The no-reflow phenomenon is closely related to several predictive factors, including high thrombotic load, cardiovascular comorbidities, left ventricular dysfunction, and prolonged time to revascularization. Early identification and management of high-risk patients is essential to improve clinical outcomes. Larger prospective studies are needed to confirm these observations and develop new therapeutic strategies

## REFERENCES

1. Ndrepepa, G., Kastrati, A., & Mehilli, J. (2008). Thrombus burden and no-reflow in patients with acute myocardial infarction. *Am Coll Cardiol*, *51*, 1234-1240. 10.1016/j.jacc.2007.10.056.
2. Ndrepepa, G., Kastrati, A., & Mehilli, J. (2004). *TIMI thrombus grade and its association with outcomes*. *Am J Cardiol*, *93*, 47-52. 10.1016/j.amjcard.2003.09.032
3. Burzotta, F., Trani, C., & Mazzari, M. A. (2008). Manual thrombus-aspiration in primary percutaneous coronary intervention: impact on myocardial reperfusion, infarct size, and clinical outcome. *European Heart Journal*, 2902-2910. 10.1093/eurheartj/ehn478
4. Niccoli, G., Scalone, F., & Crea, F. (2016). The no-reflow phenomenon in acute myocardial infarction: Mechanisms and treatment. *Int. J Cardiol*, *213*, 8-15. 10.1016/j.ijcard.2015.08.061
5. Halkin, A., Singh, M., & Nikolsky, E. (2005). Prediction of Mortality After Primary Percutaneous Coronary Intervention for Acute Myocardial Infarction: The CADILLAC Risk Score. *Journal of the American College of Cardiology*, *45*, 1397-1405. 10.1016/j.jacc.2005.01.041
6. Kloner, R. A., King, K. S., & Harrington, M. G. (2001). No-reflow phenomenon in the heart. *Circulation*, *104*, 123-128. 104:123-128. 10.1161/01.CIR.104.20.2434
7. Reffelmann, T., Kloner, R. A., & Hale, S. L. (2002). The no-reflow phenomenon: Basic science and clinical correlates. *Heart*, *87*, 162-168. 10.1136/heart.87.2.162
8. Stone, G. W., Colombo, A., & Gersh, B. (2005). Influence of time-to-treatment on myocardial, 1233-1239. 10.1161/01.CIR.0000131947.36587.20
9. De Luca, G., Suryapranata, H., van't Hof, A. W., de Boer, M. J., Hoorntje, J. C., Dambrink, J. H. E., ... & Zijlstra, F. (2004). Prognostic assessment of patients with acute myocardial infarction treated with primary angioplasty: implications for early discharge. *Circulation*, *109*(22), 2737-2743.