

## Trichofolliculoma of the Chin Region: Case Report and Literature Review

Sarra Benwadih<sup>1\*</sup>, Anas Azgaoui<sup>1</sup>, Bouchra Dani<sup>1</sup>, Nadia Cherradi<sup>2</sup>, Hafsa El Ouazzani<sup>2</sup>, Malik Boulaadas<sup>1</sup>

<sup>1</sup>Department of Maxillofacial Surgery - Ibn Sina Hospital, Rabat, Morocco

<sup>2</sup>Department of Pathology – HSR, Rabat, Morocco

DOI: <https://doi.org/10.36347/sjmcr.2025.v13i01.036>

| Received: 11.12.2024 | Accepted: 16.01.2025 | Published: 20.01.2025

\*Corresponding author: Sarra Benwadih

Department of Maxillofacial Surgery - Ibn Sina Hospital, Rabat, Morocco

### Abstract

### Case Report

Trichofolliculoma is a rare and benign adnexal tumour. It often affects the cephalic extremity. The diagnosis is confirmed by anatomopathological examination of the lesion. Treatment is surgical. We present a case of a 74-year-old male patient without any previous history. A biopsy was performed and an anatomopathological study was carried out, which revealed a trichofolliculoma. The patient underwent surgical reduction of the tumour.

**Keywords:** Trichofolliculoma, Benign Tumor, Scalp Tumor, Surgical Excision, Histopathology.

Copyright © 2025 The Author(s): This is an open-access article distributed under the terms of the Creative Commons Attribution 4.0 International License (CC BY-NC 4.0) which permits unrestricted use, distribution, and reproduction in any medium for non-commercial use provided the original author and source are credited.

## INTRODUCTION

Trichofolliculoma is an adnexal tumor of follicular origin, which includes basaloid follicular hamartoma, trichoblastoma, pilomatricoma, and other less common benign tumors, and is a follicular malformation [1].

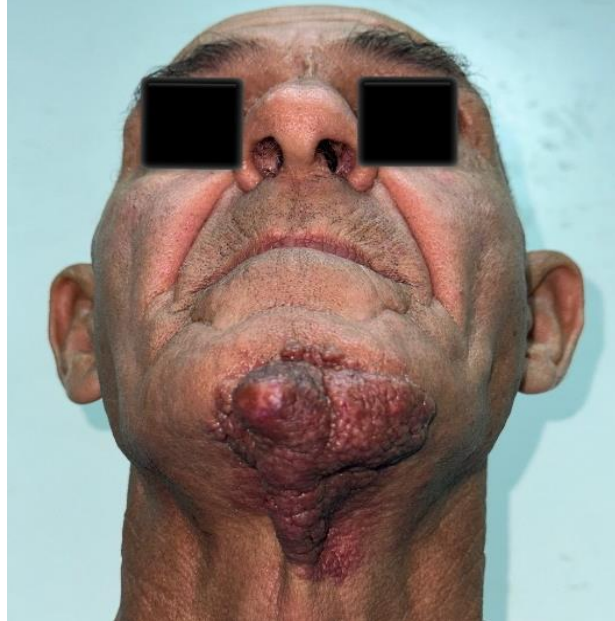The head is the most common site, with rare involvement of the labial, intranasal, and external ear canals. The tumor often presents as an isolated flesh-colored nodule, and histology characteristically shows a central dilated follicle (primary follicle) with a thick wall into which secondary follicles open [2, 3].

Anatomical-pathological examination and comparative anatomical-clinical study allow differentiation between benign and malignant lesions, thus guiding treatment.

To date, the location of the chin has not been reported in the literature, hence the interest of our study. Excisional surgery without special margins is often indicated.

## CASE REPORT

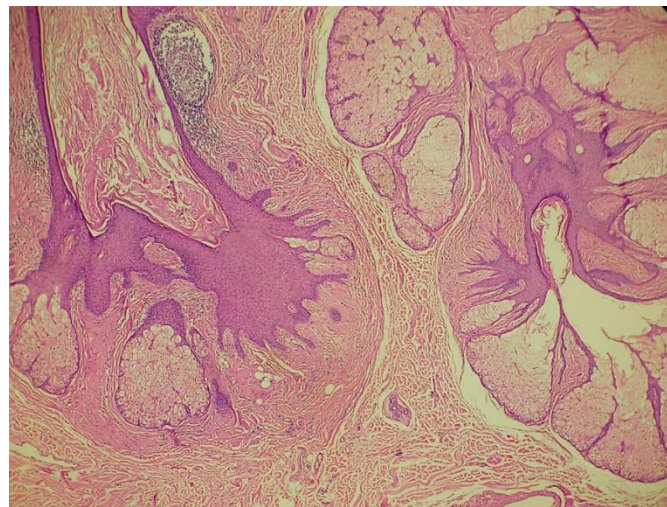
A 74-year-old patient was referred to our Maxillofacial Surgery Department at the Ibn Sina Hospital in Rabat. He presented with a submental budding swelling of approximately 50 years' duration, for which he had undergone surgical reduction 40 years ago. The patient's medical and family history was without significant findings. Clinical examination revealed a submental mass, renal, without signs of inflammation, painless, fixed in relation to the deep plane, reaching down to the cricoid cartilage and measuring approximately 10 cm in long axis (Figure 1).



**Figure 1: Image showing the macroscopic appearance of the trichofolliculoma in our case**

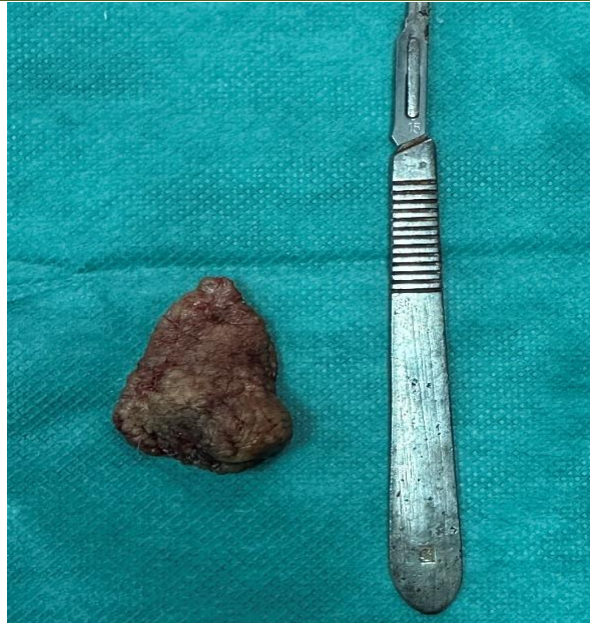In our case, a biopsy with anatomopathological examination was performed, which showed cystic formations of variable size, bordered by a well-differentiated squamous epithelium with hyperplasia of the basal layer associated with sebaceous glands and

hyperplastic sebaceous glands. These cystic structures are bordered by a predominantly mononuclear inflammatory infiltrate, confirming the diagnosis of trichofolliculoma (Figure 2).



**Figure 2: Photomicrograph of a trichofolliculoma showing cyst structures bordered by a squamous epithelium with hyperplastic keratinocytes attached. The contents are composed of keratinous lamellae which produce an inflammatory response on contact, HEX20**

The patient underwent surgical reduction and cauterisation of the residual mass with an electric scalpel under general anaesthesia.



**Figure 3: Image showing the surgical specimen**

## DISCUSSION

Trichofolliculoma (TF) is a rare and benign pilar tumor. TF is generally isolated, although multiple localizations have been reported. TF often presents in adulthood but in some cases may be present from birth with no definitive racial or gender predilection [4].

Trichofolliculoma was first described by Miescher in 1944. It presents as a dome-shaped, flesh-colored, nodular or papular lesion with a central pore through which an immature hair protrudes. In 1957, Hayman and Clayman described it as a follicular nevus. Later, Klingman proposed the name trichofolliculoma. TF is diagnosed clinically. It may also present as a typical tuft in the center of the lesion, described by some authors as a "fireworks" appearance [5]. This clinical aspect is not the same as in our case.

Almost all TF cases in literature were reported as single lesion, which is similar to our case. However, cases with multiple lesions had been described by Nomura and Cohen [6].

The mean age of onset of TF was 29, which is similar to our case. The sex ratio is 1 [7].

The etiopathogenesis of TF remains undefined. However, Kan *et al.* have developed an etiopathogenic hypothesis involving the alteration of two cell adhesion molecules; the decrease in E-cadherin expression, which is responsible for inhibiting the differentiation of hair progenitor cells, and the dynamization of CD 44, which allows certain newly generated cells to migrate to form the tumor [8].

The differential diagnosis of TF includes trichoepithelioma, tragus accessory, sebaceous cyst,

epidermal cyst, molluscum contagiosum, dilated Winer's pore, acanthoma of the pilar sheath, and basal cell carcinoma [9]. The notion of a prior trauma has also been implicated. In our case, this concept was absent.

Histopathological features of trichofolliculoma include a keratinous dermal cyst lined by squamous epithelium. Hair follicles radiate from the cyst wall. In all cases, these secondary hair follicles are connected by epithelial filaments. Trichofolliculoma can be distinguished from other hair follicular tumours by these histopathological features. Fine needle aspiration cytology of trichofolliculoma shows cohesive and branching clusters of keratinised squamous cells mixed with sebaceous cells [10, 11].

Although trichofolliculomas are considered benign, perineural invasion and recurrence after excision have been described in one patient.

The progression is often indolent. However, surgical treatment may be necessary if symptoms or functional or aesthetic discomfort occur. Aesthetic discomfort was the cause in our case.

As suggested for our patient, simple excisional surgery without surgical margins remains the treatment of choice for TF. However, excisional surgery with surgical margins may be considered for malignant adnexal tumors after multidisciplinary consultation, depending on the risk of recurrence and metastasis [5]. The prognosis is quite good and the risk of recurrence has rarely been the subject of reports.

## CONCLUSION

Trichofolliculoma is a benign or hamartomatous nodular neoplastic mass that rarely

affects the chin region. Histopathologic diagnosis is mandatory after excision. Long-term follow-up may be required if microscopic evidence of perineural invasion is found.

## REFERENCES

- Cribier, B. (2009). Trichofolliculome. In: Wechsler, J., editor. Pathologiecutané tumorale. Paris: Sauramps médical; p. 84-85.
- Kurokawa, I., Nishijima, S., Kusumoto, K., Sensaki, H., Shikata, N., & Tsubura, A. (2003). Trichofolliculoma: case report with immunohistochemical study of cytokeratins. *British Journal of Dermatology*, 148(3), 597-598.
- Misago, N., Kimura, T., Toda, S., Mori, T., & Narisawa, Y. (2010). A reevaluation of trichofolliculoma: the histopathological and immunohistochemical features. *The American journal of dermatopathology*, 32(1), 35-43.
- Howard, M. S., & Smoller, B. R. Trichofolliculoma. e-Medicine Dermatology. Available from: <http://www.emedicine.medscape.com>. [Last accessed on 2010 Aug 02]
- Fabre, F., Canihac, M., & Jouary, T. (2014). Trichofolliculome du cuir chevelu. *Ann Dermatol Venereol*, 141, 736-737.
- Nomura, M., & Hata, S. (1990). Sebaceous trichofolliculoma on scrotum and penis. *Dermatology*, 181(1), 68-70.
- Kapoor, A. G., Vijitha, V. S., & Mittal, R. (2019). Trichofolliculoma of the eyelid margin: a case report and review of literature. *Ophthalmic Plastic & Reconstructive Surgery*, 35(3), e74-e76.
- Kan, L., Liu, Y., McGuire, T. L., Bonaguidi, M. A., & Kessler, J. A. (2011). Inhibition of BMP signaling in P-Cadherin positive hair progenitor cells leads to trichofolliculoma-like hair follicle neoplasias. *Journal of biomedical science*, 18, 1-12.
- Lee, H. Y., Kim, E. K., Choi, H. S., & Jeong, J. (2023). Trichofolliculoma in the auricle. *Ear, Nose & Throat Journal*, 102(3), NP101-NP103.
- Ahmed, T. S., Del Priore, J., & Seykora, J. T. (2009). Tumors of the epidermal appendages. In: Elder, D. E., Elenitsas, R., Jaworsky, C., Johnson, B. Jr, editors. *Lever's Histopathology of the Skin*. 10th ed. (South Asian). New Delhi: Wolters Kluwer (India); pp. 854-859.
- Alexander, M. P., Makhija, P., & Jayaseelan, E. (2007). Fine needle aspiration cytology of trichofolliculoma: a case report. *Indian Journal of Pathology and Microbiology*, 50(4), 870-872.
- Stern, J. B., & Stout, D. A. (1979). Trichofolliculoma showing perineural invasion: Trichofolliculocarcinoma?. *Archives of Dermatology*, 115(8), 1003-1004.
- Panasiti, V., Roberti, V., Lieto, P., Visconti, B., Calvieri, S., & Perrella, E. (2013). The 'firework' pattern in dermoscopy. *International Journal of Dermatology*, 52(9), 1158-1159.
- Cohen, C., & Davis, T. S. (1986). Multiple trichogenic adnexal tumors. *The American journal of dermatopathology*, 8(3), 241-246.