

# Initial Experience with Endovascular Repair for Type B Aortic Dissection: Insights from the First 10 Cases at a Single Center

Arvin Thiruchelvam(MRCS)<sup>1\*</sup>, Muhammad Syakir Hasenan(MBBS)<sup>1</sup>, Ismazizi Zaharudin(MS Surgery)<sup>1</sup>

<sup>1</sup>Department of Cardiothoracic & Vascular Surgery, National Heart Institute, Kuala Lumpur, Malaysia

DOI: <https://doi.org/10.36347/sasjs.2025.v11i02.019>

| Received: 09.01.2025 | Accepted: 15.02.2025 | Published: 20.02.2025

\*Corresponding author: Arvin Thiruchelvam

Department of Cardiothoracic & Vascular Surgery, National Heart Institute, Kuala Lumpur, Malaysia

## Abstract

## Original Research Article

**Purpose:** This study was undertaken to evaluate the single center experience of endovascular intervention for Type B aortic dissection. **Methods:** Data were retrospectively analysed in 10 consecutive patients over the past 2 years (2021-2022) who had an endovascular intervention in IJN for Type B Aortic dissection. Patients' demographic, clinical and procedural data including preoperative characteristics and operative details were collected. Primary outcomes evaluated were mortality, stroke, spinal cord ischemia, vocal cord palsy and vascular access complications. **Results:** There were 10 patients who had Stanford Type B aortic dissection who underwent thoracic endovascular aortic repair (TEVAR). 1(10%) presented with acute aortic dissection, 6(60%) in the subacute stage and 3(30%) in the chronic stage. The majority of patients were male (90%), with a mean age of  $61.5 \pm 19.5$  years. TEVAR was performed till different zones, with no patients in Zone 0, 20% in Zone 1, 30% in Zone 2, 30% in Zone 3 and 20% in Zone 4 Aorta. While 50% of patients did not require any bypass for the neck vessels, 30% needed a single neck vessel chimney and 20% required surgical bypass. Average post operative hospital stay was 5.4 days (ranging 2-19 days). Postoperative vocal cord palsy occurred in 1 patient (10%) but no cases of vascular access injury, spinal hypoperfusion, cerebrovascular accident or mortality is reported in our study. **Conclusion:** Our study demonstrates that endovascular intervention with TEVAR for Type B aortic dissection in IJN resulted in favourable outcomes with low incidence of complications. However, given the small sample size, further studies with larger cohorts and longer duration of study is required to validate these findings.

**Keywords:** Type B aortic dissection, aortic surgery, endovascular, Malaysia.

Copyright © 2025 The Author(s): This is an open-access article distributed under the terms of the Creative Commons Attribution 4.0 International License (CC BY-NC 4.0) which permits unrestricted use, distribution, and reproduction in any medium for non-commercial use provided the original author and source are credited.

## BACKGROUND

Since its first description by Morgagni in 1761, our understanding of aortic dissection has significantly evolved [1]. Type B aortic dissection, unlike Type A, has undergone a diverse and evolving history of management strategies [2]. While surgical intervention has traditionally been the standard of care for Type A dissections, the treatment approaches for Type B dissections have progressively developed over time.

Key milestones in the management of Type B aortic dissection include:

**1935:** Gurin and associates introduced surgical iliac artery fenestration to address dissection-induced lower extremity ischemia.

**1955:** DeBakey and colleagues pioneered graft replacement of the dissected thoracic aorta, initially without bypass and later incorporating it.

**1965:** Wheat *et al.*, recommended medical management for descending thoracic aortic dissections.

**Early 1990s:** Endovascular interventions began, primarily with fenestration of dissection flaps to mitigate branch vessel compromise and malperfusion.

**1999:** Thoracic Endovascular Aortic Repair (TEVAR) was introduced for complicated acute Type B aortic dissections.

**2005:** The GORE TAG Pivotal Trial led to FDA approval of the GORE TAG endoprosthesis for descending thoracic aortic aneurysms [3].

**2013-2014:** The INSTEAD-XL trial provided further validation for endovascular approaches, resulting in FDA approval for the Medtronic Valiant stent.

The 2022 ACC/AHA Guidelines for Aortic Disease marked a paradigm shift, with strong recommendations favouring endovascular intervention

**Citation:** Arvin Thiruchelvam, Muhammad Syakir Hasenan, Ismazizi Zaharudin. Initial Experience with Endovascular Repair for Type B Aortic Dissection: Insights from the First 10 Cases at a Single Center. SAS J Surg, 2025 Feb 11(2): 205-210.

for Type B dissections [4]. This shift underpins the growing preference for TEVAR over traditional surgical or conservative management, reflecting its minimally invasive nature and favourable outcomes.

Our study aims to highlight the National Heart Institute (IJN)'s experience with TEVAR, contributing to the understanding of its application within the Malaysian context. By analyzing our first 10 cases, we hope to shed light on patient demographics, surgical techniques, and outcomes, providing valuable insights into the evolving management of Type B aortic dissection.

### Purpose

This study aims to evaluate the single-center experience of endovascular intervention for Type B aortic dissection at the National Heart Institute (IJN). A retrospective analysis of the first 10 consecutive cases over a two-year period (2021–2022) provides the foundation for this research. By focusing on patient demographics, clinical characteristics, and surgical details, the study seeks to contribute to a deeper understanding of the management and outcomes associated with thoracic endovascular aortic repair (TEVAR) for this condition.

A key objective of the study is to explore the demographic profile of patients who underwent TEVAR for Type B aortic dissections. This includes assessing variables such as age, gender, and the classification of dissections into acute, subacute, or chronic stages. Understanding these demographic factors is essential for identifying patterns or trends that could influence clinical decision-making and patient outcomes. Furthermore, analyzing the specific characteristics of the Malaysian population undergoing these interventions may provide insights into regional variations in presentation and management.

The study also delves into the surgical characteristics of the interventions, such as the extent of endovascular repair and the involvement of different aortic zones. Additionally, it examines the necessity of adjunct procedures like surgical or percutaneous bypass of arch vessels. By documenting these details, the study aims to highlight the technical considerations and challenges encountered in performing TEVAR for Type B dissections. This information can help refine procedural strategies and improve outcomes in future cases.

Lastly, the study evaluates key outcomes and endpoints, including in-hospital mortality, average postoperative hospital stay, and morbidity factors such as stroke, spinal cord hypoperfusion, vocal cord palsy, and vascular access complications. By providing a comprehensive analysis of these outcomes, the study intends to showcase IJN's initial experience with

TEVAR and its commitment to advancing the management of Type B aortic dissections. These findings are expected to serve as a foundation for future research and to contribute to the global understanding of endovascular interventions for aortic diseases.

## METHODS

This study utilized a retrospective analysis of patients who underwent thoracic endovascular aortic repair (TEVAR) for Stanford Type B aortic dissection at the National Heart Institute (IJN) over a two-year period (2021–2022). A total of 10 consecutive cases were included in the analysis. The mean age of the patients was  $61.5 \pm 19.5$  years. Data were collected from patient medical records, operative census logs, and the clinical research database to ensure comprehensive coverage.

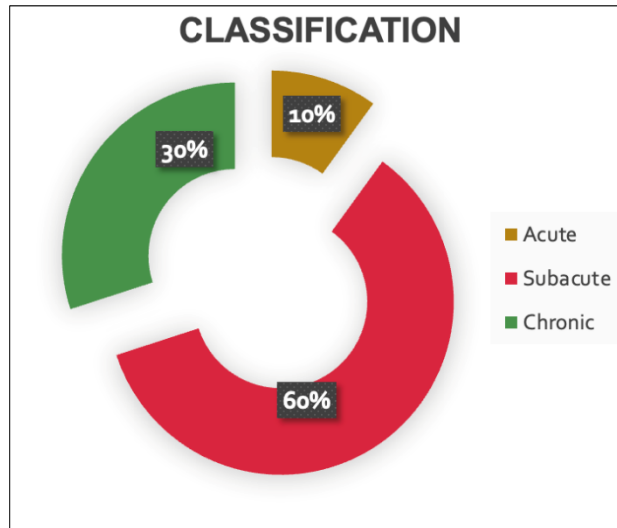
Patient demographics, clinical characteristics, and procedural details were meticulously reviewed. Demographic data included age, gender, and classification of Type B dissections into acute, subacute, and chronic stages. Procedural details, such as the extent of endovascular intervention and the aortic zones involved, were documented. The need for additional surgical or percutaneous bypass of arch vessels was also recorded.

Primary endpoints for this study included in-hospital mortality, average postoperative hospital stay, and morbidity outcomes. Morbidity factors assessed were the occurrence of new-onset stroke, spinal cord hypoperfusion, vocal cord palsy, and vascular access complications. These outcomes were used to evaluate the safety and efficacy of TEVAR in this patient cohort.

This single-center study represents an initial experience with TEVAR at IJN. As a nonrandomized, retrospective study with a small sample size, the findings provide preliminary insights into the management of Type B aortic dissections using endovascular techniques. Further research with larger cohorts and extended follow-up periods is needed to validate these results and refine treatment strategies.

## RESULTS

A total of 10 patients with Stanford Type B aortic dissection underwent thoracic endovascular aortic repair (TEVAR) at the National Heart Institute (IJN) during the two-year study period (2021–2022). The mean age of the patients was  $61.5 \pm 19.5$  years, and the majority (90%) were male. Among the cases, 10% presented with acute dissections, 60% in the subacute stage, and 30% in the chronic stage. This distribution highlights the variability in the timing of presentations and the need for tailored management strategies (Figure 1, Table 1).



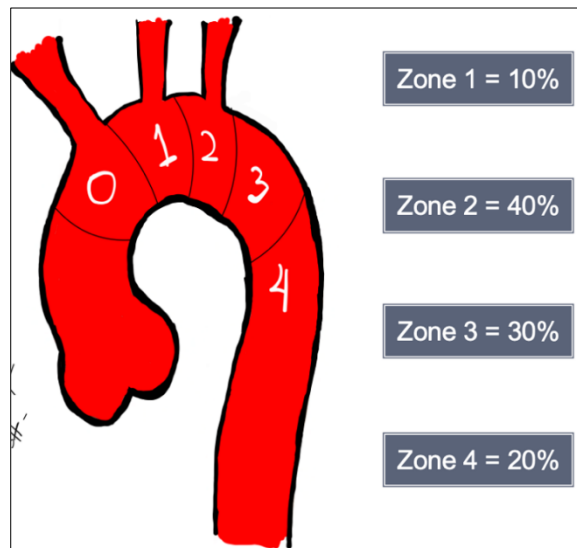
**Figure 1: Pie Chart of the breakdown of patients presenting in Acute, Subacute and Chronic Type B dissection**

**Table 1: Patients demography (Age and Gender)**

VARIABLES		n= 10 (%)
Gender	Female	1 (10.0)
	Male	9 (90.0)
Age	Mean ± SD	61.5 ± 19.5

TEVAR was performed across different aortic zones based on the extent of dissection and anatomical considerations. The procedures were distributed as follows: 10% in Zone 1, 40% in Zone 2, 30% in Zone 3,

and 20% in Zone 4. These findings reflect the technical diversity required for endovascular interventions and the need for expertise in managing dissections across various aortic segments (Figure 2).

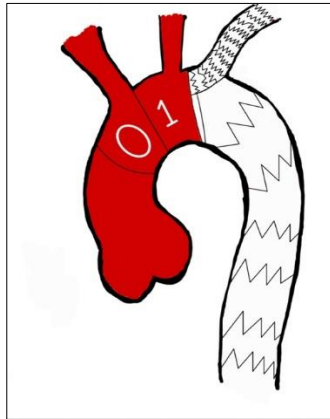


**Figure 2: Extent of Endovascular Intervention**

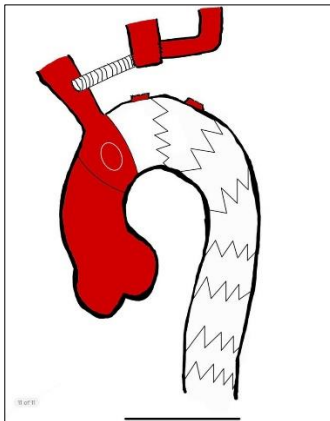
The management of neck vessels varied based on the dissection's anatomy and extent. While 50% of the patients did not require any bypass procedures, 30% underwent a single neck vessel chimney, and 20% required surgical bypass of arch vessels. Among the latter group, one patient underwent a Zone 1 TEVAR

with total arch vessel debranching, including the transposition of the Left Subclavian Artery (LSA) to the Left Common Carotid Artery (LCCA) and a graft from the brachiocephalic artery to the LCCA. The other patient underwent a Zone 2 TEVAR with transposition of the LSA to the LCCA. These approaches demonstrate

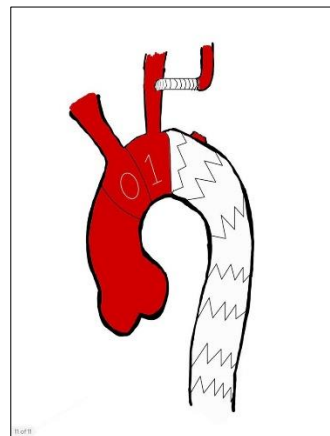
the flexibility of endovascular techniques in accommodating diverse patient anatomies and ensuring sufficient perfusion to vital areas (Figure 3, 4, 5).



**Figure 3: Zone 2 TEVAR with LSA Chimney**



**Figure 4: Zone 1 TEVAR with total arch vessel debranching with transposition of Left Subclavian Artery (LSA) to Left Common Carotid Artery (LCCA) and graft from brachiocephalic artery to LCCA**



**Figure 5: Zone 2 TEVAR with transposition of LSA to LCCA**

The average postoperative hospital stay was 5.4 days, with a range of 2 to 19 days. This relatively short length of stay reflects the minimally invasive nature of TEVAR compared to open surgical procedures. Importantly, no in-hospital mortalities were reported among the cohort, consistent with global benchmarks reporting 30-day in-hospital mortality rates of 0–5%.

These results underscore the safety of TEVAR when performed in a specialized center.

Postoperative morbidity was minimal in this study, with only one patient (10%) experiencing vocal cord palsy. There were no recorded instances of new-onset stroke, spinal cord hypoperfusion, or vascular

access complications. These findings highlight the favorable risk profile of TEVAR and its effectiveness in minimizing complications. Such outcomes are

encouraging for the continued adoption of endovascular approaches in managing Type B aortic dissections (Table 2).

**Table 2: Results of the secondary endpoints**

Complication	(n)	(%)
Cerebrovascular Accident	0	0
Spinal Cord Hypoperfusion	0	0
Vascular access complications	0	0
Vocal Cord Palsy	1	10.0

## DISCUSSION

The management of Type B aortic dissection (TBAD) has undergone significant evolution, transitioning from conservative medical therapy and open surgery to minimally invasive endovascular techniques [2, 6]. The introduction of thoracic endovascular aortic repair (TEVAR) has been revolutionary, offering a less invasive approach with reduced morbidity and mortality [3, 4]. Our study, which evaluated TEVAR outcomes for TBAD at the National Heart Institute (IJN), aligns with global trends emphasizing the efficacy and safety of endovascular intervention [5-7].

Our findings demonstrated no in-hospital mortality among the 10 patients treated with TEVAR, with morbidity limited to one case (10%) of vocal cord palsy. These outcomes are consistent with the results reported by other centers, such as the International Registry of Acute Aortic Dissection (IRAD), where endovascular interventions have achieved low mortality and morbidity rates [5, 7]. The absence of complications like spinal cord ischemia, stroke, or vascular access injuries in our cohort highlights the precision and effectiveness of TEVAR in a specialized setting [3, 6, 7]. However, our study's small sample size limits the generalizability of these findings.

The demographic profile of our patients showed a mean age of 61.5 years and a predominance of males (90%). This reflects similar patterns in global data, where male patients with underlying hypertension represent the majority of TBAD cases. Notably, our cohort included patients in the acute (10%), subacute (60%), and chronic (30%) phases of dissection. This distribution emphasizes the importance of tailoring management strategies to the timing of presentation, as each phase poses unique challenges for intervention [6, 8, 9].

The procedural diversity observed in our study, with TEVAR performed across Zones 1 to 4, underscores the complexity of managing TBAD [6, 8]. Fifty percent of patients did not require neck vessel bypass, while 30% underwent single vessel chimney procedures and 20% required surgical bypass. This variability reflects the nuanced decision-making process involved in TEVAR planning, where patient anatomy, aortic zone involvement, and perfusion requirements must all be considered [6, 10]. Our results reaffirm TEVAR's adaptability in addressing diverse anatomical challenges [6, 10].

Despite the promising results, several limitations must be acknowledged. Our study is a retrospective analysis from a single center with a small sample size, which may not capture the broader spectrum of TBAD presentations and outcomes [6, 8, 9]. Furthermore, the absence of long-term follow-up data limits our ability to assess the durability of TEVAR. Moving forward, larger, multicenter studies with extended follow-up are essential to validate these findings and refine TEVAR techniques [6, 7, 10]. The establishment of a national registry for aortic dissections, modelled after IRAD, would provide a robust platform for data collection and analysis, facilitating improvements in patient care across Malaysia [5, 7, 8].

In conclusion, our experience with TEVAR at IJN demonstrates its safety and efficacy in managing TBAD, with excellent short-term outcomes and minimal complications [3, 8, 10]. As endovascular technology and expertise continue to advance, TEVAR is poised to remain a cornerstone of TBAD management [3, 8, 11]. Future research should focus on optimizing patient selection, procedural planning, and long-term surveillance to further improve outcomes for this complex condition [8, 10, 11].

## CONCLUSION

The management of Type B aortic dissection has significantly evolved with the advent of thoracic endovascular aortic repair (TEVAR), offering a minimally invasive alternative to traditional approaches. Our study highlights the safety and efficacy of TEVAR in managing Type B aortic dissection at the National Heart Institute (IJN). With no in-hospital mortality and minimal complications observed in our cohort, TEVAR demonstrated excellent short-term outcomes, reinforcing its role as a first-line intervention for this condition.

While our findings align with international data, the study's small sample size and retrospective nature underscore the need for larger, multicenter research to validate these results and explore long-term outcomes. Future studies should aim to refine patient selection criteria, optimize procedural techniques, and establish robust follow-up protocols to enhance the durability of TEVAR and patient prognosis.

As the landscape of aortic disease management continues to evolve, the integration of national registries and collaborative efforts will be pivotal in driving improvements in care. Our findings contribute to the growing body of evidence supporting TEVAR as a safe, effective, and adaptable solution for the treatment of Type B aortic dissection, with the potential to improve survival and quality of life for affected patients.

**Acknowledgements:** None.

**Funding:** None.

**Informed Consent:** Retrospective data collection. Informed consent not applicable.

**Conflict of Interest:** The authors declare that there is no conflict of interest.

**Ethics Committee Approval:** Not required.

**Human and Animal Rights:** No animals involved.

**Statements and Declaration:** Not available

## REFERENCES

- Demers P, Miller DC. Type A aortic dissection. In: Selke FW, del Nido PJ, Swanson SJ, editors. *Sabiston & Spencer: Surgery of the Chest*. 9th ed. Philadelphia: Elsevier; 2016. p. 1214–43
- Demers P, Miller DC. Type B Aortic Dissection. In: Selke Frank W, del Nido PJ, Swanson SJ, editors. *Sabiston & Spencer: surgery of the chest*. 9th ed. Philadelphia: Elsevier; 2016. p. 1244–59.
- Makaroun, M. S., Dillavou, E. D., Kee, S. T., Sicard, G., Chaikof, E., Bavaria, J., ... & GORE TAG Investigators. (2005). Endovascular treatment of thoracic aortic aneurysms: results of the phase II multicenter trial of the GORE TAG thoracic endoprosthesis. *Journal of vascular surgery*, 41(1), 1-9.
- Makaroun, M. S., Dillavou, E. D., Kee, S. T., Sicard, G., Chaikof, E., Bavaria, J., ... & GORE TAG Investigators. (2005). Endovascular treatment of thoracic aortic aneurysms: results of the phase II multicenter trial of the GORE TAG thoracic endoprosthesis. *Journal of vascular surgery*, 41(1), 1-9.
- Hagan, P. G., Nienaber, C. A., Isselbacher, E. M., Bruckman, D., Karavite, D. J., Russman, P. L., ... & Eagle, K. A. (2000). The International Registry of Acute Aortic Dissection (IRAD): new insights into an old disease. *Jama*, 283(7), 897-903. doi:10.1001/jama.283.7.897
- Isselbacher, E. M., Preventza, O., Black, J. H. III., Augoustides, J. G., Beck, A. W., ... & Bolen, M. A. (2022). 2022 ACC/AHA guideline for the diagnosis and management of aortic disease: a report of the American Heart Association/American College of Cardiology Joint Committee on Clinical Practice Guidelines. *Circulation*, 146(24), e482. doi:10.1161/CIR.0000000000001106.
- Evangelista, A., Isselbacher, E. M., Bossone, E., Gleason, T. G., Eusanio, M. D., Sechtem, U., ... & Eagle, K. A. (2018). Insights from the international registry of acute aortic dissection: a 20-year experience of collaborative clinical research. *Circulation*, 137(17), 1846-1860. doi:10.1161/CIRCULATIONAHA.117.031264.
- Geirsson, A., Ahlsson, A., Franco-Cereceda, A., Fuglsang, S., Gunn, J., Hansson, E. C., ... & Gudbjartsson, T. (2016). The Nordic Consortium for acute type A aortic dissection (NORCAAD): objectives and design. *Scandinavian Cardiovascular Journal*, 50(5-6), 334-340. doi:10.1080/14017431.2016.1235284.
- Ahn, J. M., Kim, H., Kwon, O., Om, S. Y., Heo, R., Lee, S., ... & Song, J. K. (2019). Differential clinical features and long-term prognosis of acute aortic syndrome according to disease entity. *European Heart Journal*, 40(32), 2727-2736. doi:10.1093/eurheartj/ehz153.
- Czerny, M., Grabenwöger, M., Berger, T., Aboyans, V., Della Corte, A., Chen, E. P., ... & EACTS/STS Scientific Document Group Siepe Matthias Estrera Anthony L Bavaria Joseph E Pacini Davide Okita Yutaka Evangelista Arturo Harrington Katherine B Kachroo Puja Hughes G Chad. (2024). EACTS/STS Guidelines for diagnosing and treating acute and chronic syndromes of the aortic organ. *European Journal of Cardio-Thoracic Surgery*, 65(2), ezad426. doi:10.1093/ejcts/ezad426.