

Shield Ulcer in Vernal Keratoconjunctivitis

Shinji Makino^{1*}¹Inoda Eye Clinic, Nasushiobara, Tochigi 329-3156, JapanDOI: <https://doi.org/10.36347/sjmcr.2025.v13i02.016>

| Received: 16.01.2025 | Accepted: 21.02.2025 | Published: 22.02.2025

*Corresponding author: Shinji Makino

Inoda Eye Clinic, Nasushiobara, Tochigi 329-3156, Japan

Abstract

Case Report

We present a 14-year-old girl with shield ulcer due to vernal keratoconjunctivitis. Slit lamp examination revealed more prominent giant papillae on superior tarsal conjunctiva giving cobblestone appearance in the right eye than in the left eye. In addition, an oval-shaped shield ulcer with a transparent base on the right cornea was detected. The left cornea was unremarkable. She was treated with topical tacrolimus hydrate and flumetholon drops twice a day. Two months later, giant papillae gradually improved and shield ulcer healed with mild corneal opacity. Clinicians should be aware of corneal findings and importance of eyelid eversion in patients with vernal keratoconjunctivitis.

Keywords: Vernal Keratoconjunctivitis, Shield Ulcer.

Copyright © 2025 The Author(s): This is an open-access article distributed under the terms of the Creative Commons Attribution **4.0 International License (CC BY-NC 4.0)** which permits unrestricted use, distribution, and reproduction in any medium for non-commercial use provided the original author and source are credited.

INTRODUCTION

Vernal keratoconjunctivitis (VKC) is a recurrent, bilateral, allergic disease of the ocular surface with intermittent seasonal aggravations [1]. The symptoms of VKC are severe itching, burning, irritation, conjunctival redness, increased tear production, swelling of conjunctiva and eyelids, photophobia, and mucous secretion. The clinical findings are commonly related to conjunctival involvement. Conjunctival signs are hypertrophy, infiltrates and nodules in the limbus and giant papillary hypertrophy in the superior palpebral conjunctiva. Corneal shield ulcer is a rare and painless manifestation that occurs in 3–11% of patients with VKC [1, 2].

Herein, we report a 14-year-old girl with shield ulcer due to VKC.

CASE REPORT

A 14-year-old girl presented with pain in the right eye and itching in both eyes. Slit lamp photographs examination revealed more prominent giant papillae on superior tarsal conjunctiva giving cobblestone appearance in the right eye (Figure 1a) than in the left eye (Figure 1b). In addition, an oval-shaped shield ulcer with a transparent base on the right cornea was detected (Figure 1c). The left cornea was unremarkable (Figure 1d). Thus, she was diagnosed with shield ulcer due to VKC in the right eye. She was treated with topical tacrolimus hydrate and flumetholon drops twice a day. Two months later, giant papillae gradually improved and shield ulcer healed with mild corneal opacity.

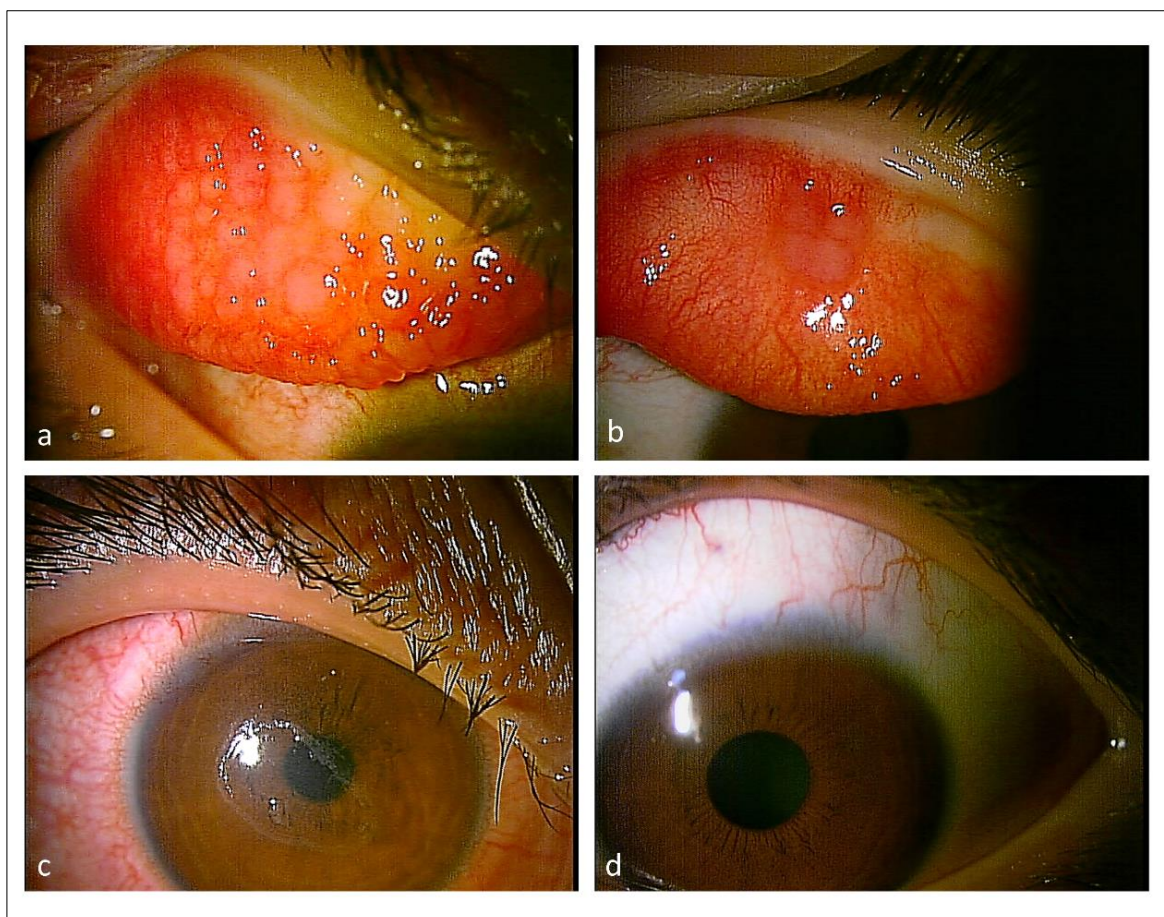


Figure 1: Slit-lamp photographs of the right (a, c) and the left (b, d) eyes

Note giant papillae on superior tarsal conjunctiva giving cobblestone appearance more prominent in the right eye (a) than in the left eye (b). Note shield ulcer with transparent ulcer bed in the right cornea (c). The left cornea was unremarkable (d).

DISCUSSION

Vernal keratoconjunctivitis is a recurrent, bilateral, allergic disease of the ocular surface in the first decade of life. Shield ulcers are serious complications of VKC. In the largest observational case series, corneal shield ulcers were detected 9.7% of 195 cases [1]. The presence of giant papillae on the superior palpebral conjunctiva is the characteristic sign of VKC. The giant papillary structure of the superior palpebral conjunctiva leads to constant mechanical damage, consequently, corneal involvement occurs. Also, inflammatory mediators may increase this injury even more. Shield ulcers, corneal plaques, and opacities, keratoconus, and keratitis may develop due to this persistent damage. Vernal shield ulcer is characteristically oval or pentagonal shaped, superficial, and locates mostly superior to the cornea. A grayish opacification may be seen at the basis of the ulcer, and the borders may be elevated slightly. If inflammatory material and debris accumulate based on an ulcer, an opaque plaque occurs. Cameron [2], suggested a classification system for shield ulcers depending on the clinical features. The basis and

borders of Grade-1 shield ulcers are clear and there is no apparent inflammatory material. Only medical treatment is generally enough for the regeneration of the epithelium. As a result of inflammatory material at the basis of ulcer, re-epithelization of Grade-2 ulcer is prolonged. They have a poor response to medical therapy, so surgical intervention may be necessary for management. Grade-3 shield ulcers have an elevated plaque above the level of the surrounding epithelium.

Two hypotheses have been proposed to explain the pathogenesis of shield ulcers in VKC [2]. In the mechanical hypothesis, giant papillae on the upper tarsal conjunctiva are believed to be responsible for mechanically abrading the cornea. In the toxin hypothesis, inflammatory mediators are thought to initiate damage to the corneal epithelium. The standard protocol for treating VKC includes antihistamines, inhibitors of mast cell degranulation, topical steroids, and immunomodulating therapy such as tacrolimus or cyclosporine [3]. Because of vision-threatening complications, shield ulcers should be treated aggressively.

CONCLUSION

Clinicians should be aware of corneal findings and importance of eyelid eversion in patients with VKC.

Conflicts of Interest: The authors have no financial or proprietary interests related to this paper.

REFERENCES

1. Bonini, S., Bonini, S., Lambiase, A., Marchi, S., Pasqualetti, P., Zuccaro, O., ... & Bucci, M. G. (2000). Vernal keratoconjunctivitis revisited: a case series of 195 patients with long-term followup. *Ophthalmology*, 107(6), 1157-1163.
2. Cameron, J. A. (1995). Shield ulcers and plaques of the cornea in vernal keratoconjunctivitis. *Ophthalmology*, 102(6), 985-993.
3. Roumeau, I., Coutu, A., Navel, V., Pereira, B., Baker, J. S., Chiambaretta, F., ... & Dutheil, F. (2021). Efficacy of medical treatments for vernal keratoconjunctivitis: a systematic review and meta-analysis. *Journal of Allergy and Clinical Immunology*, 148(3), 822-834.