

Efficacy of 0.4% Glyceryl Trinitrate Ointment and 2% Lidocaine Gel in the Treatment of Anal Fissure in Children: A Comparative Study

Dr. Md. Raisul Islam^{1*}, Prof. Dr. Susankar Kumar Mondal², Dr. Meherun Khan Methila³, Dr. Muhammad Mahbubur Rahman⁴, Dr. Jishan Mahmud⁵, Dr. Most. Mahfuja Parvin⁵, Dr. Sanjana Shahreen Antona⁵

¹Resident Surgeon (Paediatric Surgery), Rangpur Medical College Hospital, Rangpur, Bangladesh

²Professor, Department of Paediatric Surgery, Bangabandhu Sheikh Mujib Medical University, Dhaka, Bangladesh

³Resident Surgeon, Department of Surgery, Rangpur Medical College Hospital, Rangpur, Bangladesh

⁴Resident Surgeon (Paediatric Surgery), Sir Salimullah Medical College & Miford Hospital, Dhaka, Bangladesh

⁵Resident, Department of Paediatric Surgery, Bangabandhu Sheikh Mujib Medical University, Dhaka, Bangladesh

DOI: <https://doi.org/10.36347/sasjs.2025.v11i02.030>

| Received: 15.01.2025 | Accepted: 19.02.2025 | Published: 25.02.2025

*Corresponding author: Dr. Md. Raisul Islam

Resident Surgeon (Paediatric Surgery), Rangpur Medical College Hospital, Rangpur, Bangladesh

E-mail: rizurpmc@gmail.com

Abstract

Original Research Article

Background: Anal fissures in children cause painful anal canal tears, requiring careful management to prevent prolonged discomfort and complications. Though 0.4% Glyceryl Trinitrate (GTN) or 2% Lidocaine gel show promise in adults, their effectiveness and safety in pediatrics remain uncertain. This study aimed to compare the efficacy of 0.4% Glyceryl Trinitrate ointment and 2% Lidocaine gel in the treatment of anal fissures in children. **Methods:** This prospective, comparative study was conducted in the Outpatient Department of Paediatric Surgery, Bangabandhu Sheikh Mujib Medical University, Dhaka, Bangladesh from March 2022 to August 2023. This study enrolled 52 anal fissure patients aged 3-16 years of both genders. They were divided into two groups: Group I received 0.4% GTN ointment, and Group II received 2% Lidocaine gel. Ethical approval was obtained, and SPSS 23.0 was used. **Results:** Most (80.8%) acute anal fissure patients achieved symptomatic improvement and complete healing with 0.4% GTN, whereas 26.9% improved with 2% lidocaine gel ($p < 0.05$). Improvement took over a month in 52.4% (group I) and 57.1% (group II) ($p > 0.05$). All experienced perianal pain. Constipation affected 88.5% (group I) and 73.1% (group II). Headache (15.4%) and postural hypotension (7.7%) occurred in group I. **Conclusion:** Chemical sphincterotomy is an effective first-line treatment for anal fissures. Both glyceryl trinitrate (GTN) and 2% lidocaine gel aid management, but topical GTN provides superior healing, symptom relief, and sustained improvement with minimal, manageable side effects.

Keywords: Anal fissure, Chemical sphincterotomy, 0.4% glyceryl trinitrate, 2% Lidocaine gel.

Copyright © 2025 The Author(s): This is an open-access article distributed under the terms of the Creative Commons Attribution 4.0 International License (CC BY-NC 4.0) which permits unrestricted use, distribution, and reproduction in any medium for non-commercial use provided the original author and source are credited.

INTRODUCTION

Anal fissures are a common and painful condition in children, characterized by tears in the anoderm, leading to significant discomfort and distress [1]. Management requires careful consideration to relieve pain, promote healing, and minimize complications. Various conservative treatments, including dietary modifications, stool softeners, and topical agents, are commonly used before considering surgical interventions [2,3]. Topical treatments are often the first line of therapy for anal fissures in pediatric patients. Glyceryl trinitrate (GTN) ointment, a nitric oxide donor, functions by relaxing the internal anal sphincter, thereby reducing sphincter pressure and enhancing blood flow to the fissure site, which facilitates healing [4]. However, its use has been associated with side effects such as headaches, which may limit its

acceptability, especially in the pediatric population [5]. Lidocaine gel, a local anesthetic, provides symptomatic relief by numbing the affected area, thereby reducing pain during defecation [6]. While lidocaine addresses pain, it does not directly promote the healing of the fissure, and its efficacy as a monotherapy in children remains uncertain [7]. A prospective, randomized, double-blind study comparing the efficacy of diltiazem, glyceryl trinitrate, and lidocaine for the treatment of anal fissure in children found that diltiazem had a higher healing rate compared to GTN and lidocaine [8]. Another randomized clinical trial comparing topical lignocaine with diltiazem or glyceryl trinitrate for pediatric acute anal fissure concluded that the combination of diltiazem and lignocaine was more effective than glyceryl trinitrate and lignocaine in relieving symptoms and promoting healing [9]. Despite these findings, there is limited

Citation: Md. Raisul Islam, Susankar Kumar Mondal, Meherun Khan Methila, Muhammad Mahbubur Rahman, Jishan Mahmud, Most. Mahfuja Parvin, Sanjana Shahreen Antona. Efficacy of 0.4% Glyceryl Trinitrate Ointment and 2% Lidocaine Gel in the Treatment of Anal Fissure in Children: A Comparative Study. SAS J Surg, 2025 Feb 11(2): 255-260.

research specifically comparing the efficacy of GTN ointment and lidocaine gel in the pediatric population [9]. Given the differences in their mechanisms of action—GTN promoting healing through sphincter relaxation and lidocaine providing pain relief—it is important to determine which treatment offers superior outcomes for children with anal fissures [10]. This study aimed to fill this gap by conducting a prospective, comparative analysis of 0.4% GTN ointment and 2% lidocaine gel in the treatment of anal fissures in children. By evaluating the efficacy and safety profiles of these two treatments, the study seeks to provide evidence-based guidance for clinicians in selecting the most appropriate therapy for pediatric patients suffering from this painful condition.

METHODOLOGY

This was a prospective, comparative study conducted at the Outpatient Department of Pediatric Surgery, Bangabandhu Sheikh Mujib Medical University (BSMMU), Dhaka, Bangladesh, from March 2022 to August 2023. The study included 52 patients aged 3 to 16 years, of both genders, diagnosed with acute anal fissures. A purposive sampling technique was employed. Patients were randomly assigned to two groups: Group I received 0.4% glyceryl trinitrate (GTN) ointment, and Group II received 2% lidocaine gel. Both groups were treated with conservative measures, including sitz baths, stool softeners, analgesics, behavioral therapy, and dietary advice. The topical applications were instructed to be applied circumferentially 1 cm around the anus and inside the anal canal every 12 hours for 8 weeks. The first dose was administered under supervision, and patients were observed for 6 hours. Parents were advised to report any unusual symptoms. Clinical reviews were scheduled at 1, 4, and 8 weeks to assess symptoms and complications. Inclusion criteria consisted of patients aged 3 to 16 years

with acute anal fissures, while exclusion criteria included those with secondary anal fissures or associated perianal conditions. The study received approval from the ethical committee of BSMMU, and data were analyzed using SPSS version 23.0.

RESULT

In this study, the majority of patients in both groups were aged 5-10 years, with 53.8% in Group I and 69.2% in Group II. The mean age was 6.56 ± 3.06 years for Group I and 7.6 ± 2.61 years for Group II. A higher proportion of females was observed in Group I (69.2%) compared to Group II (57.7%). All patients in both groups presented with perianal pain (100%). Clinical symptoms included perianal bleeding, with 50% of Group I and 38.5% of Group II reporting this symptom. Itching was reported in 65.4% of Group I and 46.2% of Group II. Constipation was common in both groups, with 88.5% of Group I and 73.1% of Group II affected. Symptomatic improvement was evaluated at three-time points. After one week, 53.8% of Group I and 61.5% of Group II showed improvement. After four weeks, 69.2% of Group I and 42.3% of Group II experienced symptomatic relief. At the eight-week follow-up, 80.8% of Group I had symptomatic improvement compared to 26.9% in Group II, with this difference being statistically significant ($p < 0.05$). Complete healing of fissures was observed in 38.5% of Group I and 11.5% of Group II after four weeks, with 80.8% of Group I and 26.9% of Group II achieving full healing by eight weeks. This difference was also statistically significant ($p < 0.05$). The duration of improvement exceeded one month in 52.4% of Group I and 57.1% of Group II, though the difference was not statistically significant ($p > 0.05$). Side effects included headache in 15.4% of Group I, and postural hypotension in 7.7% of Group I, with no such effects reported in Group II.

Table 1: Distribution of demographic profile (N=52)

Characteristics	Group I		Group II	
	(n=26)		(n=26)	
	n	%	n	%
Age (Years)				
<5 Yrs.	8	30.8%	3	11.5%
5-10 Yrs.	14	53.8%	18	69.2%
11-15 Yrs.	4	15.4%	5	19.2%
Mean ±SD	6.56±3.06		7.6±2.61	
Gender				
Male	8	30.8%	11	42.3%
Female	18	69.2%	15	57.7%

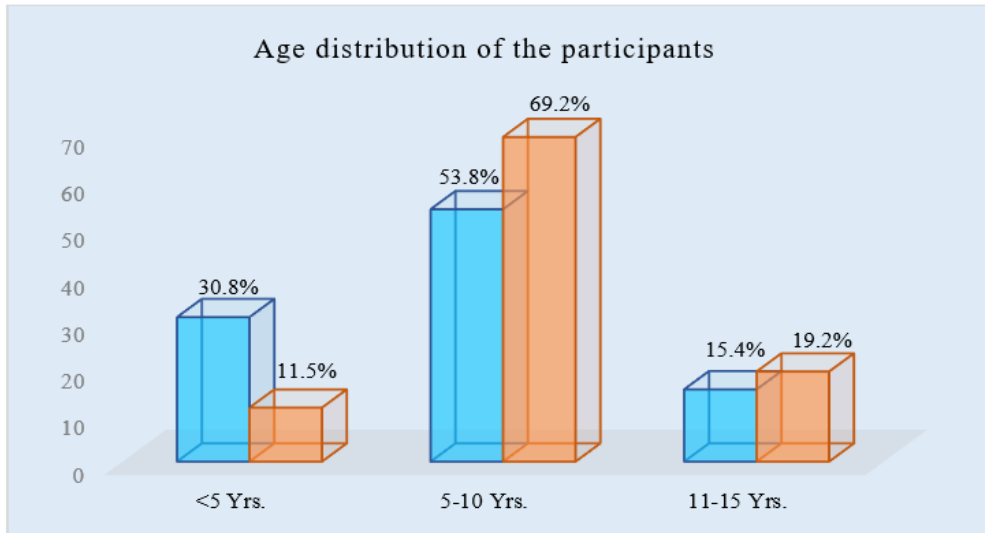


Figure I: Column chart showed age wise *patients* distribution (N=52)

Table 2: Distribution of clinical presentation (N=52)

Variables	Group I		Group II	
	n	%	n	%
Perianal pain				
Yes	26	100%	26	100%
No	0	0	0	0%
P/R bleeding				
Yes	13	50%	10	38.5%
No	13	50%	16	61.5%
Itching				
Yes	17	65.4%	12	46.2%
No	9	34.6%	14	53.8%
Diarrhea				
No	26	100	26	100
Constipation				
Yes	23	88.5%	19	73.1%
No	3	11.5%	7	26.9%

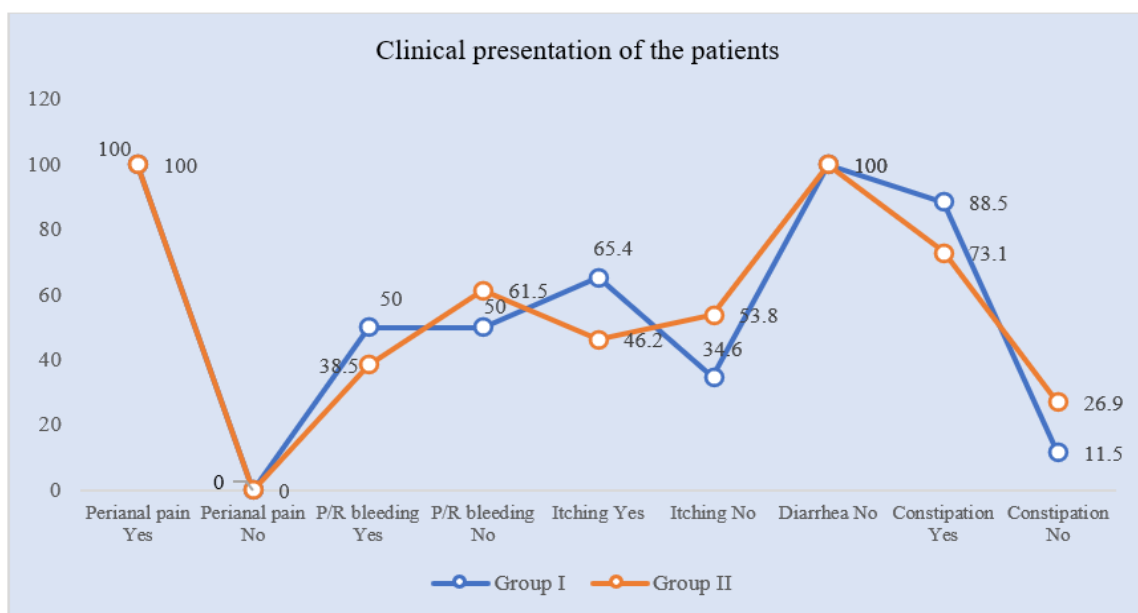


Figure II: Line chart showed clinical presentation wise *patients* distribution (N=52)

Table 3: Distribution of symptomatic improvement/response (N=52)

Status	Group I		Group II		p-value
	n	%	n	%	
Response at follow-up after 1 week					
Yes	14	53.8%	16	61.5%	0.575 ^{ns}
No	12	46.2%	10	38.5%	
Response at follow-up after 4 weeks					
Yes	18	69.2%	11	42.3%	0.051 ^{ns}
No	8	30.8%	15	57.7%	
Response at follow-up after 8 weeks					
Yes	21	80.8%	7	26.9%	0.001 ^s
No	5	19.2%	19	73.1%	

Table 4: Distribution of healing of fissure (N=52)

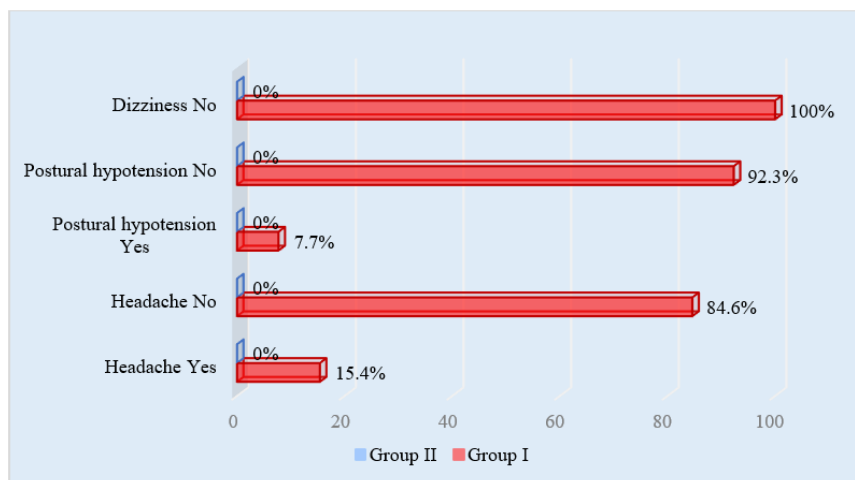
Status	Group I		Group II		p-value
	n	%	n	%	
Complete healing at follow-up after 4 weeks					
Yes	10	38.5%	3	11.5%	0.025 ^s
No	16	61.5%	23	88.5%	
Complete healing at follow-up after 8 weeks					
Yes	21	80.8%	7	26.9%	0.001 ^s
No	5	19.2%	19	73.1%	

Table 5: Complete healing as per the duration of improvement (N=52)

Duration	Group I		Group II		p-value
	n	%	n	%	
≤1 month	10	47.6%	3	42.9%	0.827 ^{ns}
>1 month	11	52.4%	4	57.1%	

Table 6: Side effects following treatment (N=52)

Parameter	Group I		Group II	
	n	%	n	%
Headache				
Yes	4	15.4%	0	0%
No	22	84.6%	0	0%
Postural hypotension				
Yes	2	7.7%	0	0%
No	24	92.3%	0	0%
Dizziness				
No	26	100%	0	0%

**Figure III: Bar chart showed side effects following treatment (N=52)**

DISCUSSION

This study aimed to compare the efficacy of 0.4% Glyceryl Trinitrate (GTN) ointment and 2% Lidocaine gel in the treatment of anal fissures in children. The findings suggest that 0.4% GTN ointment exhibited superior outcomes compared to 2% Lidocaine gel in terms of long-term healing and symptomatic improvement. These results are consistent with another study demonstrating the efficacy of GTN in promoting healing and symptom relief in anal fissures [11]. The mean age of patients in both groups was similar, with a higher proportion of children aged 5-10 years in both groups. This is in line with the typical age range for anal fissures, which often affect younger children due to the anatomical and physiological characteristics of the anal canal during early childhood [12]. Additionally, a higher proportion of females in Group I was observed, which could be attributed to potential differences in the anatomical or hormonal factors influencing the prevalence of anal fissures in younger girls [13]. Perianal pain was reported by all patients in both groups, a common symptom of anal fissures [14]. Other symptoms, such as perianal bleeding, itching, and constipation, were also prevalent in both groups, with Group I (GTN) showing slightly higher rates of itching and constipation. These symptoms are frequently observed in children with anal fissures and reflect the discomfort and complications associated with the condition [15]. Symptomatic improvement was more pronounced in Group I over time, with significant improvement observed by the 8-week follow-up. This is consistent with the findings of several studies where GTN was shown to have a more sustained effect on symptom relief and healing compared to other treatments [16,17]. The statistically significant difference at the 8-week follow-up supports the longer-term benefits of 0.4% GTN in promoting complete healing and alleviating symptoms such as pain and itching [18]. In terms of complete healing, a higher percentage of patients in Group I achieved full recovery by 8 weeks, which is consistent with previous research highlighting the effectiveness of GTN in achieving complete healing in anal fissures [19]. Although 2% Lidocaine gel provided quick pain relief, it did not show the same long-term benefits in terms of complete healing, supporting the notion that while Lidocaine can be used for immediate symptom management, GTN is more effective for sustained healing. Regarding side effects, the occurrence of headaches and postural hypotension in Group I was relatively mild and manageable. These side effects are well-documented in studies involving GTN, but they are generally transient and do not significantly affect the overall treatment efficacy [1,15]. No side effects were observed in Group II, indicating that 2% Lidocaine gel is generally well-tolerated, although it may not offer the same level of therapeutic benefit as GTN. Overall, this study suggests that 0.4% GTN ointment is more effective than 2% Lidocaine gel for the treatment of acute anal fissures in children, offering sustained improvement, greater healing rates, and manageable side

effects. While Lidocaine gel is useful for immediate pain relief, GTN should be considered for long-term management of anal fissures.

LIMITATION OF THE STUDY

This study has several limitations. First, the sample size was relatively small, which may limit the generalizability of the findings. Second, the study was conducted at a single institution, which may introduce institutional bias. Additionally, the study relied on subjective measures such as symptom reports from parents, which may lead to response bias.

CONCLUSION & RECOMMENDATION

The healing rate of acute anal fissures was significantly better in Group I (0.4% Glyceryl Trinitrate ointment) compared to Group II (2% Lidocaine gel). Notably, complete healing, symptomatic improvement, and both early and sustained recovery were more frequently observed in the 0.4% GTN group. While 2% Lidocaine gel was effective for immediate pain relief in acute anal fissures, 0.4% GTN demonstrated greater long-term benefits in terms of healing and symptomatic improvement, with minimal and manageable side effects. Therefore, 2% Lidocaine gel may be used for immediate pain relief, but for long-term and sustained improvement, 0.4% GTN is the preferred treatment option.

REFERENCES

1. Cevik, M., Boleken, M. E., Koruk, I., Ocal, S., Balcioglu, M. E., Aydinoglu, A., & Karadag, C. A. (2012). A prospective, randomized, double-blind study comparing the efficacy of diltiazem, glyceryl trinitrate, and lidocaine for the treatment of anal fissure in children. *Pediatric surgery international*, 28, 411-416.
2. Nelson, R. (2004). A systematic review of medical therapy for anal fissure. *Diseases of the colon & rectum*, 47, 422-431.
3. Jin, J. Z., Hardy, M. O., Unasa, H., Mauiliu-Wallis, M., Weston, M., Connolly, A., ... & Hill, A. G. (2022). A systematic review and meta-analysis of the efficacy of topical sphincterotomy treatments for anal fissure. *International Journal of Colorectal Disease*, 1-15.
4. JN, L. (1997). A randomized, prospective, double blind, place-controlled trial of glyceryl trinitrate ointment in treatment of anal fissure. *Lancet*, 349, 11-14.
5. Antropoli, C., Perrotti, P., Rubino, M., Martino, A., De Stefano, G., Migliore, G., ... & Piazza, P. (1999). Nifedipine for local use in conservative treatment of anal fissures: preliminary results of a multicenter study. *Diseases of the colon & rectum*, 42(8), 1011-1015.
6. Carapeti, E. A., Kamm, M. A., & Phillips, R. K. (2000). Topical diltiazem and bethanechol decrease anal sphincter pressure and heal anal fissures

- without side effects. *Diseases of the colon & rectum*, 43(10), 1359-1362.
7. Jost, W. H., & Schimrigk, K. (1993). Use of botulinum toxin in anal fissure. *Diseases of the Colon & Rectum*, 36(10), 974.
 8. Ahmed, M., Ahmad, J. A. M., Sheikh, M. A., Latif, T., & Qayyum, A. (2020). Topical Lignocaine with Diltiazem or Glyceryltrinitrate for Paediatric Acute Anal Fissure: A Randomized Clinical Trial. In *Proceedings* (Vol. 34, No. 4, pp. 70-75).
 9. Fulas, O. A., & Coderre, T. J. (2022). Topical analgesics. *Clinical Pain Management: A Practical Guide*, 198-205.
 10. Nikhil, S. (2015). *A Comparative Study of Lateral Sphincterotomy and 2% Diltiazem Gel Local Application in the Treatment of Chronic Fissure in Ano* (Master's thesis, Rajiv Gandhi University of Health Sciences (India)).
 11. Kennedy, M. L., Sowter, S., Nguyen, H., & Lubowski, D. Z. (1999). Glyceryl trinitrate ointment for the treatment of chronic anal fissure: results of a placebo-controlled trial and long-term follow-up. *Diseases of the colon & rectum*, 42, 1000-1006.
 12. Mehic, R., Indreica, V., Marcu, V., Beuran, M., & Chiotoroiu, A. L. (2020). Special conditions in the treatment of hemorrhoidal disease. The advantages of THD-RAR in the treatment of hemorrhoidal disease in these situations. *Romanian medical JouRnal*, 67(3), 260.
 13. Khayatan, D., Lemberg, D. A., & Day, A. S. (2024). The Role of Topical Tacrolimus in the Management of Inflammatory Bowel Disease: A Comprehensive Review. *Journal of clinical medicine*, 13(18), 5518.
 14. Abolhassani, H., Tavakol, M., Chavoshzadeh, Z., Mahdavian, S. A., Momen, T., Yazdani, R., ... & Aghamohammadi, A. (2019). National consensus on diagnosis and management guidelines for primary immunodeficiency. *Immunology and Genetics Journal*, 1-21.
 15. Patkova, B., & Wester, T. (2020). Anal fissure in children. *European Journal of Pediatric Surgery*, 30(05), 391-394.
 16. Kennedy, M. L., Sowter, S., Nguyen, H., & Lubowski, D. Z. (1999). Glyceryl trinitrate ointment for the treatment of chronic anal fissure: results of a placebo-controlled trial and long-term follow-up. *Diseases of the colon & rectum*, 42, 1000-1006.
 17. Nelson, R. L., Manuel, D., Gumienny, C., Spencer, B., Patel, K., Schmitt, K., ... & Yeboah-Sampong, A. (2017). A systematic review and meta-analysis of the treatment of anal fissure. *Techniques in coloproctology*, 21, 605-625.
 18. Joda, A. E., & Al-Mayoof, A. F. (2017). Efficacy of nitroglycerine ointment in the treatment of pediatric anal fissure. *Journal of pediatric surgery*, 52(11), 1782-1786.
 19. Siboe, M. M. W. (2014). A double-blind randomized controlled trial comparing effectiveness of 0.2% topical nifedipine versus 0.2% topical glyceryl trinitrate in the treatment of chronic anal fissure.