

## Surprising Image of a Meckel's Diverticulum and an Abscessed Appendix

Badr Moujahid<sup>1\*</sup>, Achraf Bahi<sup>1</sup>, Ibrahim Zouhry<sup>1</sup>, Hamada Abdelilah<sup>1</sup>, Anwar Rahali<sup>1</sup>, Abdelmounaim Ait Ali<sup>1</sup>

<sup>1</sup>Mohammed V Military Teaching Hospital, Department of General Surgery, Rabat, Morocco

DOI: <https://doi.org/10.36347/sasjs.2025.v11i03.003>

| Received: 25.01.2025 | Accepted: 27.02.2025 | Published: 01.03.2025

\*Corresponding author: Badr Moujahid

Mohammed V Military Teaching Hospital, Department of General Surgery, Rabat, Morocco

### Abstract

### Clinical Image

Meckel's diverticulum (MD), a congenital abnormality resulting from incomplete obliteration of the proximal omphalomesenteric duct during the 7th week of gestation (making it the most prevalent congenital malformation of the gastrointestinal tract) [1]. Shares overlapping clinical features with acute appendicitis, a common surgical emergency, making simultaneous presentation diagnostically challenging. Given its diverse clinical manifestations, MD can be challenging to diagnose. Symptomatic MD commonly presents with bleeding, followed by intestinal obstruction, diverticulitis, intussusception, and, rarely, neoplasm or perforation [2]. In this context, we present an image of MD and an abscessed appendix diagnosed during laparotomy and confirmed postoperatively.

**Keywords:** Diverticulum; Appendix; Appendectomy; Diverticulectomy.

Copyright © 2025 The Author(s): This is an open-access article distributed under the terms of the Creative Commons Attribution 4.0 International License (CC BY-NC 4.0) which permits unrestricted use, distribution, and reproduction in any medium for non-commercial use provided the original author and source are credited.

### INTRAOPERATIVE IMAGE

Meckel's diverticulum (MD) has a prevalence of 1 to 2% in the general population. It is most often discovered incidentally during abdominal surgery [3].

In adults, the necessity for preventive resection of an asymptomatic MD to prevent acute complications or degeneration remains debated [4, 5].

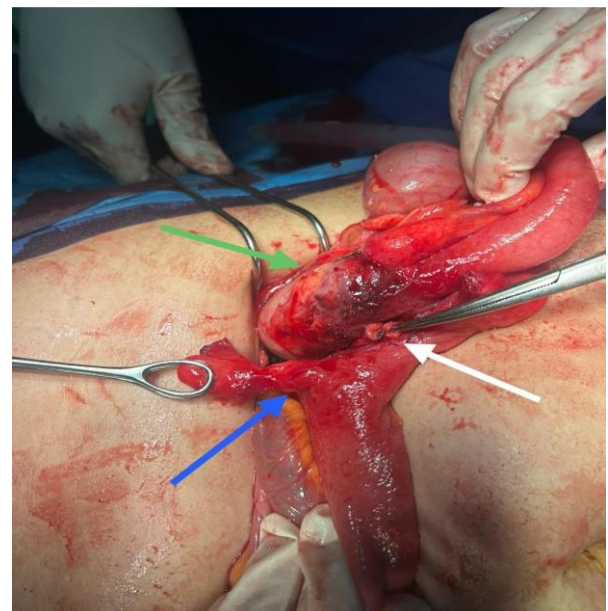
A 53-year-old female patient with a history of hypothyroidism was admitted for suspected appendicitis. Her symptoms began 20 days earlier with pain in the right iliac fossa, along with nausea and vomiting in a febrile context.

The abdominal exam revealed tenderness in the right iliac fossa with psoitis and a positive Rovsing sign. The infectious workup showed elevated markers, and ultrasound revealed a swollen, laterocaecal appendix complicated by an appendiceal abscess.

Initial management included fluid resuscitation, analgesia, and antibiotic prophylaxis. Subsequently, a laparotomy was performed, during which peritoneal effusion was aspirated. Intraoperative exploration revealed two distinct structures:

1. The MD originating from the last ileal loop (Fig 1, blue arrow), attached to the cecal base (Fig 1, white arrow).

2. The appendix, which was latero-caecal, swollen, and abscessed (Fig 1, green arrow).



**Figure 1: Intraoperative image showing a Meckel's diverticulum (blue arrow) and an abscessed appendix (green arrow)**

We proceeded with an appendectomy and diverticulectomy while preserving the carrying ileal loop. Histological analysis of the two surgical specimens

confirmed the diagnosis of Meckel's diverticulum and an abscessed appendix.

Postoperative recovery was marked by early rehabilitation and the resumption of digestive transit on the 3rd postoperative day.

## REFERENCES

1. Ihedioha, U., Panteleimonitis, S., Patel, M., Duncan, A., & Finch, G. J. (2012). An unusual presentation of Meckel's diverticulum. *Journal of Surgical Case Reports*, 2012(3), 4-4.
2. Ding, Y., Zhou, Y., Ji, Z., Zhang, J., & Wang, Q. (2012). Laparoscopic management of perforated Meckel's diverticulum in adults. *International Journal of Medical Sciences*, 9(3), 243-247.
3. Zani, A., Eaton, S., Rees, C. M., & Pierro, A. (2008). Incidentally detected Meckel diverticulum: to resect or not to resect?. *Annals of surgery*, 247(2), 276-281.
4. Park, J. J., Wolff, B. G., Tollefson, M. K., Walsh, E. E., & Larson, D. R. (2005). Meckel diverticulum: the Mayo Clinic experience with 1476 patients (1950–2002). *Annals of surgery*, 241(3), 529-533.
5. Ruscher, K. A., Fisher, J. N., Hughes, C. D., Neff, S., Lerer, T. J., Hight, D. W., ... & Campbell, B. T. (2011). National trends in the surgical management of Meckel's diverticulum. *Journal of Pediatric surgery*, 46(5), 893-896.