

Postoperative (Pressure) Alopecia on Head Rest Fixation Pointes Area, Following Intracranial Removal of Meningioma: A Rare but Disturbing Complication to Consider

Achraf Moussa^{1*}, Hatim Belfquih¹, Brahim Elmostarchid¹, Amine Adraoui¹, Hassan Baallal¹, Ali Akhaddar¹

¹Department of Neurosurgery, Avicenne Military Hospital, Cadi Ayyad University, Marrakech, Morocco and Mohammed V University in Rabat, Rabat, Morocco

DOI: <https://doi.org/10.36347/sasjs.2025.v11i03.012>

| Received: 24.01.2025 | Accepted: 26.02.2025 | Published: 08.03.2025

*Corresponding author: Achraf Moussa

Department of Neurosurgery, Avicenne Military Hospital, Cadi Ayyad University, Marrakech, Morocco and Mohammed V University in Rabat, Rabat, Morocco

Abstract

Case Report

Postoperative (pressure) alopecia (PPA) is a very rare complication, well known by cardiologic surgeons and plasticiens. PPA localized in head rest fixation pointes is exceptionally reported by neurosurgeons. To report a case of PPA localized at head rest fixation pointes. A 50-year-old man presented a PPA occipital localized head rest fixation pointes one month postoperatively following intracranial removal of anterior fossa meningioma. This alopecia disappears spontaneously and totally three month ago. The mechanism of this PPA is discussed. This complication must be considered in postoperative follow-up if intracranial surgery with expected blood loses and lengthy surgery.

Keywords: Postoperative (Pressure) Alopecia, Head Rest Fixation, Meningioma, Spontaneous Regression.

Copyright © 2025 The Author(s): This is an open-access article distributed under the terms of the Creative Commons Attribution 4.0 International License (CC BY-NC 4.0) which permits unrestricted use, distribution, and reproduction in any medium for non-commercial use provided the original author and source are credited.

INTRODUCTION

Post-operative compression alopecia, commonly referred to as “post operative (pressure) alopecia”, is very rare. Described in cardiovascular surgery and well known to anesthetists, it is very rarely described by neurosurgeons. (1, 2, 3, 4). We report a case of transient alopecia localized on the headpiece fixation points.

OBSERVATION

Mr D.R., 50 YO, was admitted to neurosurgery for treatment of an anterior meningioma. His history was unremarkable. No arterial hypertension or diabetes. No history of syphilis, alopecia or known dermatological disease. Symptomatology began 8 months ago with intractable headaches. For the past two months, the patient and family have noticed frequent memory disorders and behavioural problems. There is no epilepsy.

On admission, the patient was in good general condition, euphoric and indifferent to his illness. Blood pressure was 15/7 cmhg, pulse 74 beats per minute. Neurological examination revealed no sensory or motor deficits. There is a reflex grasping and a note of collectionism testifying to a frontal syndrome. Osteotendinous reflexes are present. The cutaneo-plantar is in extension. Coordination is normal. The nausea reflex is present. No coordination disorders.

Examination of the upper functions shows: a very advanced anterograde memory syndrome, with the patient unable to retain three words after 5 minutes. The fundus revealed bilateral papilledema. The rest of the somatic examination was unremarkable. Cutaneous examination was unremarkable. Cerebral computed tomography (CT) showed a bilateral basifrontal process predominantly on the right side, with a mass effect. This lesion presents.

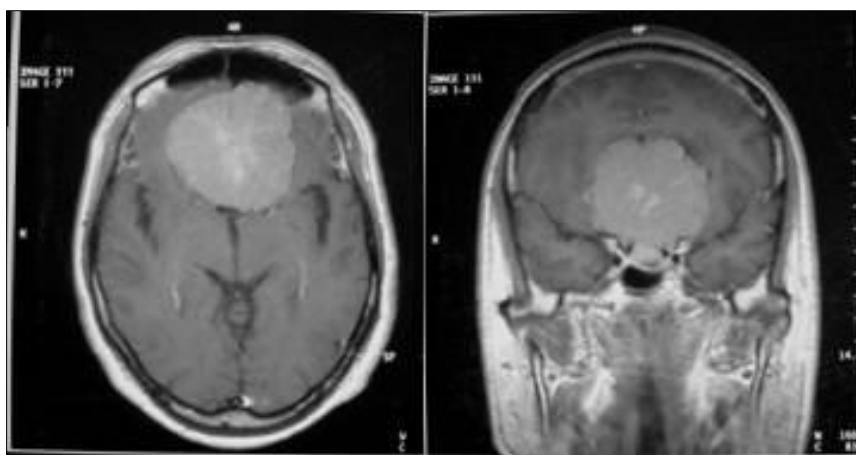


Figure 1: Cerebral MRI in T1 sequence after intravenous contrast injection, in axial section (left) and coronal section (right) showing an anterior stage meningioma

The patient was operated with a unilateral frontal flap extending beyond the midline through a bitragal incision, with fixation on the Mayfield headrest in the dorsal decubitus position. Operating time was 6h30 min. Blood loss was 1.8 liters. No shock or hypotension was recorded during the operation. Exeresis was total. The patient was extubated the same day. He was transferred to the neurosurgery department after 24 hours in intensive care. The post-operative course was straightforward, with rapid improvement in the memory syndrome. Postoperative CT confirmed total excision.

Histological study showed a transitional meningioma with no sign of malignancy.

One month later, at follow-up, round hair loss was noted centered on the two occipital points of the headpiece fixation. The right measured 2 cm (Figure 2), the left 1.5 cm. Dermatological examination ruled out ringworm or underlying pathology. Three months later, the alopecia disappeared spontaneously without any treatment. The patient's personal hygiene was normal, with normal shampoos. No recurrence was observed after 48 months.

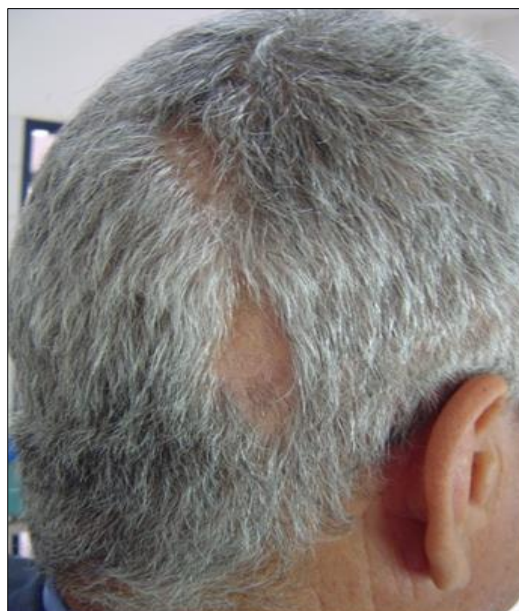

Figure 2: One-month postoperative photo of the patient with right occipital alopecia centered on the headpiece attachment points.

DISCUSSION

Our patient presented with transient postoperative alopecia centered on the headpiece fixation points, which regressed spontaneously after three months without any particular therapy, care or personal hygiene.

Described by the term “postoperative pressure alopecia” in the Anglo-Saxon literature, this observation is exceptional in neurosurgical circles, given the number of craniotomies performed with Mayfield head fixation. While postoperative alopecia is known to cardiovascular

surgeons, plastic surgeons and gynecologists, it is very rarely reported in the neurosurgical literature.

Credit must go to Abel and Lewis [1], who in 1960 were the first to describe alopecia in 8 women undergoing gynecological surgery after prolonged procedures.

Calla S, and col in 1996, following a Medline search, could find only two cases in the last 35 years [4].

Observations have been reported in cardiovascular surgery after cardiac arrest. Anesthetists and plastic surgeons have taken an interest in this entity [3-5].

Described by the term “postoperative pressure alopecia”, these reports have been reported in patients with an operative time of more than 6 hours and in patients with cardiopulmonary bypass [4-6].

The pathophysiological mechanism is probably ischemia produced by compression. This ischemia is due to prolonged immobilization of the head during surgery. Other incriminating factors include hypotension, massive blood loss and the use of scalp vasoconstrictors. Other factors incriminated were prolonged endo-tracheal intubation and prolonged immobilization of the head. Our patient had no risk factors other than duration and fixation with Mayfield spikes. The role of anaesthetic drugs appears to be minimally incriminated. The presence of edema and pain, sometimes with ulceration, in the first 24 h or even the first few days, should raise the possibility of postoperative pressure alopecia [1].

Alopecia is generally complete from 3 to 28 days post-op. In our patient, none of these signs attracted our attention. Hair regrowth occurs on average after 12 weeks. Permanent alopecia has been reported [6].

The best treatment remains preventive. Post-operative alopecia has been prevented by changing the position of the head every 30 minutes during cardiac surgery [1-7]. It seems difficult, if not impossible, during intracranial surgery. Changing the head-fixed position is the only one possible.

CONCLUSION

Transient, or exceptionally permanent, postoperative alopecia following cranial surgery is a side effect to be considered if long-term surgery with blood loss is envisaged.

REFERENCES

1. ABEL, R. R., & LEWIS, G. M. (1960). Postoperative (pressure) alopecia. *AMA Archives of Dermatology*, 81(1), 34-42.
2. Boyer, J. D., & Vidmar, D. A. (1994). Postoperative alopecia: a case report and literature review. *Cutis*, 54(5), 321-322.
3. Bruce, I. A., Simmons, M. A., & Hampal, S. (2002). ‘Horseshoe-shaped’ post-operative alopecia following lengthy head and neck surgery. *The Journal of Laryngology & Otology*, 116(3), 230-232.
4. Calla, S., Patel, S., Shashtri, N., & Shah, D. (1996). Occipital alopecia after cardiac surgery. *Canadian Journal of Anaesthesia*, 43(11), 1180-1181.
5. Dominguez, E., Eslinger, M. R., & McCord, S. V. (1999). Postoperative (pressure) alopecia: report of a case after elective cosmetic surgery. *Anesthesia & Analgesia*, 89(4), 1062.
6. Lawson, N. W., Mills, N. L., & Ochsner, J. L. (1976). Occipital alopecia following cardiopulmonary bypass. *The Journal of thoracic and cardiovascular surgery*, 71(3), 342-347.
7. Patel, K. D., & Henschel, E. O. (1980). Postoperative alopecia. *Anesthesia & Analgesia*, 59(4), 311-313.