

## Post-Traumatic Intra-Orbital Meningoencephalocele During Pregnancy: Case Report

Imad Daoudi<sup>1\*</sup>, Djoudline Doughmi<sup>1</sup>, Said Benlamkaddem<sup>1</sup>, Adnane Berdai<sup>1</sup>, Mustapha Harandou<sup>1</sup>

<sup>1</sup>Mother-Child ICU, Hassan II University Hospital, Faculty of Medicine, Pharmacy, and Dental Medicine, Sidi Mohamed Ben Abdellah University, 30 000, Fez, Morocco

DOI: <https://doi.org/10.36347/sasjs.2025.v11i04.007>

| Received: 12.03.2025 | Accepted: 15.04.2025 | Published: 24.04.2025

\*Corresponding author: Imad Daoudi

Mother-Child ICU, Hassan II University Hospital, Faculty of Medicine, Pharmacy, and Dental Medicine, Sidi Mohamed Ben Abdellah University, 30 000, Fez, Morocco

### Abstract

### Case Report

Intra-orbital meningoencephalocele (MEC) is a rare condition involving the herniation of brain tissue and meninges into the orbital cavity, typically associated with congenital anomalies, tumors, or trauma. Its occurrence during pregnancy is exceptionally uncommon and presents unique diagnostic and therapeutic challenges due to physiological changes and the dual imperative to protect maternal and fetal well-being. We report the first documented case of a pregnant woman with post-traumatic intra-orbital MEC. A 24-year-old woman at 12 weeks' gestation presented with polytrauma following a fall, manifesting with significant right periorbital swelling, exophthalmos, and visual impairment. Radiological evaluation revealed extensive craniofacial trauma, including a right orbital roof fracture with frontal lobe herniation into the orbit. Obstetric assessment confirmed fetal viability. A multidisciplinary team coordinated a staged management plan prioritizing both maternal stabilization and fetal safety. Neurosurgical intervention via frontal craniotomy enabled the excision of herniated brain tissue, dural closure, and orbital roof reconstruction. This was followed by orthopedic fixation of a femoral shaft fracture. The anesthetic management was adapted to minimize fetal exposure while ensuring maternal stability. Postoperative recovery was uneventful, with preserved vision and neurological function. Follow-up imaging confirmed successful reconstruction, and obstetric monitoring showed normal fetal development. This case underscores the feasibility and importance of timely surgical management of complex cranial pathologies during early pregnancy. It highlights the critical role of multidisciplinary coordination, individualized anesthetic planning, and the value of imaging in guiding surgical decision-making. Despite the high-risk context, both maternal and fetal outcomes were favorable, reinforcing that carefully tailored interventions can yield excellent results even in rare and complex scenarios.

**Keywords:** Intra-orbital meningoencephalocele, Multidisciplinary care, Surgery during pregnancy, Orbital roof fracture, Polytrauma.

**Copyright © 2025 The Author(s):** This is an open-access article distributed under the terms of the Creative Commons Attribution 4.0 International License (CC BY-NC 4.0) which permits unrestricted use, distribution, and reproduction in any medium for non-commercial use provided the original author and source are credited.

## INTRODUCTION

Intra-orbital meningoencephalocele (MEC) is an exceedingly rare condition involving the herniation of brain tissue, meninges, and cerebrospinal fluid into the orbital cavity through a defect in the orbital roof. While most commonly associated with congenital skull base malformations, MEC can also result from trauma or tumors (Cammarata *et al.*, 2022). Traumatic MEC is a particularly rare complication of orbital roof fractures, first described by Gardner in 1948, and is typically caused by high-energy impacts to the orbit or forehead (Gardner, 1948). These injuries often lead to complex craniofacial fractures accompanied by intracranial complications such as frontal lobe contusions, hemorrhage, and encephalocele (Wei *et al.*, 2016).

During pregnancy, trauma—including traumatic brain injuries (TBIs)—is the leading non-obstetric cause of maternal mortality (Huang *et al.*, 2024). Surgical management in pregnant patients is uncommon and presents unique challenges due to the physiological alterations of pregnancy and the need to safeguard both maternal and fetal health (Kazemi *et al.*, 2014). The literature addressing neurosurgical interventions and anesthetic strategies in this population is scarce, and no previous reports have described post-traumatic intra-orbital MEC in a pregnant patient.

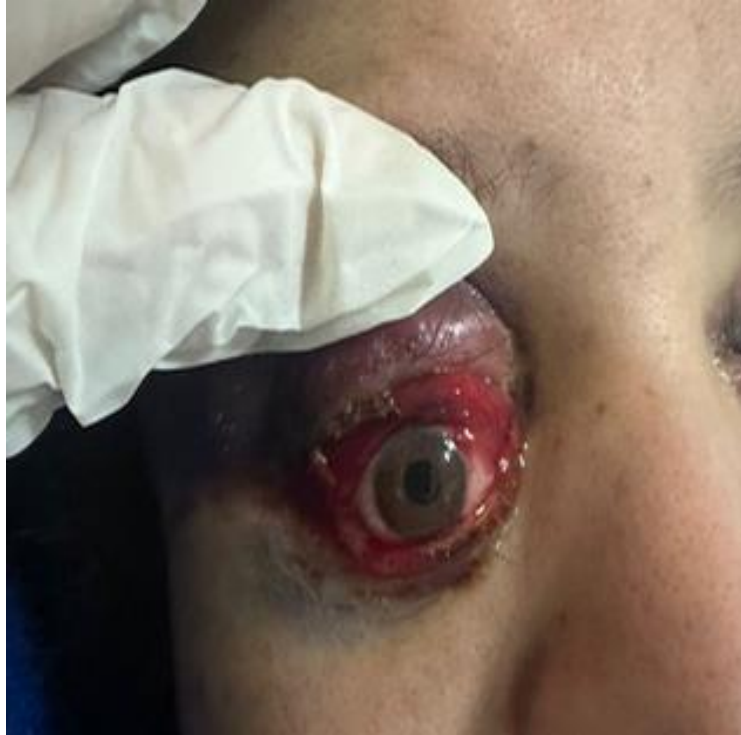We present the first known case of a post-traumatic intra-orbital MEC during pregnancy, exploring the diagnostic, anesthetic, and surgical complexities

encountered. This report adds to the limited literature at the intersection of neurosurgical trauma and pregnancy.

## CASE REPORT

A 24-year-old woman, gravida 1 para 0 at 12 weeks of gestation, with no significant medical history, was admitted to the emergency department following a fall down the stairs resulting in polytrauma. On

presentation, she was confused with a Glasgow Coma Scale (GCS) score of 14, but maintained stable respiratory and hemodynamic parameters. Clinical examination revealed marked right periorbital swelling, proptosis, eyelid edema, and hemorrhagic chemosis without conjunctival rupture (Figure 1). Visual disturbances and oculomotor impairment were suspected but difficult to assess. She also reported pain and complete functional loss of the right lower limb.

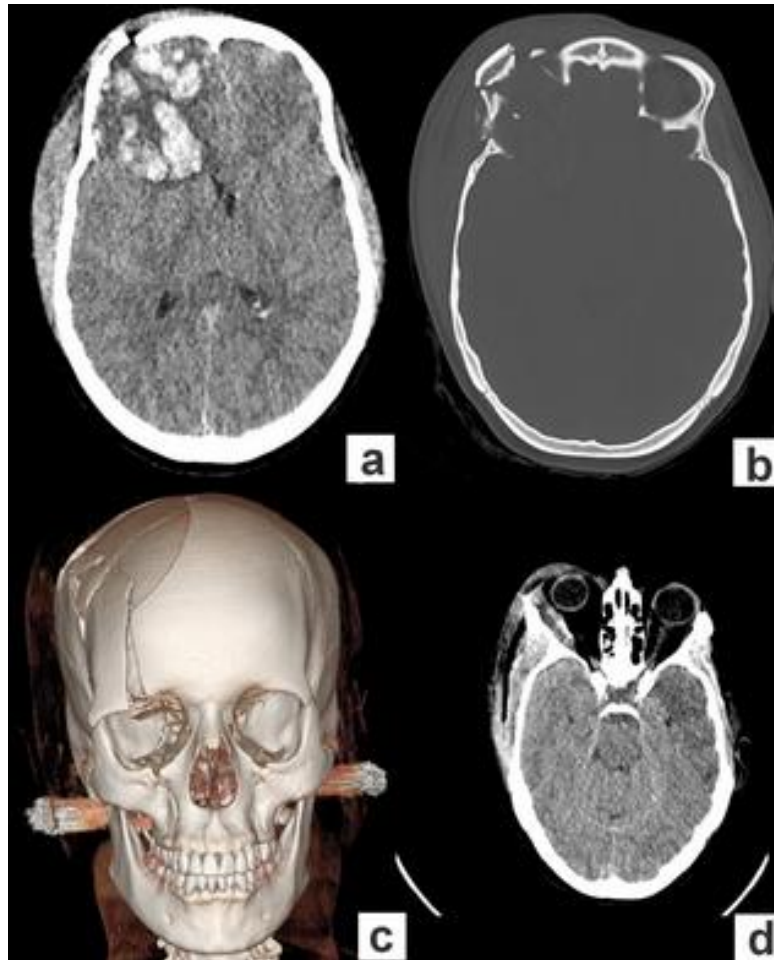


**Fig.1 Ophthalmic examination at the admission**

Marked right periorbital swelling, accompanied by right-sided proptosis, significant eyelid edema, and hemorrhagic chemosis without conjunctival rupture

A whole-body CT scan identified multiple cranial injuries, including depressed frontoparietal fractures with epidural hematomas, basilar skull fractures, frontal lobe contusions, subfalcine herniation, intraventricular hemorrhage, and cerebral edema. Facial

CT showed displaced fractures of the right orbital walls with a large fragment of the orbital roof displaced inward, causing herniation of the right frontal lobe into the orbit, leading to grade III proptosis (Figure 2). Additional fractures involved the maxillary sinus and zygomatic arch. A right femoral per-trochanteric fracture was also confirmed. Obstetric evaluation confirmed a viable intrauterine pregnancy with no signs of placental abruption.



**Fig.2 Preoperative CT scan with brain and bone windows**

Axial CT brain window showing frontal contusions with early subfalcine herniation, ventricular blood contamination, and cerebral edema (a). Bone window revealing depressed fractures of the frontoparietal bones, along with basilar skull fractures involving the greater wing of the sphenoid, sphenoid sinus, pterygoid process, and left carotid canal (b). 3D CT facial reconstruction illustrating complex displaced fractures of the right orbital walls, with a detached bony fragment from the orbital roof (c). Axial CT brain showing herniation of the right frontal lobe parenchyma into the orbit, causing severe grade III proptosis and significant ocular compression (d)

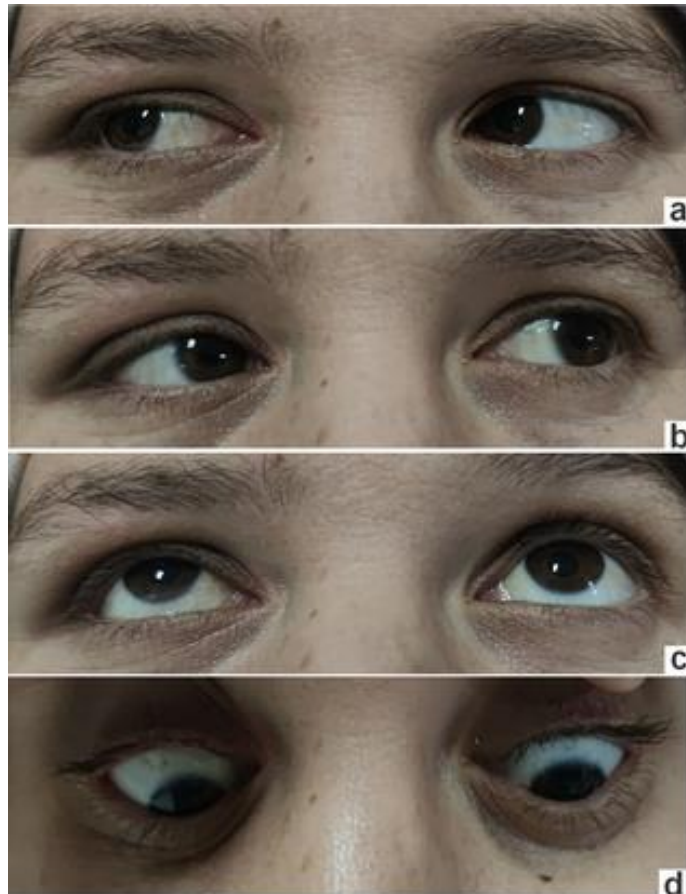She was admitted to the obstetric ICU, where a multidisciplinary team initiated a 48-hour stabilization phase, including invasive monitoring, neurological assessments, analgesia with intravenous paracetamol and morphine PCA, corticosteroids to reduce orbital edema, and close fetal surveillance.

Surgical treatment was performed under general anesthesia using total intravenous anesthesia (TIVA)

with propofol. Mannitol and methylprednisolone were administered to manage intracranial hypertension. A frontal craniotomy allowed resection of herniated frontal lobe tissue and intraorbital bone fragments. The dural defect was repaired with an epicranial graft, and the orbital roof reconstructed using an autologous iliac bone graft. Orthopedic stabilization of the femoral fracture with a gamma nail followed.

Postoperatively, the patient was extubated with a GCS of 15, remained neurologically intact, and maintained stable vital signs. The Intermittent fetal heart rate monitoring confirmed continued viability of the pregnancy. She was transferred from the ICU to the surgical ward after 48 hours and discharged on postoperative day five with a Glasgow Outcome Scale–Extended (GOSE) score of 7.

At two-month follow-up, she exhibited full neurological and ophthalmological recovery, with preserved ocular motility and a GOSE score of 8 (Figure 3). Ongoing obstetric assessments confirmed normal fetal development.



**Fig.3 Ocular Alignment and Motility at Two-Month Follow-Up. It demonstrates preserved visual axis alignment and intact extrinsic ocular motility**

The images depict voluntary eye movements in the rightward (A), leftward (B), upward (C), and downward (D) directions

## DISCUSSION

This case report describes the first known case of post-traumatic intra-orbital MEC in a pregnant patient, presenting a rare and complex clinical scenario. A 24-year-old woman, 12 weeks pregnant, was admitted with polytrauma after a fall, including craniofacial fractures and a femoral per-trochanteric fracture. She exhibited right-sided exophthalmos, visual disturbances, and was found on imaging to have a large orbital roof fracture with herniation of frontal brain tissue into the orbit. Despite the severity of her injuries, the patient was hemodynamically stable and neurologically preserved. A multidisciplinary team managed her case with a two-stage surgical approach: urgent neurosurgical repair of the orbital roof and dural defect, followed by orthopedic fixation. Anesthetic management was tailored to balance maternal cerebral protection and fetal safety. The patient was extubated postoperatively without complications and discharged five days later with a favorable neurological outcome. At two months, she demonstrated full recovery with no visual or neurological deficits and a stable, progressing pregnancy.

Trauma complicates an estimated 6 to 8 percent of all pregnancies, with falls, motor vehicle collisions, and assaults being the most common causes (Petroni *et al.*, 2019). The need for urgent surgical intervention in the setting of trauma is particularly delicate in pregnant patients, as physiological changes of gestation can exacerbate injury patterns while also complicating diagnostic and therapeutic decisions. These include increased circulating blood volume, dilutional anemia, elevated oxygen consumption, and altered coagulation profiles (Brenner, 2004).

From a pathophysiological standpoint, orbital roof fractures are classified as “blow-in” or “blow-out” injuries, depending on the direction of bony fragment displacement (Connon *et al.*, 2015). In blow-in fractures, such as seen in our patient, inward displacement compresses orbital contents, increasing intra-orbital pressure and reducing orbital volume. This predisposes to ocular complications such as proptosis, visual disturbances, and, in rare cases, meningoencephalocele. These fractures often follow direct frontal or lateral impact and are frequently associated with additional cranial injuries—including dural tears, brain contusions, epidural or subdural hematomas, and intra-orbital hemorrhage (Antonelli *et al.*, 2002).

The clinical signs of orbital MEC—particularly progressive exophthalmos, hemorrhagic chemosis, and visual impairment—must prompt urgent imaging evaluation. CT scanning remains the cornerstone for the acute diagnosis of craniofacial trauma, with thin-slice and 3D reconstruction techniques offering detailed characterization of bone and soft tissue relationships. Although magnetic resonance imaging (MRI) may provide superior soft tissue contrast for confirming MEC, its use is often limited in acute trauma due to logistical constraints, particularly in pregnant patients with concurrent orthopedic injuries, as seen here (Manfrè *et al.*, 1993).

Importantly, imaging in pregnancy—particularly CT with contrast—has historically raised concerns about fetal safety. However, contemporary guidelines support its use when clinically indicated, emphasizing that maternal stability and diagnosis take precedence. Low-osmolality iodinated contrast agents have not been associated with teratogenic effects in humans and are considered safe in emergencies (Expert Panel on Major Trauma Imaging *et al.*, 2020).

Surgical management of intra-orbital MEC must address multiple priorities: relieving intra-orbital pressure, preventing infection, repairing dural defects, and reconstructing the orbital roof to restore anatomy and preserve function. A bicoronal approach with frontal craniotomy remains the gold standard, offering optimal access to the anterior cranial fossa and orbit. Herniated brain tissue is typically resected, especially if devitalized or contaminated, and the dura is repaired with autologous or synthetic grafts. Orbital roof reconstruction can be performed with either a split bone flap or autologous iliac bone graft, as used in our case, or with titanium mesh in selected situations (Cammarata *et al.*, 2022; Duhem-Tonnelle *et al.*, 2008).

Anesthetic management during neurosurgery in pregnancy demands careful consideration of altered maternal physiology. Pregnant patients are at increased risk for aspiration, rapid desaturation, and difficult intubation due to mucosal edema and decreased functional residual capacity (McClelland *et al.*, 2008). TIVA with propofol was preferred in this case due to its favorable profile for managing intracranial pressure (ICP) and its relatively low placental transfer compared to volatile anesthetics. ICP was controlled intraoperatively using mannitol and corticosteroids. While mannitol crosses the placenta and may induce fetal dehydration, published case series suggest its safety at doses up to 1.7 g/kg, particularly when used judiciously in emergencies (Kazemi *et al.*, 2014).

Neurosurgery during pregnancy is associated with significant morbidity and mortality, though these risks are often linked to the underlying neurosurgical condition rather than the surgical or anesthetic management itself (Kazemi *et al.*, 2014). Recovery after

intra-orbital MEC is generally positive. A literature review of 28 patients reported a GOSE score of 8, indicating upper good recovery, in 82% of cases (Cammarata *et al.*, 2022). This aligns with the satisfactory neurological outcomes observed in our patient.

This study has several limitations that should be acknowledged. As a single case report, findings cannot be generalized to all similar scenarios. Long-term fetal outcomes were not available at the time of writing, and while intraoperative strategies such as the use of mannitol and corticosteroids were effective here, their safety in early pregnancy remains under-documented. Finally, the rarity of orbital MEC—especially in pregnancy—makes prospective studies difficult, limiting evidence-based recommendations.

## CONCLUSION

This case highlights the exceptional rarity and complexity of managing post-traumatic intra-orbital MEC during pregnancy, a clinical case that demands a multidisciplinary approach to balance maternal stabilization and fetal safety. The integration of advanced imaging, precise surgical interventions, and tailored perioperative care allowed for successful outcomes despite the unique challenges posed by the patient's condition. This case underscores the importance of recognizing rare surgical complications in the context of trauma and pregnancy, emphasizing the critical need for collaboration across specialties. Further studies are warranted to develop evidence-based guidelines for managing similar cases, improving outcomes for both maternal and fetal health in such high-risk scenarios.

**Acknowledgements:** None.

**Conflict of interest:** The authors declare that they have no conflict of interest.

## Ethics, Informed Consent, and Data Confidentiality Statement:

We confirm that oral and written informed consent was obtained from the patient and her relatives for the publication of this clinical case. All clinical data were handled in compliance with confidentiality standards, ensuring that the patient's privacy and personal information remain protected.

## REFERENCES

1. Antonelli, V., Cremonini, A. M., Campobassi, A., Pascarella, R., Zofrea, G., & Servadei, F. (2002). Traumatic encephalocele related to orbital roof fractures: Report of six cases and literature review. *Surgical Neurology*, 57(2), 117–125. [https://doi.org/10.1016/s0090-3019\(01\)00667-x](https://doi.org/10.1016/s0090-3019(01)00667-x)

2. Brenner, B. (2004). Haemostatic changes in pregnancy. *Thrombosis Research*, 114(5–6), 409–414. <https://doi.org/10.1016/j.thromres.2004.08.004>
3. Cammarata, G., Altieri, R., Certo, F., Petrella, L., Basile, A., Pizzo, A., Crimi, S., Battaglia, S., Bianchi, A., & Barbagallo, G. (2022). Post-traumatic intra-orbital meningoencephalocele in adults: Technical note on a rare entity and review of the literature. *Neurosurgical Review*, 46(1), 6. <https://doi.org/10.1007/s10143-022-01906-0>
4. Connon, F. V., Austin, S. J. B., & Nastri, A. L. (2015). Orbital Roof Fractures: A Clinically Based Classification and Treatment Algorithm. *Craniofacial Trauma & Reconstruction*, 8(3), 198–204. <https://doi.org/10.1055/s-0034-1393728>
5. Duhem-Tonnelle, V., Duhem, R., Mora, A.-R., Allaoui, M., & Assaker, R. (2008). [Traumatic orbital encephalocele in an adult: Report of one case]. *Neuro-Chirurgie*, 54(1), 28–31. <https://doi.org/10.1016/j.neuchi.2008.01.004>
6. Expert Panel on Major Trauma Imaging, Shyu, J. Y., Khurana, B., Soto, J. A., Biffl, W. L., Camacho, M. A., Diercks, D. B., Glanc, P., Kalva, S. P., Khosa, F., Meyer, B. J., Ptak, T., Raja, A. S., Salim, A., West, O. C., & Lockhart, M. E. (2020). ACR Appropriateness Criteria® Major Blunt Trauma. *Journal of the American College of Radiology: JACR*, 17(5S), S160–S174. <https://doi.org/10.1016/j.jacr.2020.01.024>
7. Gardner, W. J. (1948). Unilateral exophthalmos due to cerebellar tumor and orbital defect. *Journal of Neurosurgery*, 5(5), 500–502. <https://doi.org/10.3171/jns.1948.5.5.0500>
8. Huang, R. S., Spence, A. R., & Abenhaim, H. A. (2024). Non-Obstetric Maternal Mortality Trends by Race in the United States. *Maternal and Child Health Journal*, 28(5), 895–904. <https://doi.org/10.1007/s10995-023-03862-7>
9. Kazemi, P., Villar, G., & Flexman, A. M. (2014). Anesthetic management of neurosurgical procedures during pregnancy: A case series. *Journal of Neurosurgical Anesthesiology*, 26(3), 234–240. <https://doi.org/10.1097/ANA.0000000000000029>
10. Manfrè, L., Nicoletti, G., Lombardo, M., Consoli, V., Pero, G., & Albanese, V. (1993). Orbital “blow-in” fracture: MRI. *Neuroradiology*, 35(8), 612–613. <https://doi.org/10.1007/BF00588407>
11. McClelland, S. H., Bogod, D. G., & Hardman, J. G. (2008). Apnoea in pregnancy: An investigation using physiological modelling. *Anaesthesia*, 63(3), 264–269. <https://doi.org/10.1111/j.1365-2044.2007.05347.x>
12. Petrone, P., Jiménez-Morillas, P., Axelrad, A., & Marini, C. P. (2019). Traumatic injuries to the pregnant patient: A critical literature review. *European Journal of Trauma and Emergency Surgery: Official Publication of the European Trauma Society*, 45(3), 383–392. <https://doi.org/10.1007/s00068-017-0839-x>
13. Wei, L. A., Kennedy, T. A., Paul, S., Wells, T. S., Griepentrog, G. J., & Lucarelli, M. J. (2016). Traumatic orbital encephalocele: Presentation and imaging. *Orbit (Amsterdam, Netherlands)*, 35(2), 72–77. <https://doi.org/10.3109/01676830.2015.1122816>