

## The Buschke-Lowenstein Tumour and Review of Literature

S. Sylla<sup>1\*</sup>, OE Atiqui<sup>1</sup>, C.E. Fifatin<sup>1</sup>, Y Lamalla<sup>1</sup>, O Oudrhiri<sup>1</sup>, S. Boukind<sup>1</sup>, MD Amrani<sup>1</sup>, and Y. Benchamkha<sup>1</sup>

<sup>1</sup>CHU Mohammed VI Marrakech Plastic and Burn Surgery Service

DOI: <https://doi.org/10.36347/sasjs.2025.v11i05.029>

| Received: 08.04.2025 | Accepted: 16.05.2025 | Published: 24.05.2025

\*Corresponding author: S. Sylla

CHU Mohammed VI Marrakech Plastic and Burn Surgery Service

### Abstract

### Case Report

Buschke-Löwenstein tumour (TBL), or giant acuminated condyloma, is a sexually transmitted infection caused primarily by human papillomavirus (HPV) types 6 and 11. It develops after acuminated condylomas and is distinguished by marked proliferation, deep growth, and potential for recurrence despite a benign histology. Its location is often genital, with frequent involvement of the penis in men and vulva in women, as well as anorectal cases. We presented three cases of BBT with genital, perineal and intergluteal localization, whose surgical sequelae were simple, without recurrence observed after one year of follow-up. The disease progresses slowly and can lead to serious complications such as infections, fistulas or necrosis. The diagnosis is based on an anatomopathological examination, which reveals epithelial hyperplasia without invasion of the basal membrane, sometimes associated with koilocytes. The main treatment is surgical, often wide and sometimes mutilating to avoid relapses. Local treatments (laser, cryotherapy) and medical approaches such as chemotherapy or immunotherapy are sometimes used but their effectiveness remains limited. Radiotherapy and chemotherapy are reserved for inoperable or recurrent cases. Multidisciplinary management and long-term monitoring are essential to prevent recurrence.

**Keywords:** Buschke-Löwenstein tumour, Giant acuminated condyloma, HPV 6/11, Surgical treatment, Genital/Anorectal.

Copyright © 2025 The Author(s): This is an open-access article distributed under the terms of the Creative Commons Attribution 4.0 International License (CC BY-NC 4.0) which permits unrestricted use, distribution, and reproduction in any medium for non-commercial use provided the original author and source are credited.

## I. INTRODUCTION

Buschke-Löwenstein's tumour, or giant acuminated condyloma, is a sexually transmitted infection caused by the human papillomavirus (HPV), most commonly type 6 and/or 11. Rare, it always appears after condylomata acuminata. Although histological analysis of the tumour reveals a benign appearance, its clinical appearance may suggest a more aggressive character.

It is distinguished from condylomata acuminata by its more marked proliferation and deep penetration into underlying tissues which can then be repressed, and squamous cell carcinoma by the absence of histological invasion (respect of the basal membrane) [1].

This epithelial tumour, whose relationship with warty carcinoma remains uncertain, mainly affects men and is characterized by deep growth, potential for malignant degeneration and a strong tendency to recur after treatment [2].

The treatment of choice is surgery, often complemented by other methods such as laser therapy or antiviral treatments to reduce the risk of recurrence.

Careful post-treatment monitoring is essential because of its relapse.

We present 3 cases of the Buschke-Lowenstein tumor.

## II-CASE REPORTS

### Observation #1:

Patient 58 years old, married, with a history of syphilis treated with notion of sexual impotence, without notion of multiple partners or homosexuality

Presents for a mass sprouting vegetative extended at the level of the penis, the scrotum, pubis and anal progressive installation evolving since 04 years

The examination at admission, found a cauliflower tumor with lesions budding, ulcerated and vegetative localizing at the level of the hēmi scrotum right, the penis, pubis measuring 11cm\*8cm and in anal perium. The rest of the review is unremarkable.

The screening for sexually transmitted infections (STIs) (TPHA, VDRL, chlamydia serology, hepatitis, HIV) is negative.

The partner was referred to a gynecological clinic for comprehensive screening, including condylomatous lesions and other sexually transmitted infections (STIs). The results of this screening were negative, indicating no abnormalities or associated infections.

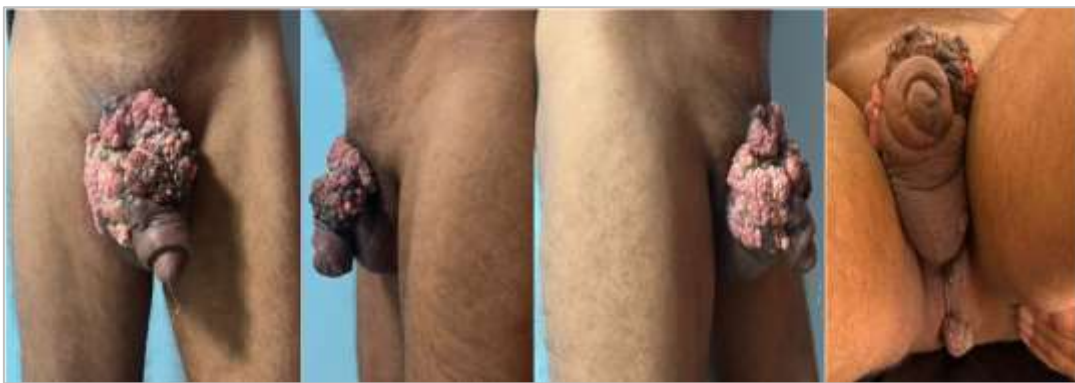Pelvic MRI: Cutaneous tumour process infiltrating the cell-fatty space and coming into contact with the corpora cavernosa with respect to the adipose interface of separation. It also includes the left deep dorsal vein which remains permeable.

A total excision of the tumour taking the skin of the pubic, the penis to the superficial fascia and the right scrotum whose tumor invaded the vaginal then shaving

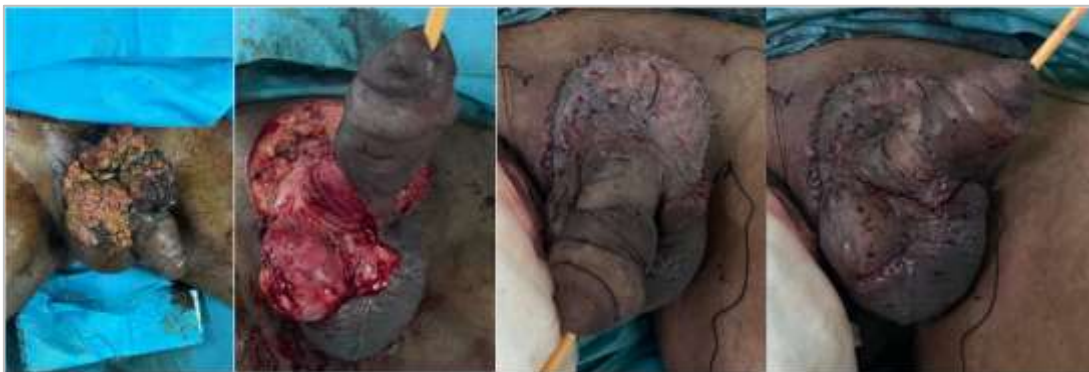small condylomes at the perineal level with coverage by a skin graft mine. The surgical follow-up was simple.

Histologically: we observe an acanthosis epidermis, papillomatous, with orthokeratosis and parakeratosis, as well as the presence of koilocyte and dyskeratotic cells, accompanied by some mitosis. The epithelial architecture is relatively preserved, with regular basal cells. The underlying dermis shows edema, congestion and a discrete perivascular lymphocyte infiltrate. These findings confirm the diagnosis of Buschke-Löwenstein tumour.

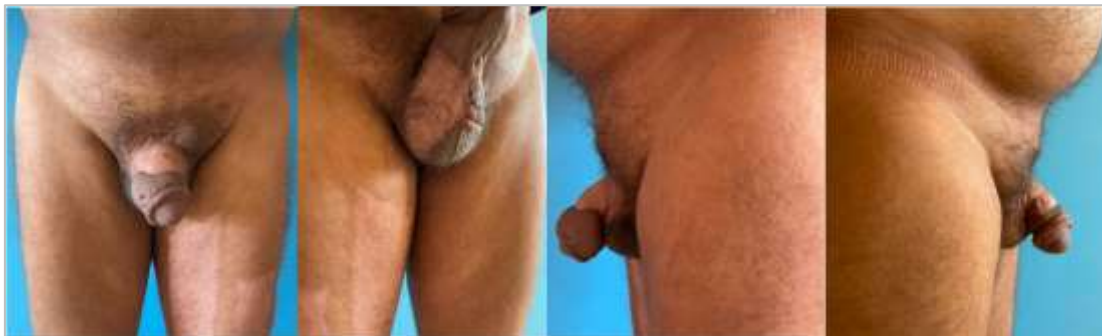The evolution, with a 1 year delay, shows no signs of tumor recurrence. The patient has returned to normal sexual activity and is clearly satisfied with the results.



**Figure 1: Buschke-Löwenstein tumor aspect with pubopenous and scrotal localization (pre-operative).**



**Figure 2: Tumour exeresis with thin skin graft coverage (per-operative)**



**Figure 3: Follow-up of 1 year post-operative evolution**

**Observation #2:**

Patient aged 56, married, no multiple partners, no known history.

Presents for a vegetative budding mass at the hypogastric and perineal level evolving for 12 years.

Upon admission, clinical examination revealed the presence of a cauliflower tumor characterized by budding and vegetative lesions. These lesions were located at the hypogastric, penile and bilateral scrotal region. The tumor had a seepage aspect, with dimensions measured at 17 cm x 11 cm at the hypogastric and 7 cm x 3 cm at the scrotal. The rest of the review is unremarkable.

**Negative serologies**

The partner was referred to gynecology for a full screening, which was negative, with no abnormalities or infection detected.

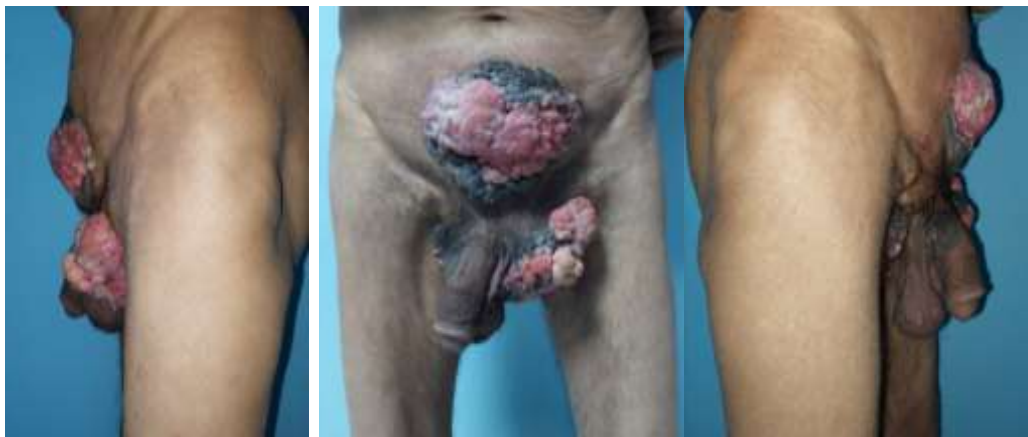CT pelvic abdomino: Cutaneous lesion process of the hypogastric region without deep extension.

Skin and subcutaneous lesion process of the inguino-scrotal region left a perineal extension having contact with the muscle plane and the underlying spermatic cord,

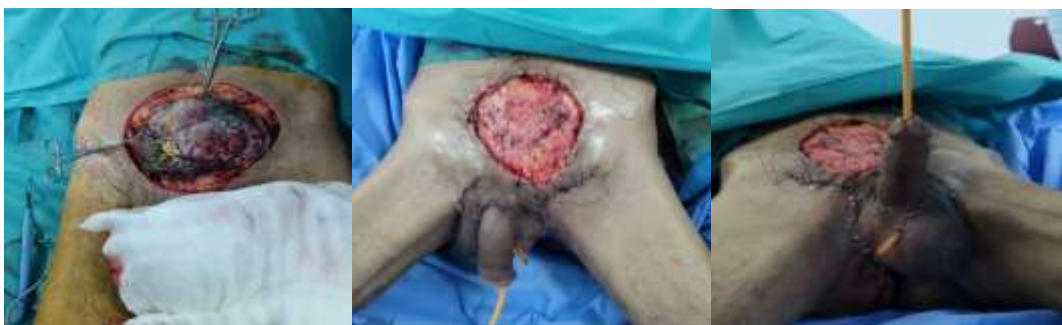A total excision of the tumor was performed, including hypogastric, penile and bilateral scrotal lesions, followed by a direct suture at the scrotal level and a thin skin graft performed in the second operating time at the hypogastric. The surgical follow-up was simple.

Histologically, epithelium acanthosis, papillomatous, parakeratosis hyperkeratosis, koilocytic cells, dyskeratosis, numerous mitoses. Preserved basal membrane. Edematous, congestive dermis, lymphocyte infiltrates and melanic deposits. Evokes a Buschke-Löwenstein tumour.

The evolution with a two-year hindsight did not show any tumour recurrence.



**Figure 1: Buschke-Löwenstein tumor aspect with pubopeneous and scrotal localization ( pre-operative).**



**Figure 2: Tumoral exeresis with direct suture at the scrotal level (per-operative)**

**Observation #3:**

Patient aged 54, married, with primary syphilis history (TPHA+) treated on penitard

Presents for interfessial, fessial and pubic lesions evolving since 02 years,

The examination, at admission, found a papulomatous and itchy vegetative budding lesions located at the buttock, interfesium and anal level measuring 7 cm x 13 cm, postero internal face of the left thigh and pubic.

The rest of the review is unremarkable.

**Negative serologies**

The partner was referred to gynecology for a screening, negative results, no abnormality detected.

Pelvic CT: Irregular skin thickening of the buttock region with anterior extension to the external orifice of the anal canal.

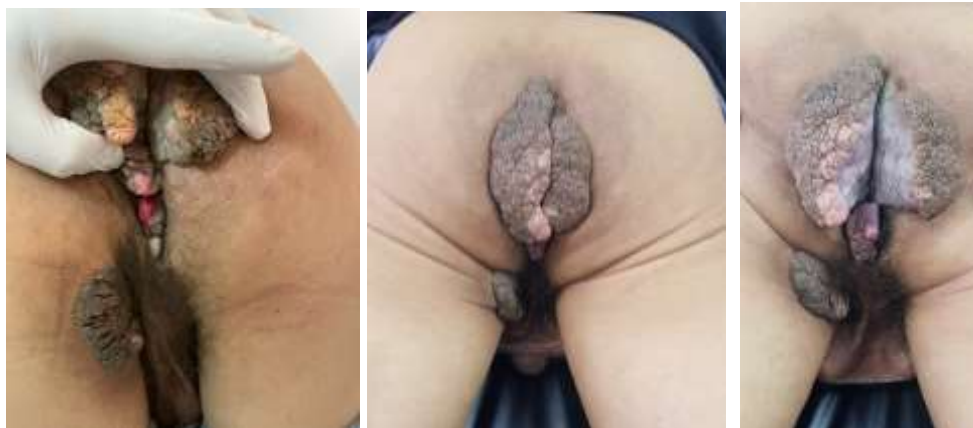
At the colonoscopy, no papillomatous lesions especially in the anal canal.

Colostomy done before the gesture.

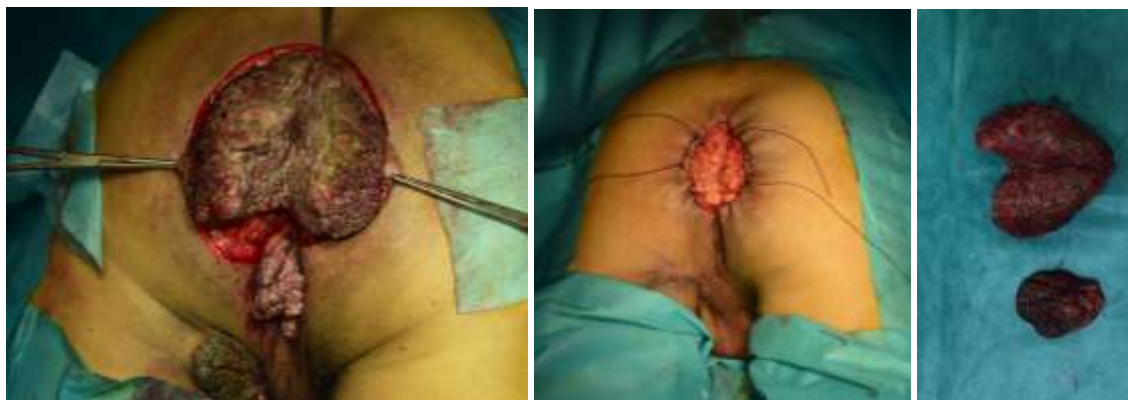A total excision of the tumor taking the lesion from the buttock area, and anal then shaving small condylomes at the level of the thigh and subsequent coverage. The surgical follow-up was simple.

Histologically, exophytic epithelial proliferation with marked papillary projections, with superficial hyperkeratosis and parakeratosis. Many koilocyte cells in the epithelium. In favour of a Buschke-Löwenstein tumour.


With a two-year hindsight, no tumour recurrence was observed. The patient expresses complete satisfaction with the observed results



**Figure 1: Buschke-Löwenstein tumor aspect with anal and interfesional localization (pre-operative).**



**Figure 2 : Exerese tumorale (per-operatoire)**



**Figure 3: Follow-up of 1 year post-operative evolution**

### III. DISCUSSIONS

The Buschke-lowensteinou giant acuminate condyloma was first described in 1896. It was in 1925 that Buschke and Löwenstein made it a characterized entity [3]. It occurs at any age after puberty and predominates between the 4th and 6th decades [4].

In the series of Safi *et al.* as well as in that of Njoumi *et al.*, the average age was 44 years [3, 5].

The mean age of our study patients is 56, and the advanced age of our patients could be explained by a delay in consultation. Indeed, due to its genital localization, the subjects generally have the modesty to go consult with this added lack of resources and ignorance of the disease. A delay in consultation could explain the advanced age of our patients in our series. BL is an essentially male pathology [5], *Idem* in our context.

The literature generally attributes the etiology of this disease to human papillomavirus (HPV), mainly to types 6 and 11, known for their low oncogenic potential but their strong tropism for the cutaneous and mucosal epithelium. However, rare cases with negative infectious scores (especially for HPV) raise important diagnostic and pathogenic issues.

A virological study was not performed as part of our series.

The BBT is most often located at the level of the external genitalia and mainly at the level of the penis. Anorectal localization remains less common but it is not rare. This localization is found in both sexes with a male predominance [6, 7], as was the case in our series. In men, BLT is located in 81 to 94% of the cases in the penis and in 10 to 17% of the cases in the ano-rectal region. In women, the localization is essentially vulvar in 90% of cases, unlike the anorectal localization which remains less frequent [8]. In our series the localization at the level of the external genitals is constant with a case of reaching the anal margin.

Depending on the location, the extension assessment may include, in addition to ganglion palpation, a rectoscopy, gynecological examination, pelvic computed tomography or nuclear magnetic resonance imaging [9].

Women would tend to consult in gynecology or dermatology. Papillomavirus HPV 6 and 11 are implicated in the genesis of TBL [10], the virological study of HPV was not done in our series.

On the anatomo-pathological level, TBL is a perfectly limited malpighian tumour, characterized by considerable epithelial hyperplasia sometimes pseudo-epitheliomatous whose basal membrane is still intact, hyperacantosis, hyperpapillomatosis and koilocytes

which are pathognomonic markers of HPV infection, however their presence is not constant [8, 11].

The course is slow, it can be burdened with several complications including dermatitis, infection, fistulization of nearby organs, necrosis, anal stenosis and hemorrhage [4, 12]. The search for other sexually transmitted infections is systematic (HIV, chlamydia trachomatis, syphilis) in the literature, similar in our context and no cases of association with HIV have been reported. Only one patient had previously contracted a syphilitic infection and treated it.

The treatment of TBL is often difficult, even if histology confirms that it is benign [13]. Surgery remains the treatment of choice for most authors [4, 14]. It must be broad enough or even mutilating to rule out the spectre of recurrence and hope for a definitive cure.

In perianal locations, a resection with preservation of the sphincter and reconstruction is carried out as often as possible, but more severe interventions such as rectal amputation or abdominoperineal amputations are sometimes necessary [14]. The complete nature of the surgical removal of the PBT must be confirmed by anatomopathological examination of the operating room. If the surgical removal is incomplete, surgical recovery is indicated [15].

Patients with extensive lesions with multiple fistula pathways and/or superinfection may require a temporary discharge colostomy [16].

In our context, all patients underwent tumor resection followed by thin skin grafting. The surgical follow-up was simple, with no recurrence observed in the two years following the intervention.

Local treatments such as podophyllin, 5-FU, electrocoagulation, cryotherapy and laser destruction, commonly used for common condylomas, are ineffective in the management of BL [4, 13, 14, 17].

The major disadvantage of these methods is that they do not provide tissue for histological analysis [15, 17].

Methotrexate or bleomycin-based chemotherapy may be considered, but its effectiveness remains limited. It is mainly indicated in preoperative surgery to reduce tumor volume and make the surgical procedure less aggressive [18].

The use of radiation therapy is controversial [13, 15]. It is used preoperatively to reduce tumor mass or as a last resort for inoperable tumors [14, 17]. For some authors, The combination of radiotherapy and neoadjuvant chemotherapy could yield remarkable results; it has been used successfully to treat degenerate

BLT [12, 16]. For some, chemotherapy and radiation should be used only in cases of non-resectable or recurrent TBL because their effectiveness is not well documented [19].

Autoimmunization immunotherapy appears to be effective in treating old and recurrent condyloma(18)

#### IV. CONCLUSION

TBL is an epithelial condylomatous proliferation of viral origin, the evolution of which remains uncertain. Its prevention is essential, based on the treatment of condylomata acuminata and control of sexually transmitted infections. Early treatment is crucial, mainly surgical, involving extensive excision. Rigorous and prolonged postoperative clinical and histological monitoring is necessary, taking into account the potential for degeneration of relapses.

#### BIOBIOGRAPHY

- Njoumi N, Tarchouli M, Ratbi MB, Elochi MR, Yamoul R, Hachi H, *et al.* The anorectal Buschke-Lowenstein tumor: about 16 cases and literature review. *Pan Afr Med J.* 8 Dec 2013;16:131.
- Amrani FE, Hassam B. La tumeur de Buschke-Löwenstein. *Pan Afr Med J* [Internet]. 2013 [cited 8 Oct 2024];14. Available at: <http://www.panafrican-med-journal.com/content/article/14/94/full/>
- Njoumi N, Tarchouli M, Ratbi MB, Elochi MR, Yamoul R, Hachi H, *et al.* The anorectal Buschke-Lowenstein tumor: about 16 cases and literature review. *Pan Afr Med J.* 8 Dec 2013;16:131.
- Qarro A, Ait Ali A, Choho A, Alkandry S, Borki. K. Buschke-Lowenstein tumor with anorectal localization. *Ann Chir.* Feb 2005;130(2):96-100.
- Safi F, Bekdache O, Al-Salam S, Alashari M, Mazen T, El-Salhat H. Management of peri-anal giant condyloma acuminatum—A case report and literature review. *Asian J Surg.* Jan 2013;36(1):43-52.
- [Buschke-Löwenstein tumor] - PubMed [Internet]. [cited 11 Jan 2025]. Available at: <https://pubmed.ncbi.nlm.nih.gov/15746622/>
- 52-13.pdf [Internet]. [cité 8 oct 2024]. Available at: <https://toubkal.imist.ma/bitstream/handle/123456789/22723/52-13.pdf?sequence=1>
- Cherkaoui A, Araki A, Aboutaieb R, Meziane F. Giant acuminate condyloma - Buschke Lowenstein tumour (about 3 cases). *Prog En Urol.* 2003;
- P G, O V, B R, M DLB. [Buschke-Löwenstein tumor]. *Ann Dermatol Venereol* [Internet]. jan 2005 [cited 11 jan 2025];132(1). Available at: <https://pubmed.ncbi.nlm.nih.gov/15746622/>
- Braga JCT, Nadal SR, Stiepcich M, Framil VM de S, Muller H. Buschke -Loewenstein tumor: identification of HPV type 6 and 11. *An Bras Dermatol.* 2012;87(1):131-4.
- Li ALK, Walsh S, McKay DR. Surgical management of a giant condyloma of Buschke-Löwenstein in a patient with Netherton syndrome using the pedicled anterolateral thigh flap--a case report. *J Plast Reconstr Aesthetic Surg JPRAS.* nov 2011;64(11):1533-6.
- Tytherleigh MG, Birtle AJ, Cohen CE, Glynne-Jones R, Livingstone J, Gilbert J. Combined surgery and chemoradiation as a treatment for the Buschke-Löwenstein tumour. *Surg J R Coll Surg Edinb Irel.* Dec 2006;4(6):378-83.
- Kasmaoui E, Lezrak M, Ameur A, Jira H, Beddouch A, Abbar M. About four observations. *Ann Urol.* 1 Jan 2002;36(3):211-6.
- Lévy A, Lebbe C. Management of Buschke-Löwenstein tumours. *Ann Urol.* June 1, 2006;40(3):175-8.
- Rabii R, Joual A, Bellabidia B, Skalli-Dehbi K, Hafliani M, Bennani S, *et al.* Condylome acuminate scrotal giant: about one case. *Ann Urol.* 1 Jan 2001;35(1):67-70.
- Chao MWT, Gibbs P. Squamous cell carcinoma arising in a giant condyloma acuminatum (Buschke-Lowenstein tumour). *Asian J Surg.* Jul 2005;28(3):238-40.
- Ali Sbai M, Balti W, Dhahak S, Ben Romdhane S, Tabib M, Balti H. Buschke Lowenstein tumor: unusual bilateral localization. *Tunis Med.* sept 2009;87(9):627-9.
- Cherkaoui A, Araki A, Aboutaieb R, Meziane F. Giant acuminate condyloma - Buschke Lowenstein tumour (about 3 cases). *Prog En Urol.* 2003;
- Tan XJ, Wu M, Lang JH. Giant condyloma acuminatum of the vulva. *Int J Infect Dis IJID Off Publ Int Soc Infect Dis.* mai 2010;14(5):e455-456.