

## Advanced Malignant Skin Tumors of the Face: Surgical Management and Outcomes in 30 Cases

Dr. Y. Lamaalla<sup>1\*</sup>, Dr. Z. Alami<sup>1</sup>, Dr. Idelkheir<sup>1</sup>, Dr. Azzouzi<sup>1</sup>, Dr. Sylla<sup>1</sup>, Dr. Oudghiri<sup>1</sup>, Pr. El Atiqi<sup>1</sup>, Pr. MD. Elamrani<sup>1</sup>, Pr. Y. Benchamkha<sup>1</sup>

<sup>1</sup>Department of Plastic and Reconstructive Surgery, Mohammed VI University Hospital, Marrakech, Morocco

DOI: <https://doi.org/10.36347/sjmcr.2025.v13i06.045>

| Received: 24.04.2025 | Accepted: 01.06.2025 | Published: 19.06.2025

\*Corresponding author: Dr. Y. Lamaalla

Department of Plastic and Reconstructive Surgery, Mohammed VI University Hospital, Marrakech, Morocco

### Abstract

### Original Research Article

Advanced malignant skin tumors of the face represent a significant clinical and public health challenge due to their high prevalence, potential for disfigurement, and life-threatening complications. This retrospective study analyzed 30 cases treated surgically over two years at a tertiary care center in Morocco. The mean patient age was 63 years, with a male predominance (sex ratio 2:1). Delayed consultation (average 15 months) was attributed to rural healthcare barriers and use of traditional medicine. Histopathological analysis revealed basal cell carcinoma (60%), squamous cell carcinoma (37%), and melanoma (3%). Surgical management included wide local excision (73% curative intent), lymphadenectomy (33% for squamous cell carcinoma), and reconstruction with grafts (20%) or locoregional flaps (80%). The discussion highlights the epidemiological and therapeutic challenges unique to phototypes IV–V populations and underscores the need for early diagnosis and multidisciplinary care.

**Keywords:** Facial skin cancer, advanced tumors, surgical management, epidemiology, reconstruction.

Copyright © 2025 The Author(s): This is an open-access article distributed under the terms of the Creative Commons Attribution 4.0 International License (CC BY-NC 4.0) which permits unrestricted use, distribution, and reproduction in any medium for non-commercial use provided the original author and source are credited.

## INTRODUCTION

Cutaneous malignancies of the face are among the most frequently encountered pathologies in dermatologic and plastic surgery practice, particularly in regions with high ultraviolet (UV) radiation exposure [1]. In Morocco, skin cancers rank as the eighth and tenth most common malignancies in men and women, respectively, with basal cell carcinoma (BCC) constituting 61% of cases [19]. Advanced-stage tumors, defined by deep invasion, nodal metastasis, or destruction of critical facial structures, present formidable therapeutic challenges due to their aesthetic, functional, and prognostic implications [1].

The management of advanced facial skin tumors necessitates a balance between oncologic radicality and functional reconstruction. Surgical resection remains the cornerstone of treatment, yet the anatomical complexity of the face often complicates margin assessment and reconstruction planning [7]. In Morocco, delayed diagnosis—driven by socioeconomic barriers and reliance on traditional medicine—further exacerbates the prevalence of advanced cases [33]. This study aims to analyze the clinical characteristics, histopathological findings, and surgical outcomes of

advanced facial skin tumors in a Moroccan cohort, providing insights into region-specific challenges and therapeutic strategies.

## MATERIALS AND METHODS

### Study Design and Population

A retrospective analysis was conducted on 30 patients treated at Mohammed VI University Hospital between 2019 and 2021. The study was approved by the institutional ethics committee, and data were anonymized to ensure patient confidentiality.

### Inclusion and Exclusion Criteria

Patients were included if they had histologically confirmed malignant tumors (BCC, squamous cell carcinoma [SCC], or mucinous carcinoma) with advanced local invasion (e.g., bone, orbital involvement, or nodal metastasis). Exclusion criteria comprised benign lesions, early-stage tumors, and malignancies confined to the scalp.

### Surgical Protocol

- Oncologic Resection:** Wide local excision was performed with safety margins tailored to tumor type (5 mm for BCC, 10 mm for SCC) [29]. Margins

were marked preoperatively and confirmed via intraoperative frozen sections when feasible.

2. **Reconstruction:** Immediate reconstruction (20% of cases) utilized full-thickness skin grafts for small defects. Larger defects required delayed reconstruction (80%) with locoregional flaps (e.g., Mustardé flap for periorbital defects, deltopectoral flap for cervicofacial involvement).
3. **Lymphadenectomy:** Indicated for SCC with clinically positive nodes (33% of SCC cases).

#### Data Collection

Demographic (age, gender), clinical (consultation delay, macroscopic features), and

histopathological data were extracted from medical records. Therapeutic outcomes, including margin status and recurrence, were analyzed.

## RESULTS

### Demographics

The mean patient age was 63 years (range: 7–89), with 67% of cases occurring in patients aged 60–80. A male predominance was observed (67%, sex ratio 2:1).

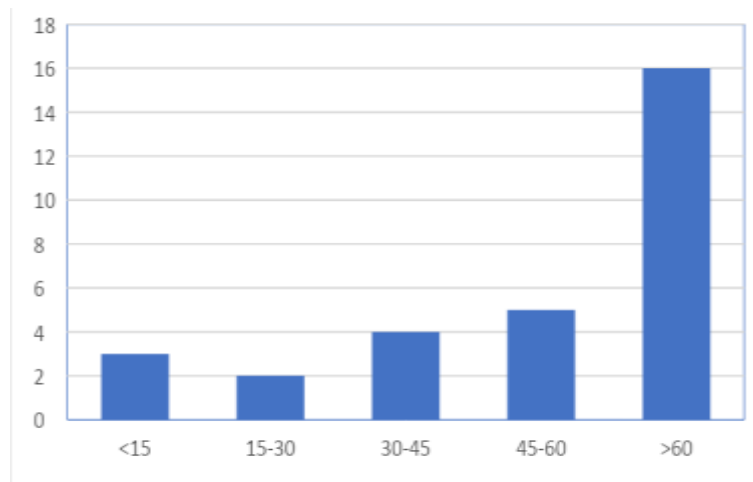


Figure 1: age of patients

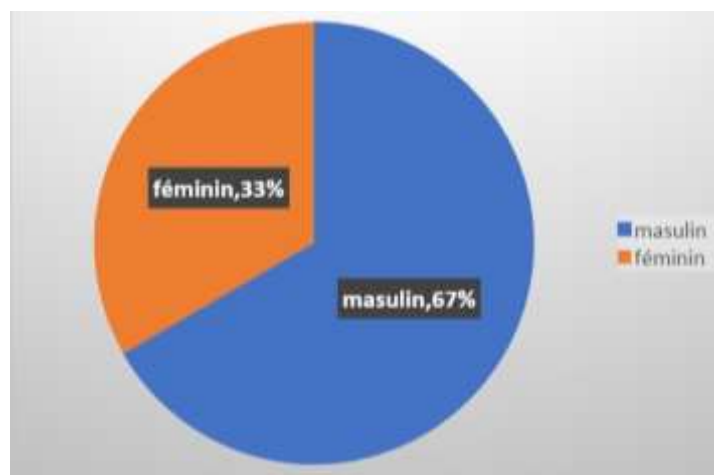


Figure 2: gender of patients

### Clinical Presentation

The average delay to consultation was 15 months (range: 6–24 months). Rural residence (87%) and prior use of traditional medicine (20%) were significant contributors to delayed presentation. Macroscopically, tumors were ulcero-proliferative (56%), nodular (20%), ulcerated (14%), or proliferative (8%).

### Histopathological Findings

BCC accounted for 60% of cases, followed by SCC (37%) and melanoma (3%).

### Therapeutic Outcomes

- **Surgical Resection:** Clear margins were achieved in 77% of cases; 23% required re-excision.

- **Reconstruction:** Immediate reconstruction was performed in 20% of cases, while 80% underwent delayed procedures using locoregional flaps.

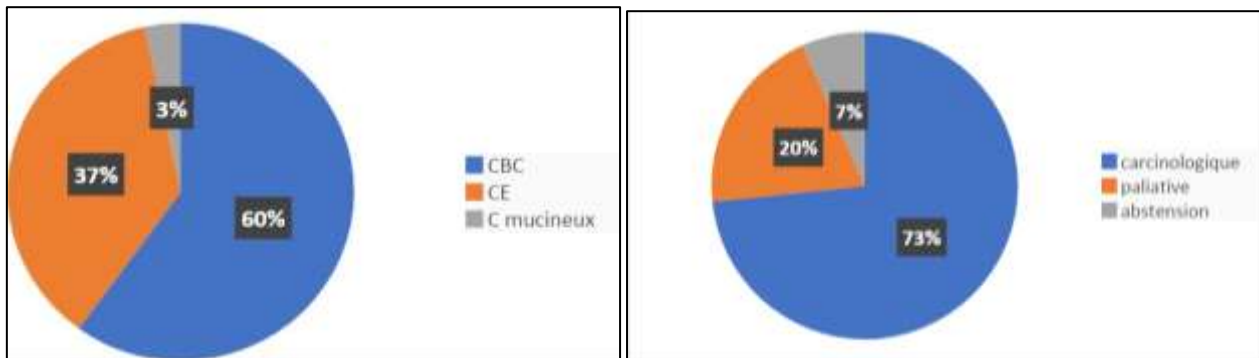


Figure 3: histological type and therapeutic

- **Adjuvant Therapy:** Radiotherapy was administered to 60% of patients with high-risk features (perineural invasion, close margins).

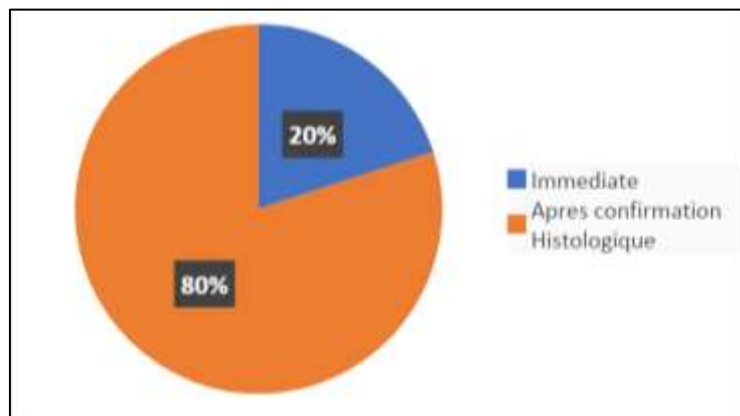


Figure 4: delay before reconstruction

## DISCUSSION

### Epidemiological and Clinical Insights

The male predominance (2:1 ratio) aligns with global trends in UV-exposed populations, where occupational sun exposure is more common among men [34]. The high prevalence of phototypes IV–V (88%) in our cohort contrasts with Caucasian-majority studies, underscoring the need for region-specific prevention strategies [35].

### Risk Factors and Diagnostic Delays

Chronic UV exposure and smoking (linked to BCC in women [41]) were key risk factors. The protracted consultation delay (15 months) reflects systemic barriers, including rural healthcare inaccessibility and cultural reliance on traditional medicine [33].

### Surgical Challenges

The face's anatomical complexity necessitates meticulous resection and reconstruction. The 23% re-

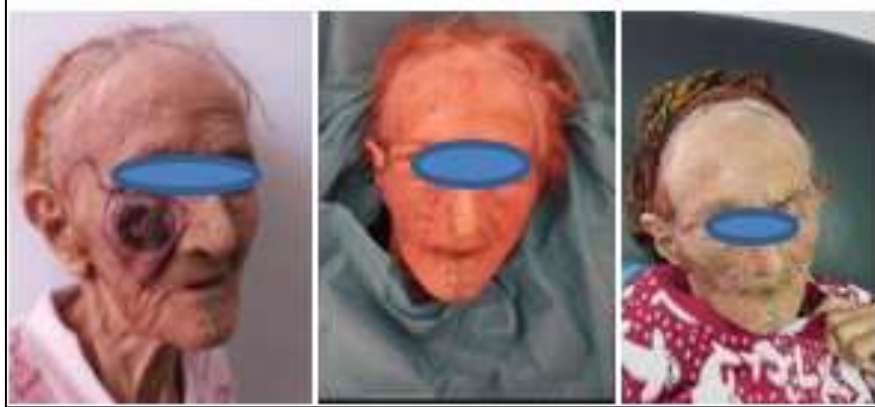excision rate highlights the difficulty of achieving clear margins in advanced tumors [29]. Locoregional flaps, such as the deltopectoral flap, provided reliable coverage for large defects, though aesthetic outcomes require further long-term evaluation.

### Comparative Analysis

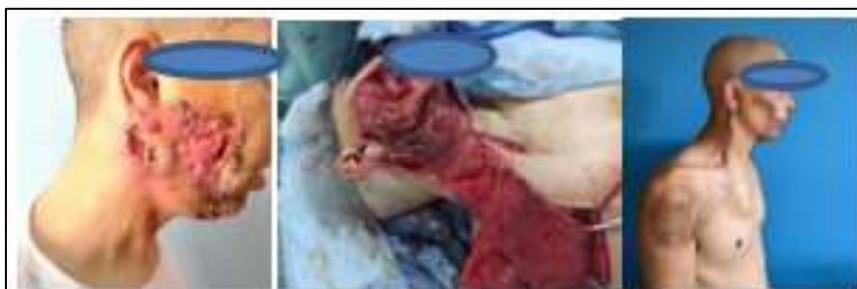The predominance of BCC (60%) mirrors global data, while the higher SCC incidence (37% vs. 20% in Western cohorts) may reflect differences in photoprotective behaviors [19, 35].

### Recommendations

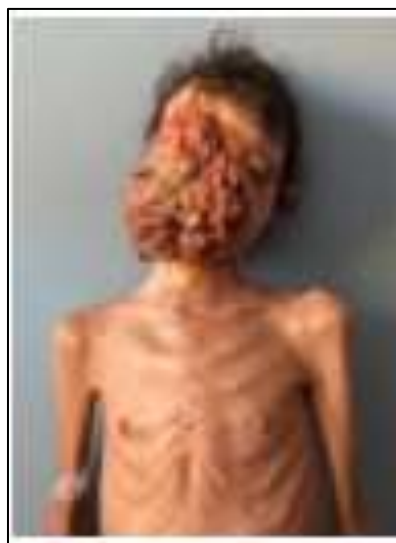1. **Early Detection Programs:** Community-based screening to reduce advanced-stage presentations.
2. **Multidisciplinary Care:** Collaboration between dermatologists, oncologists, and reconstructive surgeons.
3. **Public Health Initiatives:** Education on sun protection and healthcare access in rural areas.



**Figure 5: An 85-year-old patient presented with a C, Epidermoid of the right palpebral jugal region who benefited from a Mustarde flap. Therapeutic**



**Figure 6: Patient aged 43, smoker who consulted for cervico-jugal infiltrating CBC and benefited from a Deltopectoral Flap**



**Figure 7: abstention in a 15-year-old patient with a large ulcerative budding tumor of the right hemiface and limitation of oral opening**

## CONCLUSION

This study underscores surgery as the gold standard for advanced facial skin tumors, with reconstruction playing a pivotal role in functional and aesthetic recovery. The high prevalence of delayed diagnosis in rural populations calls for targeted public health interventions. Future research should explore long-term oncologic and quality-of-life outcomes in phototype IV–V populations.

## REFERENCES

1. CEDEF: collège des enseignants en dermatologie de France.
2. Annales de dermatologie et de vénéréologie (2015) 142S, S201—S224 Item 299—UE 9—Tumeurs cutanées épithéliales et mélaniques.
3. Université Médicale Virtuelle Francophone
4. Anatomie cranio-faciale. <http://umvf.univ-nantes.fr/chirurgie-maxillo-faciale-etstomatologie/>

- enseignement/stomatologie1/site/html/cours.pdf.
5. Y. Saban, R. Polselli, V. Ruvo. Anatomie de la face. Chirurgie réparatrice du visage et du cou, tome 1, chapitre 1, pages 4-15.(2011)
  6. Atlas d'anatomie chirurgicale de la face et du cou, Tome 1 :
  7. Paupières, orbite, voies lacrymale, nez et sinus. Anatomie et fonction des paupières et conjonctives:
  8. Arnaud, M. Bouzebo, V. Huguier, V. Darsonval, P. Rousseau: Couly G. Anatomie Maxillo-Faciale. Paris: Julien Prelat ; 1991. 69:193-7.
  9. Christophe Bonnefoy, Jacques Dichamp, Luc Chikhani. 14. AOS 2013;265:24-32.
  10. Anatomie artistique en prothèse faciale et muscles peauciers de la face et du cou (1ère partie ).
  11. Tutorat des étudiants de santé de Dijon .
  12. UE Spécifique Anatomie tête et cou [https://www.ted21.fr/index.php?option=com\\_phoca\\_download&view=category&download=733:livret-anatomie-specifique&id=49:pre-rentree&Itemid=251](https://www.ted21.fr/index.php?option=com_phoca_download&view=category&download=733:livret-anatomie-specifique&id=49:pre-rentree&Itemid=251).
  13. Kamina P, Renard M. Le corps humain Paris: Maloine, 1994.
  14. [www.lecorpshumain.fr/corps humain/1-muscles-zy](http://www.lecorpshumain.fr/corps humain/1-muscles-zy).
  15. Garnier B, Simon E, Dumont T, Sellal S, Stricker M, Chassagne J-F.
  16. Les carcinomes cutanés basocellulaires méritent-ils leur réputation de tumeurs à faible
  17. malignité ?. Rev Stomatol Chir Maxillofac. 2005; 106(1):16-21.
  18. Basset-Seguin N , Dreno B , Grob JJ . Tumeurs cutanées épithéliales et mélaniques:
  19. Carcinomes épithéliaux . Ann Dermatol Venerol. 2002; 129(10 Suppl):S132-6.
  20. P. Bernard, C. Derancourt, E. Arnoult-Coudoux, R. Picot, C. Delvincourt.
  21. Etude prospective de l'incidence des cancers cutanés dépistés en pratique dermatologique Dans la région
  22. Champagne-Ardenne.
  23. Annales de Dermatologie et de Vénéréologie , Vol 128, N° 8-9 - septembre 2001.
  24. Registre des cancers de la région du grand casablanca 2008-2012.
  25. G. Staub, M. Revol, P. May, .-C. Bayol, O. Verola, J-M. Servant.
  26. Marges d'exérèse chirurgicale et taux de récurrence des carcinomes cutanés . Etude prospective de 844 cas. 2007 Elsevier Masson SAS.
  27. Samarasinghe V, Madan V. Nonmelanoma skin cancer. Journal of Cutaneous and Aesthetic Surgery. 2012;5(1):3.
  28. Ahmad I, Gupta AD. Main Articles Epidemiology of basal cell carcinoma and squamous cell carcinoma of the pinna. The Journal of Laryngology & Otology. 2001;115:85-6.
  29. Mernissi. Tumeurs cutanées malignes colligées au service de dermatologie du CHU Hassan II Sur une Période de 2 ans. Thèse de médecine. 2008.
  30. Bano Traore F . Carcinome basocellulaire sur une zone photo exposée chez une africaine mélanoderme. Annales de dermatologie et de vénéréologie. 2001; vol. 128.
  31. Flavia Regina Ferreira, Luiz Fernando Costa Nascimento, Osmar Rotta. Risk factors for non - melanoma skin cancer in Taubaté, São Paul, Brazil: a case-control study. Elsevier Editora Ltda.
  32. Dumas P , Benatar M , Cardot-Leccia N , Lebreton E , Chignon-Sicard B . Étude de la rétraction cutanée appliquée à la prise en charge des tumeurs cutanées
  33. Cartographie du corps humain. Annales de chirurgie plastique esthétique [Internet]. 2012 [cité 4 mai 2013].
  34. Louis Dubertret. CANCERS CUTANES, p 135-136
  35. Grant W. The effect of solar UVB doses. European journal of cancer. 2008; no. 44
  36. Philippe B . Carcinomes épithéliaux : tumeurs cutanées épithéliales et mélaniques . Annales de dermatologie et de vénéréologie. 2003 ; vol. 130.
  37. Pinatel B , Mojallal A . Prise en charge diagnostique et thérapeutique du carcinome cutané basocellulaire– Analyse des recommandations. Annales de Chirurgie Plastique Esthétique. avr 2012;57(2):92 - 105
  38. Wojno TH. The association between cigarette smoking and basal cell carcinoma of the eyelids in women. Ophthal Plast Reconstruction Surg, 1999;15:390-2.
  39. Feedman DM, Sigurdson A, Doody MM, Mabuchi K, Linet MS. Risk of basal cell carcinoma in relation to alcohol intake and smoking. Cancer Epidemiol Biomarkers Prev 2003;12:1540-3.
  40. L. Ben Slama. Carcinoma of the lips. Rev Stomatol Chir Maxillofac 2009;110:278-283.
  41. Eskizmir G, Baker S, Cingi C. Nonmelanoma Skin Cancer of the Head and Neck. Facial Plastic Surgery Clinics of North America. nov 2012;20(4):493-513.