

## Therapeutic Impact of Iodine-131 in Patients with Toxic Multinodular Goiter: Our Experience

S.E. Abaid<sup>1\*</sup>, H. Alaoui<sup>1</sup>, A. Abdali<sup>1</sup>, M.A Bsis<sup>1</sup>, A. Matrane<sup>1</sup>

<sup>1</sup>Nuclear Medicine Department, Hematology Oncology Centre, Mohammed VI University Hospital, Marrakesh, Morocco

DOI: <https://doi.org/10.36347/sjmcr.2025.v13i08.029>

| Received: 21.05.2025 | Accepted: 27.06.2025 | Published: 16.08.2025

\*Corresponding author: S.E. Abaid

Nuclear Medicine Department, Hematology Oncology Centre, Mohammed VI University Hospital, Marrakesh, Morocco

### Abstract

### Original Research Article

Toxic multinodular goiter is the most common etiology of hyperthyroidism in the elderly. The aim of our work is to illustrate the relevance of iodine therapy and its therapeutic effectiveness on this endocrinopathy. This retrospective study collected data over a period of 9 years, from January 2014 to January 2023, conducted in the nuclear medicine department at CHU Mohamed VI in Marrakech, concerning 43 cases. The collected data includes age, sex, clinical and paraclinical data, and the indication for treatment with iodine therapy in the patients. GMNT typically occurs on pre-existing goiters, with iodine deficiency being one of the main factors for its occurrence. We note a treatment success rate of 87.09%. The administration of iodine-131, which has minimal effects and complications, demonstrated very good effectiveness from the first treatment. Iodine therapy thus establishes itself as a first-line treatment for multinodular goiter, given its low aggressiveness.

**Keywords:** GMNT, Radioactive iodine therapy, Goiter, Hyperthyroidism.

**Copyright © 2025 The Author(s):** This is an open-access article distributed under the terms of the Creative Commons Attribution 4.0 International License (CC BY-NC 4.0) which permits unrestricted use, distribution, and reproduction in any medium for non-commercial use provided the original author and source are credited.

## INTRODUCTION

Toxic multinodular goiter (TMNG) is the most common cause of hyperthyroidism in the elderly, particularly in cases of mild to moderate iodine deficiency. In these patients, hyperthyroidism cannot be definitively cured with antithyroid drugs. Treatment with radioiodine-131 is, in principle, an attractive therapeutic option, as the suppressed extranodular thyroid tissue is partially protected. Its popularity has increased in recent years [1]. Radical treatment with iodine-131 is increasingly becoming the first-line treatment of choice. The therapeutic strategy for administering optimal activities varies from one medical team to another. The treatment with iodine-131 is one of the oldest therapeutic applications in nuclear medicine [2]. The objective is to demonstrate its therapeutic efficacy on this endocrinopathy.

## PATIENTS AND METHODS

This is a retrospective study conducted over a 9-year period, from January 2014 to January 2023, involving 43 cases. It consists of an analysis of medical records of patients followed for toxic multinodular goiter at the Nuclear Medicine Department of Mohamed VI University Hospital in Marrakech.

### In this study, we collected:

- Epidemiological data (age, sex, origin, medical history)
- Clinical data (circumstances of diagnosis)
- Histological data
- Biological data (thyroglobulin, antithyroglobulin antibodies)
- Medical imaging data
- Indication for treatment with radioiodine therapy

### Inclusion criteria for this study were:

All patients followed in the department for toxic multinodular goiter were included.

### Exclusion criteria included:

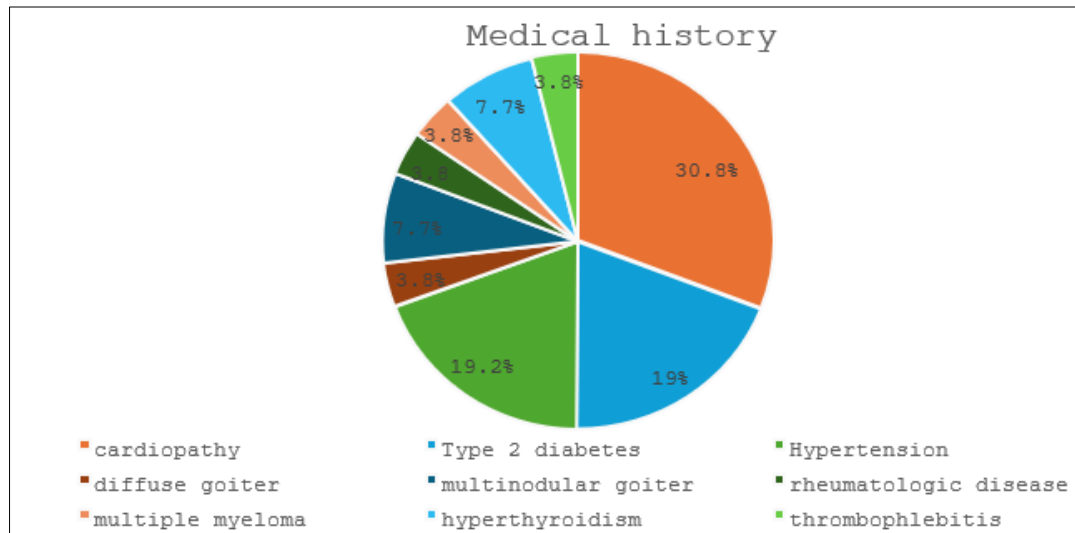
Cases of hyperthyroidism not diagnosed as TMNG; patients whose medical records could not be retrieved; and patients lost to follow-up.

The mean age of our patients was 64 years (range: 60–79), with a clear female predominance (38 women / 5 men), giving a sex ratio of 7.62. A total of 72.1% of patients came from urban areas, compared to 27.9% from rural areas. Regarding medical history, we found that:

- Cardiopathies accounted for 30.8%,

- Type 2 diabetes and hypertension each represented 19.2%,
- Hyperthyroidism and multinodular goiter each accounted for 7.7%,
- Diffuse goiter, multiple myeloma, rheumatologic disease, and thrombophlebitis each represented 3.8%.

The majority of patients had no medical history, but among those who did, cardiopathies appeared to be the most common. Diabetes and hypertension were also frequent conditions in this group (**Fig. 1**).



**Fig. 1: Distribution of medical history**

The clinical signs were varied in our series, dominated by asthenia, thermophobia, weight loss, and in terms of cardiovascular signs by tachycardia and palpitations. Regarding neuropsychic signs, irritability was the predominant symptom, followed by sleep disturbances. For muscular signs, muscle weakness and amyotrophy were frequent symptoms among our patients.

Concerning the presence of goiter, 40 patients presented with a goiter on clinical examination, representing 93.02%. The majority of goiters were of a stony consistency.

For paraclinical data:

Biologically, TSH at the time of diagnosis was suppressed ( $<0.2$   $\mu\text{IU/mL}$ ) in 28 patients, and  $>0.2$   $\mu\text{IU/mL}$  in 15 patients.

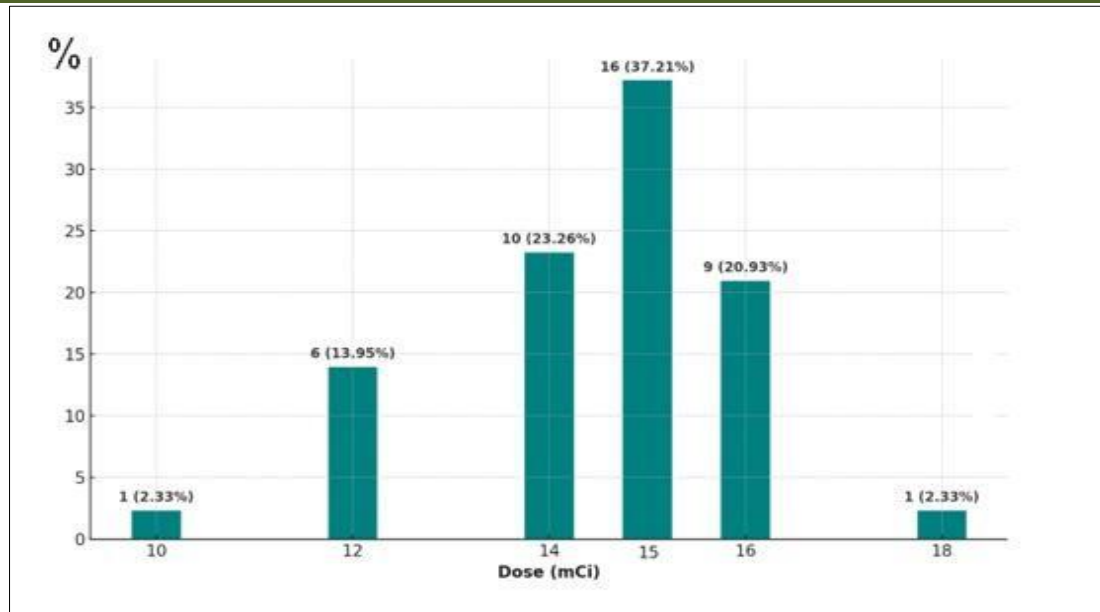
The LT4 assay in the majority of patients showed values around 25 pmol/L, which was the most frequent range in this population.

Immunologically, all patients included in this study had a negative antibody assay.

On ultrasound, a heterogeneous multinodular goiter with EU-TIRADS 2 aspect was the most frequent, representing 50% of patients; a heterogeneous multinodular goiter with EU-TIRADS 3 aspect represented 25% of patients; a multinodular goiter was observed in 5%, a nodular vascular goiter in 7.5%, and 12.5% of the patients in our series had undocumented ultrasounds.

Thyroid scintigraphy demonstrated typical imaging of toxic multinodular goiter in all our patients, characterized by areas of hyperfixation with hypofixation of the surrounding tissues.

Radioiodine therapy was indicated as first-line treatment for almost all patients; 93.02% received a single course of radioiodine therapy, 6.98% received two courses, and no patient received three courses. The administered activity varied between 10 and 18 mCi, with the most frequently administered dose being 15 mCi in 37.21% of patients; 14 mCi in 23.26%; 16 mCi in 20.93%; 12 mCi in 13.95%; and doses of 18 mCi and 10 mCi were each administered to 3.23% of patients. (**Fig.2**)



**Fig. 2: Activities administered during the first treatment cycle.**

Short-term results: Among all patients who received radioactive iodine, no early side effects such as acute thyroiditis or acute thyrotoxic crisis were observed. Long-term results were assessed in terms of the occurrence of hypothyroidism, return to euthyroidism, and persistence or recurrence of hyperthyroidism. Ultimately, treatment success was noted in 87.09% of cases.

## DISCUSSION

Toxic multinodular goiter (TMNG) is a condition with female predominance, secondary to the autonomization of one or more nodules. Hyperthyroidism does not rule out the diagnosis of thyroid cancer; in the presence of a sonographically suspicious nodule, surgical treatment is preferred over other therapeutic options for hyperthyroidism. [3].

A large multinodular goiter may sometimes cause compressive symptoms, and one of its nodules may harbor a cancerous focus. In the presence of compressive symptoms, imaging without iodinated contrast should be used to assess the extent of the goiter, particularly its retrosternal component, and spirometry can help determine the severity of tracheal obstruction. Rarely, in the event of hemorrhage within a large goiter, acute airway obstruction may occur. [4].

Iodine-131 is a radioactive isotope of stable iodine. It is taken up and organified by thyroid cells, which allows for the exploration of thyroid metabolism as a whole. It is a mixed  $\gamma$  and  $\beta^-$  emitter. It is therefore used at low doses for diagnostic purposes, but mainly at high doses for therapeutic indications [5].

In our study, we demonstrated the efficacy and good tolerance of radioisotope therapy with iodine-131 in patients with toxic multinodular goiters.

Radioiodine therapy thus stands out as a first-line treatment for TMNG, as it is minimally invasive, easily administered, and cost-effective. Moreover, it is particularly suitable for elderly patients, for whom surgery and antithyroid drugs (ATDs) carry certain risks. Our results are consistent with data from the literature [6].

However, there is still a dilemma between administering a high ablative dose of iodine, which often leads to hypothyroidism, and administering a lower antithyroid dose, which carries a higher risk of treatment failure, the main predictive factor for treatment failure in toxic multinodular goiter is the goiter volume [7].

Thyroid volume reduction occurs during the first three months following radioiodine Iode131 treatment, followed by a continued volumetric effect of iodine over 24 months. The median thyroid volume decreases, with no observed regrowth of paramodular tissue, indicating that radioiodine therapy affects not only the hyperfunctioning nodules but also the paramodular tissue [8].

The administration of Iodine-131, which has minimal effects and complications, has demonstrated very good efficacy from the first course of treatment [9].

In our study, we observed notable efficacy and good tolerance of radioisotopic treatment with Iodine-131

## CONCLUSION

Toxic multinodular goiters (TMNG) remain common among our patients. Strengthening the promotion of iodized salt in the diet is one of the key strategies to reduce this prevalence, as TMNG generally develops on preexisting goiters, with iodine deficiency being one of the main contributing factors. Radioiodine is a simple, minimally invasive, and low-cost treatment. It can be considered a first-line therapy for nodular hyperthyroidism when there is no anatomical compression or suspicious signs of neoplastic disease. Surgery, however, still has its place in cases of large goiters. Nonetheless, surgery may carry certain complications such as hypoparathyroidism and recurrent laryngeal nerve paralysis. An increase in the indications for radioiodine therapy could help reduce complications related to surgery and improve patients' post-therapeutic comfort.

**Acknowledgements:** The authors wish to thank all colleagues who supported this study.

### Authorship Contributions:

Medical Practices: S.E.A., H.A., A.A., M.A.B., A.M., Concept: H.A., Design: S.E.A., Data Collection or Processing: S.E.A., H.A., A.A., Analysis or Interpretation: S.E.A., H.A., A.A., M.A.B., A.M., Literature Search: S.E.A., Writing: S.E.A.,

**Funding:** This research received no specific grant from any funding agency in the public, commercial or not-for-profit sectors.

### Declaration

#### Conflict of interest:

All the authors (Saad Eddine Abaid, Hamza Alaoui, Ayman Abdali Mohammed Aziz Bsiss, Aboubaker Matrane) declare that there is no conflict of interest that could be perceived as prejudicing the impartiality of the research reported.

**Informed Consent:** Written informed consent was obtained prospectively from the patient to use their clinical data.

## REFERENCES

1. Nygaard, Birte, Laszlo Hegedüs, Peter Ulriksen, Kamilla Gerhard Nielsen, et Jens Mølholm Hansen. « Radioiodine Therapy for Multinodular Toxic Goiter ». *Archives of Internal Medicine* 159, n° 12 (28 juin 1999): 1364. <https://doi.org/10.1001/archinte.159.12.1364>.
2. El Issami, S., F. Sarroukh, M. Elrhoul, H. Guerrouj, I. Ghfir, et N. Ben Rais Aouad. « Traitement de l'hyperthyroïdie par l'iode 131 : à propos de 280 cas ». *Médecine Nucléaire* 35, n° 10 (octobre 2011): 528-32. <https://doi.org/10.1016/j.mednuc.2011.08.001>.
3. Sagna, Y., I. Khaldouni, A.E. Tadmori, M. Rchachi, H. El Ouahabi, et F. Ajdi. « Les goîtres multinodulaires toxiques : aspects épidémio-cliniques, thérapeutiques et évolutifs au CHU Hassan II de Fès (Maroc) ». *Annales d'Endocrinologie* 76, n° 4 (septembre 2015): 448. <https://doi.org/10.1016/j.ando.2015.07.492>.
4. Petite, Christophe, et Christoph A Meier. « Thyroid nodules and goiters: surgical treatment », s. d
5. N. LOUNISSI, D. BEN SELLEM : irathérapie des GMNT.
6. Université de Tunis El Manar 2017
7. D. Ben Sellem et N. Lounissi, « Irathérapie des adénomes toxiques », *Annales d'Endocrinologie* 79, no 4 (septembre 2018): 358, <https://doi.org/10.1016/j.ando.2018.06.508>.
8. Zaabar, L., I. Sakka, M. Yazidi, D. Ben Sallem, F. Chaker, I. Oueslati, et B. Ben Ltaief. « Radioactive iodine treatment in toxic multinodular goiter: prognostic factors ». *Annales d'Endocrinologie* 81, n° 4 (septembre 2020): 340-41. <https://doi.org/10.1016/j.ando.2020.07.560>.
9. Nygaard, Birte, Laszlo Hegedüs, Peter Ulriksen, Kamilla Gerhard Nielsen, et Jens Mølholm Hansen. « Radioiodine Therapy for Multinodular Toxic Goiter ». *Archives of Internal Medicine* 159, n° 12 (28 juin 1999): 1364. <https://doi.org/10.1001/archinte.159.12.1364>.
10. N. Lounissi et D. Ben Sellem, « Irathérapie des goîtres multinodulaires toxiques », *Annales d'Endocrinologie* 78, no 4 (septembre 2017): 341-42, <https://doi.org/10.1016/j.ando.2017.07.407>.