

Optic Disc Melanocytoma: Clinical and Paraclinical Characteristics, and the Value of Multimodal Surveillance - A Case Report

Charaf Bouabbadi^{1*}, Ayoub Bouimtarhan¹, Yasmine Nejjar¹, Yasmine Bensaoud¹, Aissam Fiqhi¹, Adil Elkhouyaali¹, Yassine Mouzari¹

¹Mohammed V Military Teaching Hospital Rabat

DOI: <https://doi.org/10.36347/sjmcr.2025.v13i11.047>

| Received: 21.09.2025 | Accepted: 19.11.2025 | Published: 24.11.2025

*Corresponding author: Charaf Bouabbadi
Mohammed V Military Teaching Hospital Rabat

Abstract

Case Report

A 42-year-old female presented for routine examination. Fundus photography, Fluorescein Angiography (FA), and Optical Coherence Tomography (OCT) were performed to characterize a highly pigmented optic disc lesion. The patient was placed on an active annual surveillance protocol utilizing clinical examination and serial multimodal imaging. A jet-black, dome-shaped lesion on the left optic disc with feathered margins and preserved retinal vessels was documented (Fig. A, B). FA showed typical early hypofluorescence with late-phase filling (Fig. C). OCT confirmed the elevated structure with dense posterior shadowing (Fig. D). Over a two-year follow-up period, the lesion remained absolutely stable in size and morphology (Fig. E), confirming the benign diagnosis of ODM. Optic Disc Melanocytoma is a rare, typically stable tumor that poses a significant diagnostic challenge with choroidal malignant melanoma. While benign, the risk of rare malignant transformation and local vision-threatening complications mandates continuous vigilance. This case underscores the crucial role of active, long-term annual surveillance, particularly utilizing serial OCT and fundus photography, as the definitive and conservative management approach for clinically quiescent ODM.

Keywords: optic disc melanocytoma, optic nerve head tumor, choroidal melanoma, multimodal imaging.

Copyright © 2025 The Author(s): This is an open-access article distributed under the terms of the Creative Commons Attribution 4.0 International License (CC BY-NC 4.0) which permits unrestricted use, distribution, and reproduction in any medium for non-commercial use provided the original author and source are credited.

INTRODUCTION

Optic Disc Melanocytoma (ODM) is a rare, heavily pigmented, and typically benign variant of nevus, originating from the melanocytes of the optic nerve head [1].

Differentiating ODM from life-threatening lesions, particularly choroidal malignant melanoma (MM), constitutes a major diagnostic challenge in ophthalmic oncology, given the profoundly different prognostic and therapeutic implications [2]. Moreover, while usually quiescent, ODM may rarely undergo malignant transformation [3] or be associated with vision-threatening complications.

We report a case of an incidentally discovered ODM. Through multimodal imaging, this case highlights the tumor's characteristic features and underscores the critical need for an active, long-term surveillance strategy to detect rare complications or malignant change [4].

CASE PRESENTATION

A 42-year-old female patient with no notable past medical history presented to our structure for evaluation of presbyopia. Upon initial assessment, best-corrected visual acuity was 10/10 P2 (+1.50) in the right eye (OD) and 10/10 P2 (+1.50) in the left eye (OS). Intraocular pressure (IOP) was bilaterally 18 mmHg. Examination of the anterior segment, pupillary reactions, and ocular motility was unremarkable.

Funduscopy examination of the left eye (OS) revealed a highly pigmented, dome-shaped lesion originating from the optic disc, estimated to be approximately half of the disc diameter (DD) in size. The mass exhibited a characteristic jet-black coloration with feathery margins extending into the adjacent peripapillary area. Importantly, there was no obscuration or distortion of the overlying retinal vessels and no signs of associated subretinal fluid, retinal exudation, or other features concerning for malignancy (Fig. A). The remaining retina was clinically quiescent. The right eye (OD) fundus was entirely normal (Fig. B). Fluorescein angiography revealed an early hypofluorescent lesion

Citation: Charaf Bouabbadi, Ayoub Bouimtarhan, Yasmine Nejjar, Yasmine Bensaoud, Aissam Fiqhi, Adil Elkhouyaali, Yassine Mouzari. Optic Disc Melanocytoma: Clinical and Paraclinical Characteristics, and the Value of Multimodal Surveillance - A Case Report. Sch J Med Case Rep, 2025 Nov 13(11): 2858-2861.

that progressively filled in the late phase (Figure C). Optical coherence tomography (OCT) demonstrated a dome-shaped lesion with a posterior shadow,

characterized by irregular hyperreflective margins and scattered hyperreflective foci (Figure D)

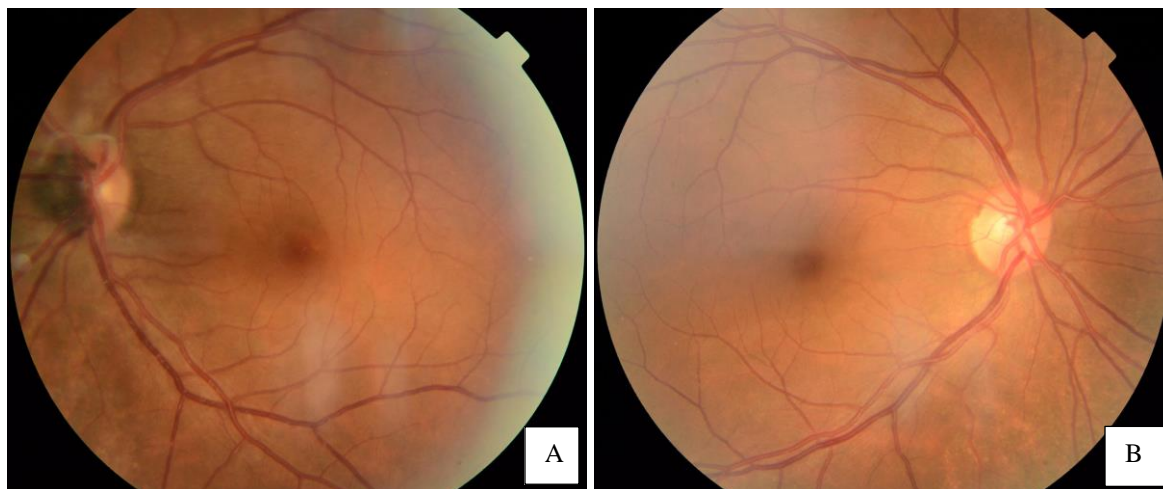


Fig A: Fundus Photograph of the Left Eye (OS): Optic disc melanocytoma appearing as a highly pigmented, round papillary lesion with peripapillary extension and preserved retinal vessel structure.

Fig B: Fundus Photograph of the Right Eye (OD): Normal appearance of the optic disc and retina, used as baseline comparison for the left eye lesion

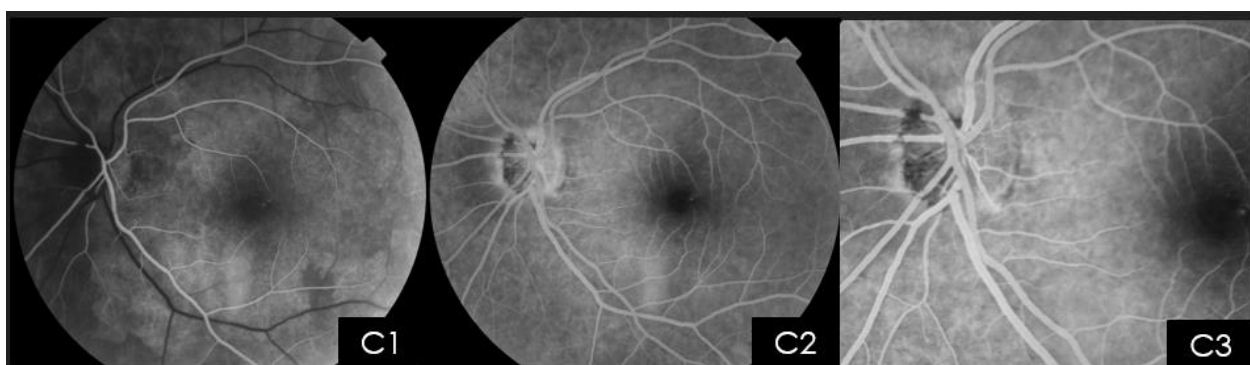


Fig C: Fluorescein Angiography (FA) of the Left Eye (OS): Early phase hypofluorescence (C1) of the optic disc melanocytoma, followed by progressive, late-phase filling (C2-C3) without significant leakage

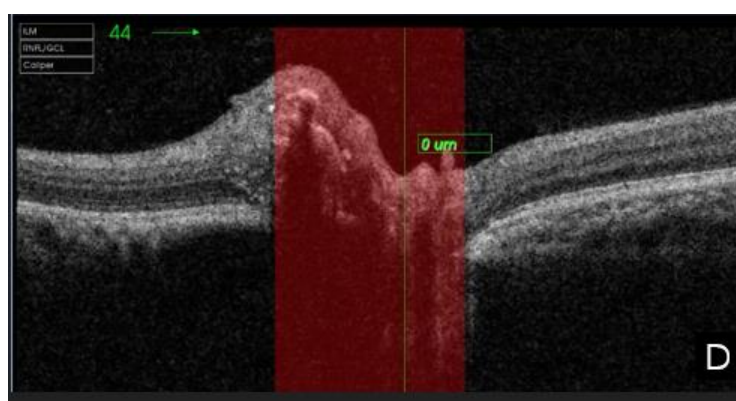

Fig D: Optical Coherence Tomography (OCT) of the Optic Disc Melanocytoma: Demonstration of a dome-shaped lesion characterized by irregular hyperreflective margins and scattered hyperreflective foci, with a large posterior shadowing artifact due to heavy pigmentation

Given the classical benign clinical appearance of an optic disc melanocytoma (ODM) and the absence of high-risk features (TFSOM: Thickness, Fluid, Symptoms, Orange pigment, Margin), a management strategy of active annual surveillance was initiated.

Follow-up included comprehensive clinical examination, serial fundus photography, and Optical Coherence Tomography (OCT) of the optic disc.

Over a two-year observation period (Fig. E), the lesion maintained absolute stability in size and morphology, with no documentation of tumor growth, change in pigmentation, or development of secondary

complications. This sustained clinical stability strongly affirmed the benign diagnosis of ODM and validated the conservative surveillance approach over invasive diagnostic or therapeutic intervention.

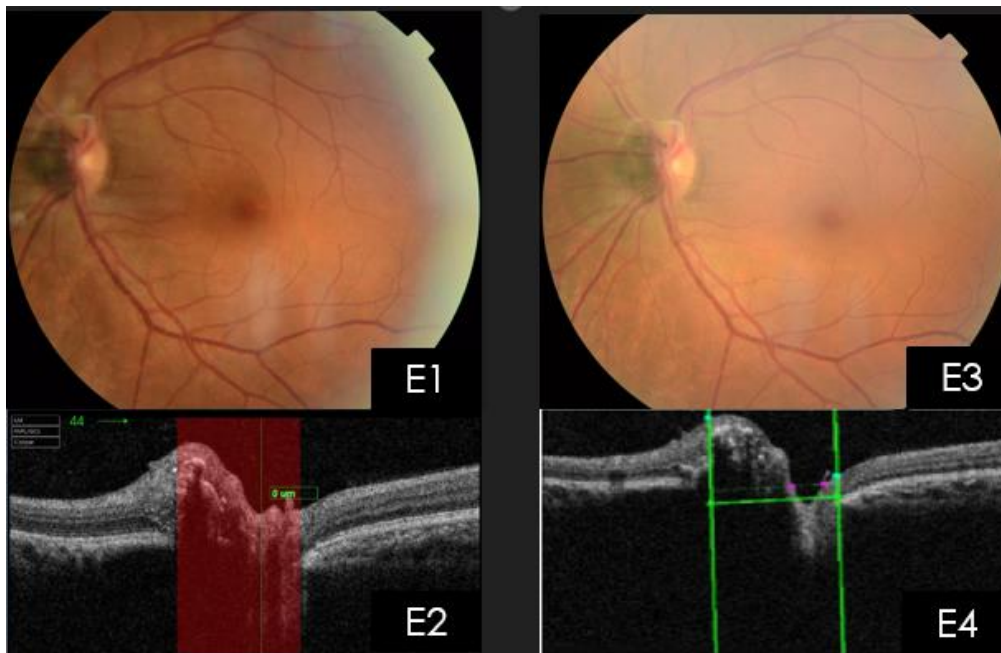


Fig. E: Long-Term Follow-up (2 Years) of Optic Disc Melanocytoma : Stability demonstrated through serial multimodal imaging. E1 and E3 show comparable fundus photographs at baseline and 2-year follow-up, respectively. E2 and E4 illustrate stable OCT characteristics over the two-year period, confirming the benign course of the lesion

DISCUSSION

The Optic Disc Melanocytoma (ODM) is a rare, highly pigmented, and typically benign tumor that arises from the melanocytes located within the lamina cribrosa of the optic nerve head [2]. Historically, this lesion was frequently misdiagnosed as malignant melanoma until Zimmerman and Garron conclusively established its benign nature in 1962 [5]. Histologically, ODM is characterized by large, uniform, deeply pigmented nevus cells [6]. Clinically, it is an incidental finding in the majority of cases, usually presenting unilaterally in asymptomatic patients, most often between the fourth and fifth decades of life [6,7].

Diagnostic Challenge and Multimodal Imaging

The primary clinical imperative is the differentiation of ODM from choroidal malignant melanoma (MM), a distinction essential due to the drastically different prognostic and therapeutic implications [7]. Clinically, ODM presents as a jet-black, dark lesion, often displaying characteristic feathered margins that extend into and infiltrate the peripapillary retinal nerve fiber layer [7].

Paraclinical testing is fundamental to confirming the diagnosis and establishing a baseline for long-term monitoring. Fluorescein Angiography (FA) typically reveals persistent hypofluorescence of the tumor body due to the dense pigment block, though fine telangiectatic vessels may occasionally be observed [7].

In contemporary practice, Optical Coherence Tomography (OCT) and OCT-Angiography (OCT-A) have emerged as critical tools for non-invasive characterization and surveillance [8, 9, 13]. As demonstrated in our case (Figure D), OCT reliably visualizes the tumor's structure as a dome-shaped, elevated lesion with distinct hyperreflective margins and an intense posterior shadowing artifact secondary to heavy melanin absorption. OCT-A provides valuable, detailed insights into the vascularity, helping to rule out the intense intrinsic vascularity often associated with malignant melanomas [13]. Complementary diagnostic tools, such as B-scan ultrasonography and visual field testing (which often detects an enlargement of the physiological blind spot), are also used to complete the functional and structural assessment [10].

Clinical Course and Rationale for Surveillance

The natural history of ODM is overwhelmingly one of clinical stability, a characteristic strongly supported by the two-year stability observed in the patient reported here (Figure E). Nevertheless, the literature reports slow growth in a minority of cases (10–15%), and, more significantly, malignant transformation into melanoma, though exceptionally rare (1–2%), has been documented [11, 12].

Furthermore, ODM is not without risk, as its location can predispose patients to vision-threatening

local complications, including disc edema, tumor necrosis, and secondary retinal vascular occlusion (Central Retinal Artery or Vein Occlusion) [14].

Therefore, management hinges on a rigorous, active surveillance strategy involving regular clinical examination and repeated multimodal imaging (serial fundus photography and OCT) [9, 11]. This conservative approach successfully distinguishes the benign course of ODM from malignant progression, preventing unnecessary invasive procedures, while ensuring the timely detection of any rare local complications or malignant changes [11].

CONCLUSION

The optic disc melanocytoma (ODM) is a typically stable and benign entity, confirmed in our case by two years of multimodal imaging surveillance. However, the potential for slow growth and, albeit rarely, malignant transformation mandates a cautious approach to management. Furthermore, the risk of vision-compromising local complications, such as secondary vascular occlusions or edema, necessitates continuous vigilance.

Given the differential diagnosis with malignant melanoma, we strongly advocate for a strategy of active, long-term annual surveillance. This protocol must include serial multimodal imaging, prioritizing Optic Disc Optical Coherence Tomography (OCT) to precisely assess tumor structure and exclude subretinal fluid, complemented by fundus photography for documenting changes in size and morphology. This non-invasive approach remains crucial for confirming benignity and ensuring prompt intervention should adverse changes occur.

REFERENCES

1. Shields JA, Shields CL, Eagle RC et al. Clinical and imaging features of optic disc melanocytoma. *Intraocular Tumors Text & Atlas*. 2nd ed. 2016.
2. Raval V, Reddy R, Kaliki S, Das T, Singh AD. Optic nerve head melanocytoma: OCT / OCT-Angiography features. *Semin Ophthalmol*. 2020;35(2-3):98-106.
3. Joffe L, Shields JA, Osher RH. Transformation of optic disc melanocytoma into melanoma: long-term follow-up studies. *Arch Ophthalmol*. 1979;97(9):1631-1633.
4. Shields JA, Demirci H, Mashayekhi A, Eagle RC Jr, Shields CL. Melanocytoma of the optic disk: a review. *Surv Ophthalmol*. 2006;51(2):93–104.
5. Zimmerman LE, Garron LK. Melanocytoma of the optic disc. *Int Ophthalmol Clin*. 1962;2(2):431–440.
6. Shields JA, Demirci H, Mashayekhi A, Eagle RC Jr, Shields CL. Melanocytoma of the optic disk: a review. *Surv Ophthalmol*. 2006;51(2):93–104.
7. Shields JA, Shields CL, Eagle RC et al. Clinical and imaging features of optic disc melanocytoma. *Intraocular Tumors Text & Atlas*. 2nd ed.
8. Raval V, Reddy R, Kaliki S, Das T, Singh AD. Optic nerve head melanocytoma: OCT / OCT-Angiography features. (PMC article).
9. Eyewiki – Optic disc melanocytoma and OCT / OCT-A characteristics.
10. Joffe L, Shields JA, Osher RH. Transformation of optic disc melanocytoma into melanoma: long-term follow-up studies. *JAMA Ophthalmol*.
11. Optical coherence tomography angiography characteristics of optic disc melanocytoma – BMC Ophthalmology.
12. Central retinal artery occlusion in optic disk melanocytoma – case report.