

## Severe Grave's Orbitopathy with Triple Complication: Corneal Abscess, Glaucoma, and Optic Nerve Compression—A Case Report

Y. Achegri<sup>1\*</sup>, A. Bouimtarhan<sup>1</sup>, S. Azib<sup>1</sup>, C. Bouabbadi<sup>1</sup>, R. Zerrouk<sup>1</sup>, A. Fiqhi<sup>1</sup>, A. ElKhoyaali<sup>1</sup>, A. Fiqhi<sup>1</sup>, Y. Mouzari<sup>1</sup>

<sup>1</sup>Department of Ophthalmology, Mohamed V Military Study Hospital, Rabat, Morocco

DOI: <https://doi.org/10.36347/sjmcr.2025.v13i12.012> | Received: 02.10.2025 | Accepted: 05.12.2025 | Published: 15.12.2025

\*Corresponding author: Y. Achegri

Department of Ophthalmology, Mohamed V Military Study Hospital, Rabat, Morocco

### Abstract

### Case Report

Thyroid-associated orbitopathy (TAO), also known as Graves' orbitopathy, is an autoimmune disorder affecting orbital tissues and may lead to severe complications including optic neuropathy, secondary glaucoma, and corneal damage. We report a case of a 60-year-old woman with Graves' disease presenting with sight-threatening orbitopathy, manifesting all three complications simultaneously. Ophthalmologic examination revealed bilateral exophthalmos, severe limitation of ocular motility, and a central corneal abscess in the left eye. Imaging confirmed optic nerve compression and a multinodular goiter. Management included intravenous corticosteroid therapy, systemic and topical antibiotics, local hypotensive treatment, frequent ocular lubrication, and tarsorrhaphy, under a multidisciplinary approach involving endocrinology, ophthalmology, and neurosurgery. The patient showed improvement in visual acuity, reduction of inflammatory signs, and partial resolution of exophthalmos. This case highlights the importance of urgent, multidisciplinary management in severe Graves' orbitopathy to preserve visual function and prevent further complications.

**Keywords:** Thyroid-associated orbitopathy, Graves' disease, optic neuropathy, corneal abscess, exophthalmos, corticosteroid therapy, multidisciplinary management.

**Copyright © 2025 The Author(s):** This is an open-access article distributed under the terms of the Creative Commons Attribution 4.0 International License (CC BY-NC 4.0) which permits unrestricted use, distribution, and reproduction in any medium for non-commercial use provided the original author and source are credited.

## INTRODUCTION

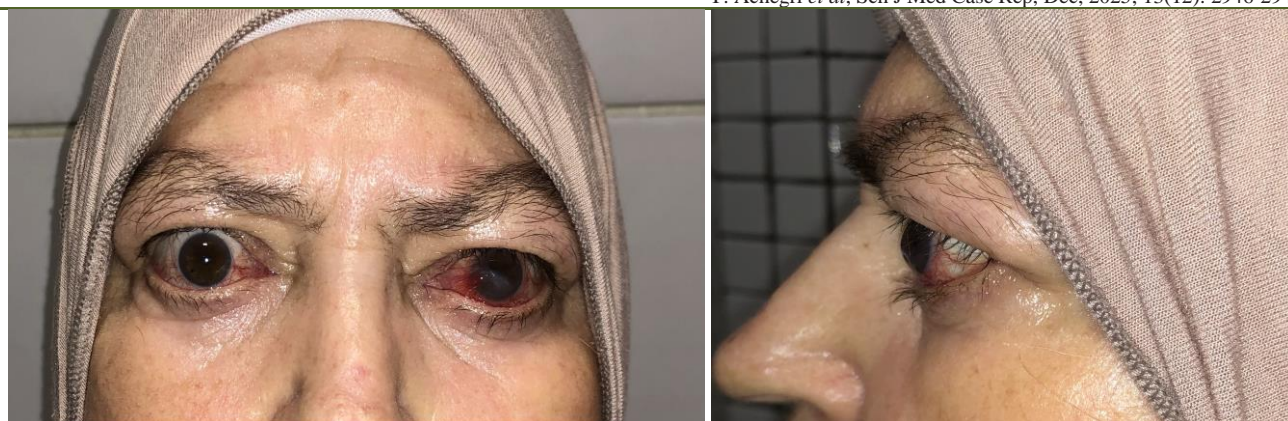Thyroid-associated orbitopathy (TAO), also known as Grave's orbitopathy, is an autoimmune disorder affecting orbital tissues, most commonly associated with Graves' disease. The most severe forms can lead to three potential complications: functional vision loss due to optic neuropathy, either from glaucoma or optic nerve compression, or corneal damage. This paper aims to report a case of sight threatening thyroid-associated orbitopathy that presented all three complications simultaneously, as well as its management.

## PATIENTS AND METHODS

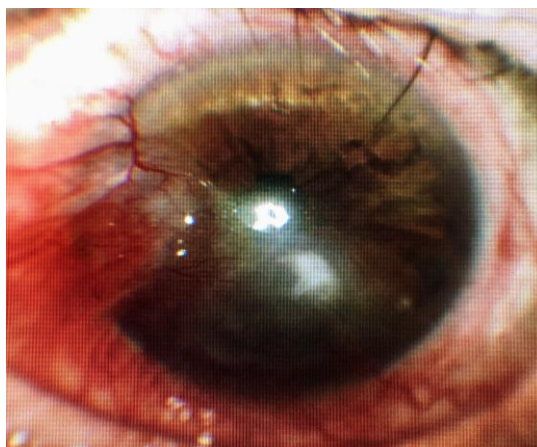The patient is a 60-year-old woman, followed since 2021 for hyperthyroidism due to Graves' disease under treatment. She presented a Grave's orbitopathy associated with bilateral decreased visual acuity, more pronounced in the left eye. Visual acuity was measured

at 5/10 on Monoyer scale in the right eye, and light perception (LP+) in the left eye. Ophthalmologic examination revealed bilateral exophthalmos (Figure 1), with severe limitation of ocular motility in all directions, and a central corneal abscess in the left eye (Figure 2). Intraocular pressure (IOP) measurement in the right eye was 28 mmHg, while IOP in the left eye was found to be elevated on digital palpation.

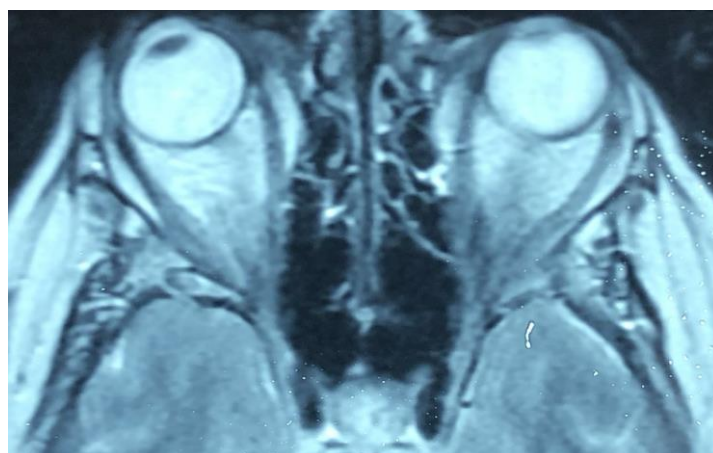
Microbiological sampling of the abscess has found *Streptococcus sp.* And *Candida tropicalis*, requiring systemic antibiotic therapy (fluoroquinolone and imipenem) and local treatment with fortified antibiotic eye drops (vancomycin and ceftazidime) along with voriconazole. Imaging studies confirmed a multinodular goiter, and orbital MRI revealed grade 1 bilateral exophthalmos with compression of both optic nerves (Figure 3). Visual field testing showed a diffusé deficit in the right eye, while the left visual field was untestable due to profound visual acuity loss.



**Figure 1: Photographs showing severe bilateral exophthalmos with significant inflammatory signs.**



**Figure 2: Photograph of the left eye showing a corneal abscess with neovascularization and pterygium**



**Figure 3: Orbital MRI showing grade 3 exophthalmos with compression of both optic nerves**

The patient received six weekly boluses of 500 mg of intravenous methylprednisolone, followed by six additional boluses of 250 mg. She also received local hypotensive treatment (dorzolamide, timolol, brimonidine), frequent ocular lubrication, and a tarsorrhaphy to promote eyelid closure. Multidisciplinary management involving endocrinology, ophthalmology, and neurosurgery facilitated the monitoring and control of both the thyroid disease and orbitopathy. The patient's condition improved, with increased visual acuity in the right eye from LP to 1/10,

a reduction in the corneal abscess and inflammatory signs, as well as decreased exophthalmos and spontaneous eyelid closure.

## DISCUSSION

Grave's orbitopathy is an autoimmune disease primarily affecting the thyroid gland but can also lead to complications in the orbit. The etiology of this condition is linked to excessive thyroid hormone production, caused by the presence of antibodies that stimulate TSH receptors. This abnormal activation of TSH receptors

triggers an inflammatory response in the orbit, leading to edema, fibrosis, and hypertrophy of orbital tissues. The pathogenesis of thyroid-related orbitopathy involves a complex interaction between immune cells, fibroblasts, and orbital adipocytes, leading to significant structural alterations [1].

The etiology of Grave's orbitopathy is primarily associated with overproduction of thyroid hormones and the presence of antibodies stimulating TSH receptors. This abnormal activation of TSH receptors leads to a chronic inflammatory response in the orbit, characterized by fibroblast proliferation and increased secretion of glycosaminoglycans [2]. These pathological changes lead to thickening of orbital tissues, increased water retention, and compression of surrounding structures, such as ocular muscles and the optic nerve. Additionally, Grave's orbitopathy is associated with genetic and environmental factors that may influence individual predisposition to this autoimmune disease.

Severe Grave's orbitopathy refers to a form that threatens short-term visual prognosis and requires urgent management. It complicates 3–5% of cases of thyroid-associated orbitopathy [3,4]. This may present as either compressive optic neuropathy or secondary glaucoma, corneal damage, or, more rarely, all three, as in our case.

Management involves not only treating and monitoring thyroid disease but also urgent treatment of orbitopathy with intravenous corticosteroid boluses [5] and local and systemic antibiotics for the abscess. Symptomatic measures, such as controlling aggravating factors, ocular lubrication, and tarsorrhaphy, help control the evolution under treatment and prevent further complications. Orbital decompression surgery and amniotic membrane grafts are last-resort therapeutic options. It is crucial to implement a multidisciplinary approach involving ophthalmologists, endocrinologists,

and neurosurgeons for optimal management of patients [6].

## CONCLUSION

Severe Grave's orbitopathy is a rare form that jeopardizes visual prognosis. It represents a major diagnostic and therapeutic challenge, and urgent, multidisciplinary management improves short-term symptomatology and limits the functional impact of complications in the medium and long term.

## REFERENCES

1. Adenis J.P., Lasudry J., Robert P.Y.: Orbitopathiedysthyroïdienne. Adenis J.P. Morax S. Société française d'ophtalmologie. Pathologie orbitopalpebrale. 1998. Masson Paris: pp. 38-68
2. Lehmann G.M., Feldon S.E., Smith T.J., Phipps R.: Immune mechanisms in thyroid eye disease. *Thyroid* 2008; 18: pp. 959-965
3. Migliori M.E., Gladstone G.J.: Determination of the normal range of exophthalmometric values for black and white adults. *Am J Ophthalmol* 1984; 98: pp. 438-442
4. J. Delmas, J.-P. Adenis et P.-Y. Robert, Orbitopathies dysthyroïdiennes, *Ophtalmologie*, 2020-03-01, Volume 37, Numéro 1, Pages 1-12, Copyright © 2020 Elsevier Masson SAS
5. Management of Thyroid Eye Disease (Graves Ophthalmopathy) Jennifer A. Villwock Douglas A. Girod Christopher G. Larsen Cummings *Otolaryngology: Head and Neck Surgery*, 125, 1917-1927.e2
6. Lun, A. Y., Le Bras, M., Scharbarg, E., Morcel, P., Hadjadj, S., Lebranchu, P., & Drui, D. (2022). L'orbitopathie basedowienne: diagnostic, épidémiologie et principes de traitement. *La Revue de Médecine Interne*, 43(4), 242-251.