

## Lower Eyelid Avulsion Following Road Traffic Accident: Surgical Reconstruction and Outcome – A Case Report

Rolyf keith AWORE ADJATIN<sup>1\*</sup>, Eriga. LVJ<sup>2</sup>, Yosra Azaro<sup>3</sup>, Mouinga Abayi. D.A<sup>4</sup>

<sup>1</sup>Mohamed V Military Teaching Hospital, Rabat (Morocco)

<sup>2</sup>Omar Bongo Ondimba Military Teaching Hospital, Libreville (Gabon)

<sup>3</sup>Specialty Hospital, Rabat (Morocco)

<sup>4</sup>Omar Bongo Ondimba Military Teaching Hospital, Libreville (Gabon)

DOI: <https://doi.org/10.36347/sjmcr.2025.v13i12.031>

| Received: 10.10.2025 | Accepted: 03.12.2025 | Published: 26.12.2025

\*Corresponding author: Rolyf keith AWORE ADJATIN

Mohamed V Military Teaching Hospital, Rabat, Morocco

### Abstract

### Case Report

**Background:** Eyelid avulsion is a rare but serious injury usually associated with severe facial trauma. Due to the eyelid's intricate anatomy and crucial role in protecting the eye, such injuries constitute a surgical emergency. Prompt repair by an experienced ophthalmic surgeon is required to restore both functional and aesthetic integrity. **Case Presentation:** We report a 25-year-old male who sustained a left lower eyelid avulsion following a road traffic accident caused by glass fragments. The avulsion involved the medial canthus and lower eyelid margin, accompanied by a smaller upper eyelid laceration and conjunctival hyperemia. Visual acuity was 10/10 in both eyes. The patient received systemic antibiotics, anti-inflammatory medication, topical dexamethasone-neomycin, and artificial tears before undergoing layered surgical reconstruction. The conjunctival fornix was reconstituted with 7-0 Vicryl, the medial canthus reattached with 6-0 Prolene, the muscular layer closed with 8-0 Vicryl, and the skin sutured with 6-0 Prolene. Postoperative recovery was favorable, with mild transient edema at day 10 and complete healing at one month without epiphora or lid malposition. **Conclusion:** Early meticulous repair by an ophthalmic surgeon ensures satisfactory cosmetic and functional outcomes in eyelid avulsion injuries. Delay in management can result in significant sequelae such as ectropion, notching, or chronic tearing.

**Keywords:** eyelid avulsion, road traffic accident, eyelid reconstruction, trauma, ophthalmic surgery.

Copyright © 2025 The Author(s): This is an open-access article distributed under the terms of the Creative Commons Attribution 4.0 International License (CC BY-NC 4.0) which permits unrestricted use, distribution, and reproduction in any medium for non-commercial use provided the original author and source are credited.

## INTRODUCTION

Eyelid avulsion is defined as the traumatic detachment or tearing away of the eyelid from its normal anatomical insertions. Although relatively infrequent, this type of injury represents a true ophthalmic emergency because of its potential to cause both functional impairment and significant cosmetic deformity. The eyelids play an essential role in ocular protection, tear distribution, and maintenance of corneal health; their disruption may therefore result in exposure keratitis, secondary infection, or even permanent vision loss if not promptly repaired [1].

The main causes of eyelid avulsion include road traffic accidents, physical assaults, animal bites, and occupational or industrial trauma [2]. In developing regions, glass-related motor-vehicle collisions are the most frequently reported mechanism, particularly among young adults [3]. Epidemiological studies from sub-

Saharan Africa indicate that eyelid lacerations and avulsion injuries account for roughly 11.7% of all eyelid trauma cases [4].

Either the upper or lower eyelid may be affected, but the lower lid is more commonly involved because of its thinner structure and close relationship to the bony orbital rim [5]. The medial canthal region is especially at risk due to the presence of the lacrimal drainage apparatus and the medial canthal tendon; injury in this area can lead to functional disturbances and esthetic asymmetry [6].

The primary objectives of treatment are to restore normal eyelid anatomy, ensure proper lid-globe apposition, and preserve the tear drainage pathway while optimizing cosmetic outcomes [8]. Early and accurate repair by a trained oculoplastic or ophthalmic surgeon remains the key factor determining prognosis [9]. The present report describes a case of lower eyelid avulsion

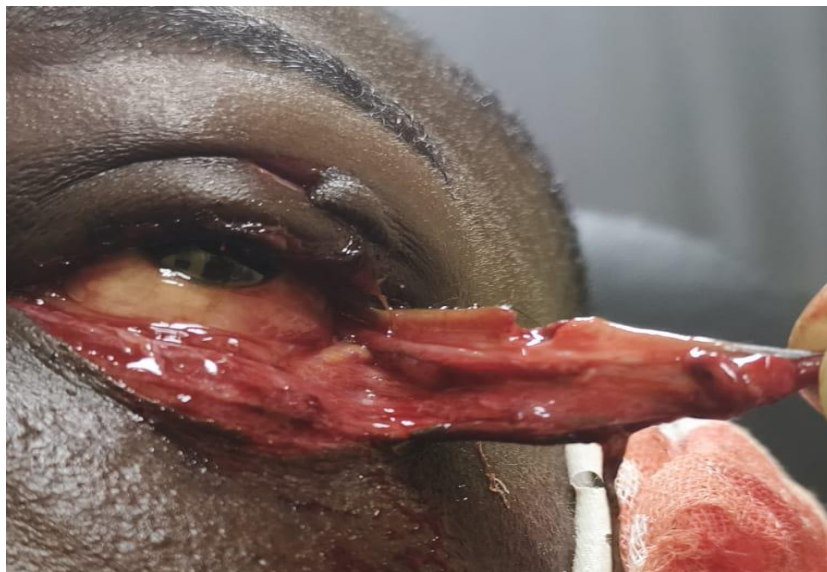**Citation:** Rolyf keith AWORE ADJATIN, Eriga. LVJ, Yosra Azaro, Mouinga Abayi. D.A. Lower Eyelid Avulsion Following Road Traffic Accident: Surgical Reconstruction and Outcome – A Case Report. Sch J Med Case Rep, 2025 Dec 13(12): 3018-3024.

successfully managed through layered reconstruction and highlights the technical considerations and challenges encountered during such procedures.

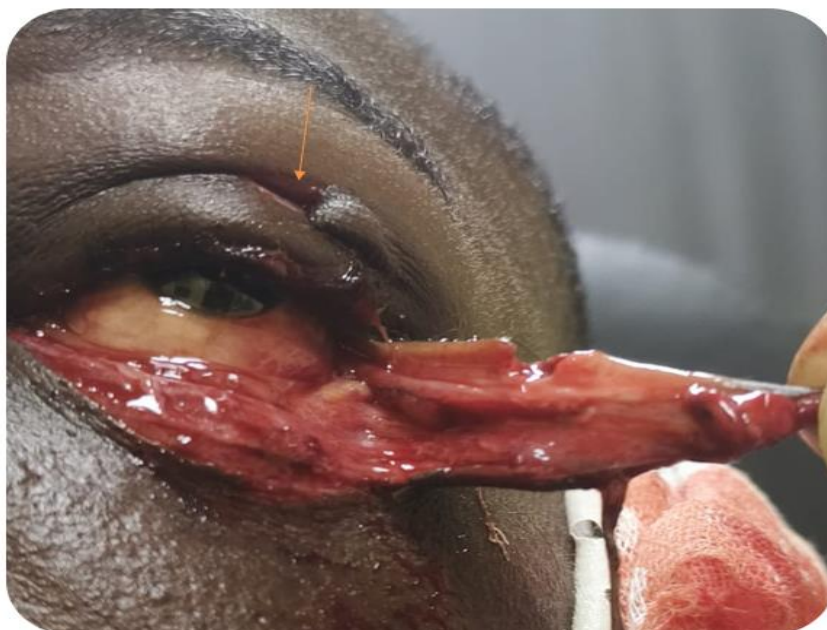## CASE PRESENTATION

A 25-year-old male patient was referred from the emergency unit to the ophthalmology department of Hôpital d'Instruction des Armées Omar Bongo Ondimba for management of a left eyelid injury sustained during a road traffic accident. A collision between two vehicles caused the windshield to shatter, leading to facial trauma. The injury occurred approximately two hours prior to presentation. Visual acuity was 10/10 in both eyes. The left lower eyelid showed a complete avulsion involving

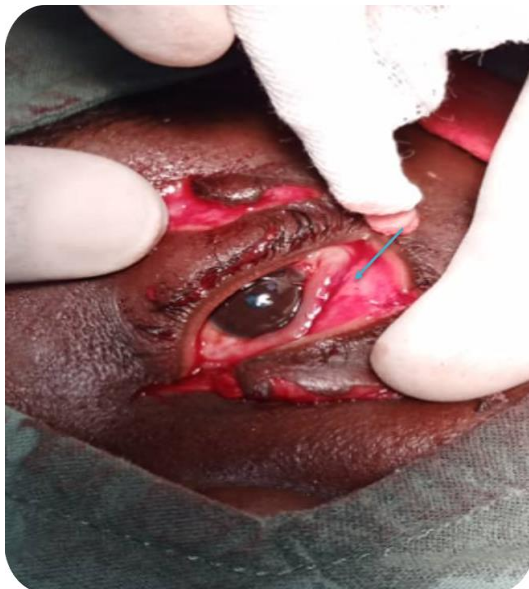the medial canthus and one-third of the lower eyelid margin (see Figure 1). There was a superficial laceration of the upper eyelid (see Figure 2) and marked conjunctival hyperemia. Surgical exploration confirmed the complete avulsion of the lower eyelid, including detachment of the medial canthal tendon and partial loss of the conjunctival cul-de-sac. The reconstruction was performed in layers: conjunctival fornix with 7-0 Vicryl (see Figure 3), medial canthus repositioning with 6-0 Prolene (see Figure 4), orbicularis oculi repair with 8-0 Vicryl (see Figure 5), and skin closure with 6-0 Prolene (see Figure 6). Postoperatively, healing was excellent, with mild edema at day 10 (see Figure 7) and complete recovery at day 30 (see Figures 8–10) with a satisfactory final aesthetic appearance at day 60 (see Figure 11).



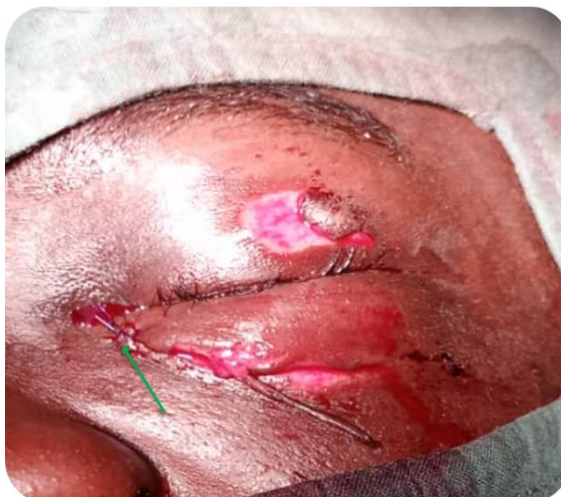**Figure 1: Preoperative view showing lower eyelid avulsion**



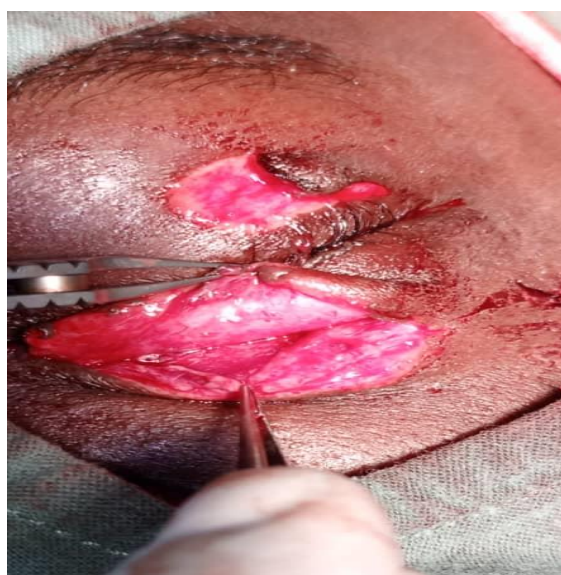
**Figure 2: Associated upper eyelid laceration**



**Figure 3: Reconstruction of the conjunctival fornix**

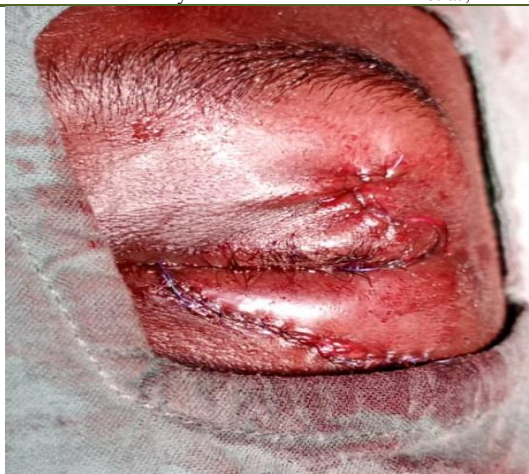

**Figure 4: Medial canthus repositioning**

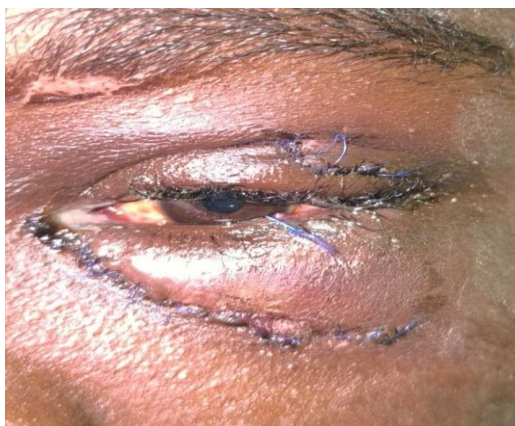

**Figure 5: Muscular layer suturing**

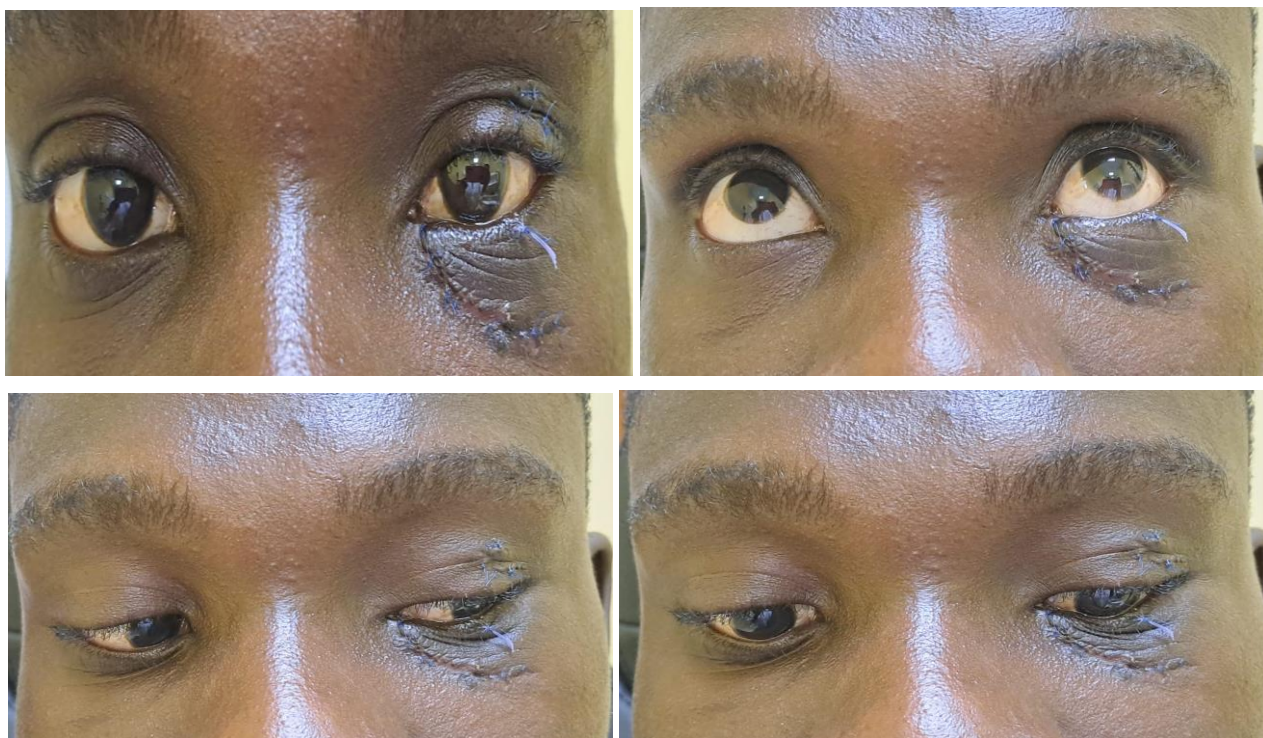




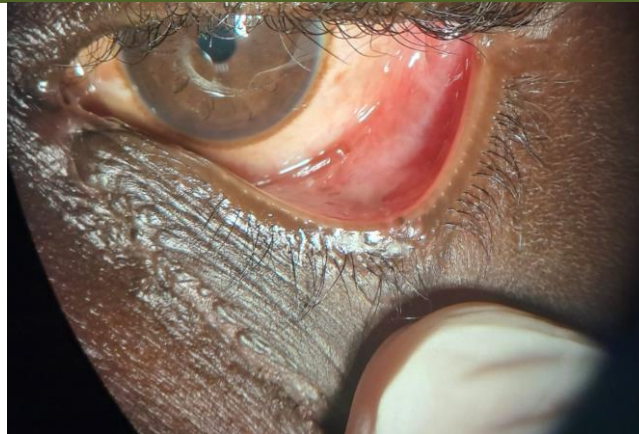
**Figure 6: Cutaneous closure with 6-0 Prolene**



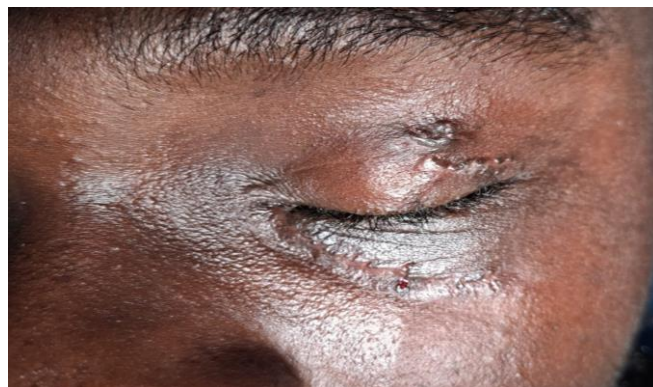**Figure 7: Day 10 postoperative follow-up showing mild edema**



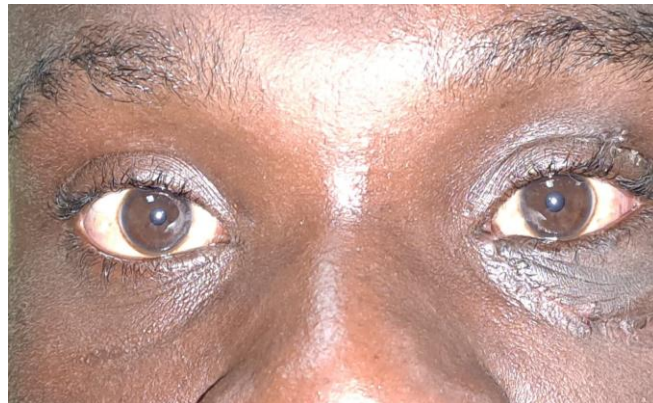**Figure 8: Day 30 postoperative result showing normal lid position and normal static lid function**



**Figure 9: Day 30 postoperative result showing Reformed conjunctival cul-de-sac**



**Figure 10: Day 30 postoperative result showing symmetrical palpebral aperture**



**Figure 11: Day 60 postoperative result showing Final esthetic appearance and overview of complete reconstruction**

## DISCUSSION

Eyelid avulsion is among the most complex emergencies encountered in oculofacial surgery. The diversity of the anatomical structures involved — including the skin, orbicularis muscle, tarsus, conjunctiva, and canthal system — requires a meticulous reconstruction that respects the lamellar organization of the eyelid in order to restore both function and esthetics. Successful management depends on early, precise surgical intervention, ideally within the first few hours following trauma, to preserve tissue viability and prevent secondary complications [10].

Anatomical reconstruction must faithfully reproduce the three structural lamellae of the eyelid: the posterior lamella, which provides support and rigidity to the lid margin; the middle lamella, which determines contour and tone; and the anterior lamella, responsible for mobility and skin coverage [11]. Layer-by-layer closure re-establishes the natural curvature and tension balance of the eyelid, ensuring normal blink dynamics.

Precise reconstruction of the conjunctival fornix prevents adhesions and supports ocular motility, as it prevents symblepharon formation and preserves ocular motility. Correct repositioning of the medial



canthus (see Figure 6) is equally essential to restore eyelid anchorage and maintain the physiological axis of the lacrimal drainage system. Repair of the orbicularis oculi muscle (see Figure 7) reinstates active lid closure and corneal protection, while also contributing to an aesthetically pleasing result.

The choice of surgical technique depends on the extent of tissue loss. Limited defects can be repaired directly, whereas more extensive avulsions require local or regional flaps, such as the Mustardé cheek rotation flap or the Hughes tarsoconjunctival flap [12,13]. In the present case, adequate tissue viability allowed for direct layered closure without grafting.

When the lacrimal canaliculus cannot be clearly identified, omission of intubation is acceptable provided that the medial eyelid structures are precisely realigned. Several authors, including Reifler and Kakizaki, have reported satisfactory functional outcomes without silicone stenting when anatomical realignment is accurate [14,15].

Eyelid avulsion is among the most complex emergencies encountered in oculofacial surgery. The diversity of the anatomical structures involved — including the skin, orbicularis muscle, tarsus, conjunctiva, and canthal system — requires a meticulous reconstruction that respects the lamellar organization of the eyelid in order to restore both function and esthetics. Successful management depends on early, precise surgical intervention, ideally within the first few hours following trauma, to preserve tissue viability and prevent secondary complications [10].

Anatomical reconstruction must faithfully reproduce the three structural lamellae of the eyelid: the posterior lamella, which provides support and rigidity to the lid margin; the middle lamella, which determines contour and tone; and the anterior lamella, responsible for mobility and skin coverage [11]. Layer-by-layer closure re-establishes the natural curvature and tension balance of the eyelid, ensuring normal blink dynamics.

Postoperative care is equally important for achieving optimal results. Control of edema, prevention of infection, and regular ocular lubrication facilitate proper healing. At one-month follow-up (see Figures 8–10), the patient showed complete recovery with symmetrical eyelid contour and preserved lacrimal function, consistent with outcomes documented in earlier clinical studies [16].

Complications described in clinical series include eyelid malposition (ectropion or entropion), skin necrosis, secondary infection, and chronic epiphora. These are most often related to excessive suture tension or inadequate tarsal plane reconstruction. Atraumatic surgical technique, precise respect for anatomical landmarks, and early referral to an experienced

oculoplastic surgeon remain essential to minimize such sequelae.

This case underscores the necessity of a multidisciplinary approach to eyelid-avulsion management, combining rapid intervention, thorough anatomical knowledge, and meticulous surgical technique. Anatomically faithful and functionally stable reconstruction allows long-term protection of the ocular surface while achieving an excellent cosmetic outcome.

## CONCLUSION

Eyelid avulsion is an uncommon but challenging emergency in oculoplastic surgery, where the final outcome depends largely on the speed and precision of management. This case underscores the value of prompt, carefully planned surgical intervention that respects the eyelid's anatomical structure and restores both function and appearance.

Successful reconstruction requires an accurate clinical evaluation, a thorough understanding of eyelid anatomy, and refined microsurgical technique. Performing the repair without delay, using delicate sutures suited to each layer, and ensuring attentive postoperative follow-up are key measures that help prevent complications such as eyelid malposition, persistent tearing, or canthal instability.

Comprehensive management of eyelid avulsion should integrate timely surgical repair, multidisciplinary coordination, and vigilant postoperative care, which together secure long-term functional preservation and satisfactory aesthetic recovery.

## Patient Consent

Written informed consent was obtained from the patient for publication of this case report and accompanying images.

**Conflict of Interest:** The authors declare no conflict of interest.

## REFERENCES

1. Mouinga Abayi D.A. *et al.*, Epidemiology and management of eyelid lacerations in Gabon. *Health Res Afr.* 2024 ; 2(4): 32-37.
2. Awidi AA, Zhao J, Li X, Rajaii F, Ahmad M, Jensen A, Woreta FA. Etiology and Characteristics of Patients Presenting with Eyelid Lacerations at a Level 1 Trauma Center. *Clin Ophthalmol.* 2024 ;18 :929-935
3. Collin J.R., Welham R.A. A Manual of Systematic Eyelid Surgery. Edinburgh : Churchill Livingstone ; 1989.
4. Nelson CC. Management of eyelid trauma. *Aust N Z J Ophthalmol.* 1991 Nov ;19(4):357-63.
5. Reifler D.M. Management of canalicular laceration. *Surv Ophthalmol.* 1991 ; 36: 113-132.

6. Codner MA, McCord CD, Mejia JD, *et al.*, Upper and lower eyelid
7. Alghoul MS, Kearney AM, Pacella SJ, Purnell CA. Eyelid Reconstruction. *Plast*
8. Francesco Bernardini, Brent Skippen. Principles and Techniques of Eyelid Reconstruction. 2019, *Surgical Ophthalmic Oncology*, p. 33-57
9. Kunaal Jindal, Marc Sarcia, Mark A. Codner. Functional Considerations in Aesthetic Eyelid Surgery. 2014, *Plastic and Reconstructive Surgery*, № 6, p. 1154-1170
10. Reifler DM. Management of canalicular laceration. *Surv Ophthalmol*. 1991 Sep-Oct;36(2):113-32.
11. Arnaud Martel *et al.*, Management of Injuries to the Lacrimal Drainage System and Medial Canthus. *Oculoplastic, Lacrimal and Orbital Surgery* (pp.679-687)
12. Alghoul M, Pacella SJ, McClellan WT, Codner MA. Eyelid reconstruction. *Plast Reconstr Surg*. 2013 Aug ;132(2):288e-302e.
13. Ward D. Techniques in Ophthalmic Plastic Surgery with DVD. A Personal Tutorial. *Ann R Coll Surg Engl*. 2011 Mar ;93(2):177.
14. Nerad JA. *Oculoplastic Surgery (The Requisites in Ophthalmology)*. Chicago: American Medical Association; 2002.
15. Reconstructive designs for the eyelids. *Czyz, Craig N. et al., Operative Techniques in Otolaryngology-Head and Neck Surgery, Volume 22, Issue 1, 35 – 46*
16. Alghoul MS, Kearney AM, Pacella SJ, Purnell CA. Eyelid Reconstruction. *Plast Reconstr Surg Glob Open*. 2019 Nov 27;7(11):e2520.