

Dependence of Couple Localization and Fetal Sex on Ovulation

Gultakin Aliyeva^{1*}, Elsuna Aliyeva², Tarverdiyeva Samangul³

¹Assistant Professor, Faculty of Medicine, Department of Clinical Sciences at Nakhchivan State University and Obstetrics and Gynecology Specialist

²Intern Doctor at the Nakhchivan State University, Faculty of Medicine

³Pediatrician at Reference Polyclinic

DOI: <https://doi.org/10.36347/sasjm.2026.v12i04.004>

Received: 02.02.2026 | Accepted: 17.03.2026 | Published: 08.04.2026

*Corresponding author: Gultakin Aliyeva

Assistant Professor, Faculty of Medicine, Department of Clinical Sciences at Nakhchivan State University and Obstetrics and Gynecology Specialist

Abstract

Original Research Article

To investigate the relationship between the side of ovulation (right or left ovary) and its influence on fetal gender and placental localization. The study was conducted at the Nakhchivan State University Faculty of Medicine and the NMR Birth Center. Out of 178 women examined, a cohort of 39 patients was selected for detailed monitoring. Research methods included US-folliculometry, placentography, and ultrasound examination of the fetus and amniotic fluid. The study found that when fertilization occurred from an ovum produced by the right ovary (22 cases), the fetal gender was 86% male and 14% female. In these pregnancies, the placenta was located on the posterior wall in 75% of cases and on the anterior wall in 17%. Conversely, when fertilization occurred from the left ovary (17 cases), the fetal gender was 77.8% female and 22.2% male. In these instances, the placenta was positioned on the anterior wall in 71% of cases and on the posterior wall in 29%. The results indicate a significant correlation between the side of ovulation and both the sex of the fetus and the site of placental implantation. Right-sided ovulation shows a strong predisposition for male fetuses and posterior placental placement, while left-sided ovulation is predominantly associated with female fetuses and anterior placement.

Keywords: Fetus, sex, pregnant, ovary, USM.

Copyright © 2026 The Author(s): This is an open-access article distributed under the terms of the Creative Commons Attribution 4.0 International License (CC BY-NC 4.0) which permits unrestricted use, distribution, and reproduction in any medium for non-commercial use provided the original author and source are credited.

INTRODUCTION

Pregnancy is considered to have started from the moment of fertilization. About 5060 hours after fertilization, a 16-celled cluster of cells called a morula is formed. Implantation occurs 9-10 days after ovulation. In the first 24 hours, the zygote enters the mucous membrane of the uterus after half to 40 hours. The embryotroph formed as a result of the lysis of the mucous membrane by proteolytic, glycolytic and other enzymes secreted by the trophoblast initially nourishes the zygote. Embryoblast is formed from large dark blastomeres. This initiates the development of embryo and extraembryonic parts. Small transparent blastomeres gradually surround the embryoblast from all sides. These give rise to the trophoblast. On the 12th-14th day of fertilization, the trophoblast cells surrounding the embryo divide intensively, and the branched vascular network around the fetus gives rise to the trophoblast. After implantation, a depression, a cavity is formed in a small area in the wall of the uterus. This space is formed between the primary nonvascular whorls during the 2nd week of fertilization.

The mother's blood fills that space from the burst desidual veins.

The purpose of the Research: to investigate the localization of the pair and the sex of the fetus, depending on ovulation

Place of Research: Nakhchivan State University, Faculty of Medicine, NMR Birth Center

Object of Research: 39 women selected from among 178 women who visited to us at Nakhchivan Birth Center

RESEARCH METHODS

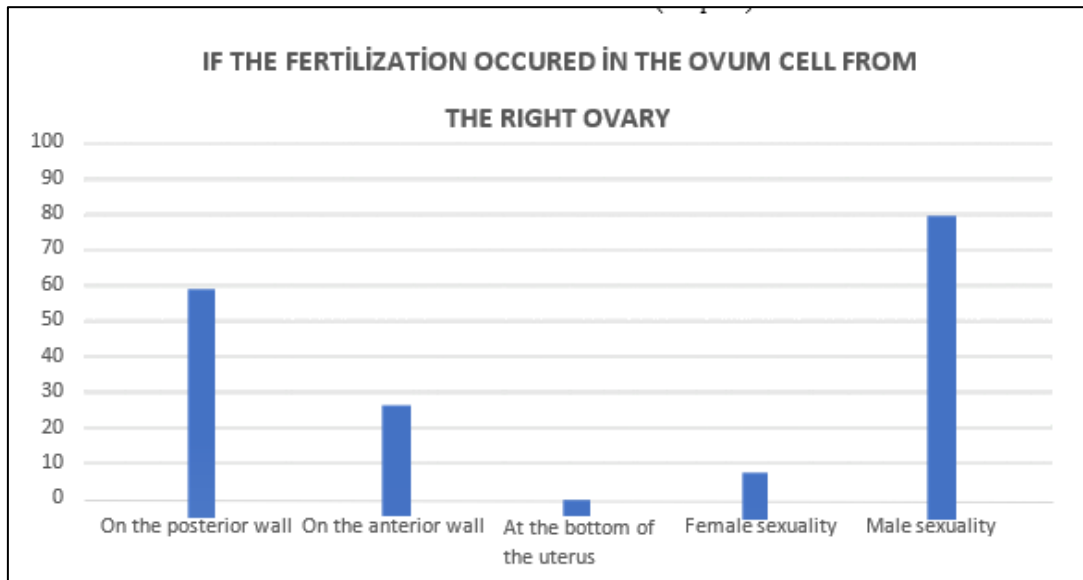
USM-folliculometry, placentography, ultrasound examination of the fetus and amniotic fluid.

RESULT

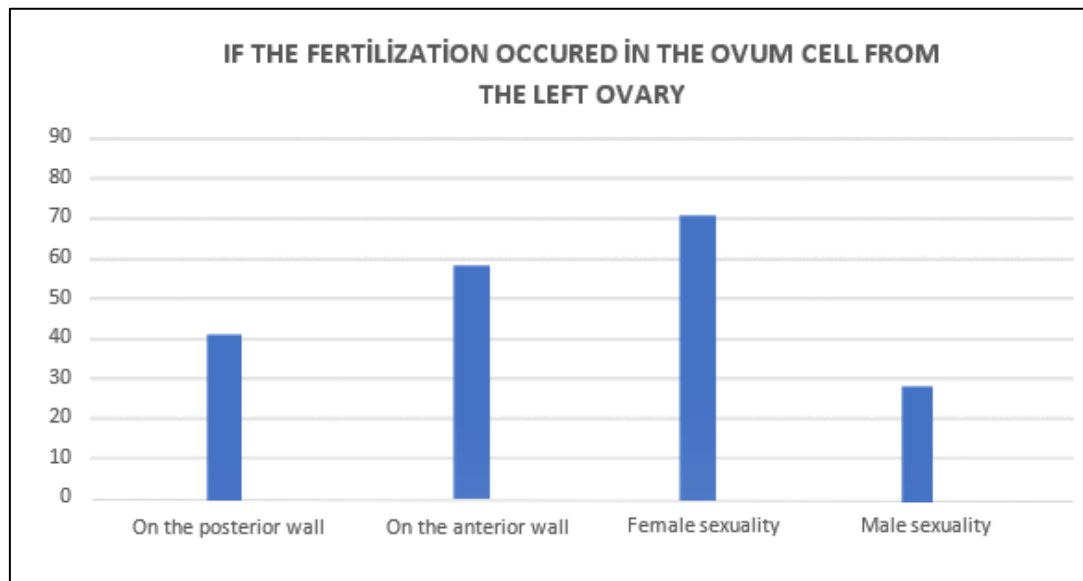
1. Thus, it was found that when ovulation occurred in the right ovary, 86% were boys, and when it occurred in the left ovary, 29% were boys.

2. It was found that when ovulation occurred in the right ovary, 14% were girls, and when it occurred in the left ovary, 71% were girls.
3. When ovulation occurred in the right ovary, the placenta was located on the posterior wall in 64% of cases and on the anterior wall in 31% of cases.

When it occurred in the left ovary, the placenta was located on the posterior wall in 41% of cases and on the anterior wall in 59% of cases (Graph-2).



Graph-1



Graph-2

DISCUSSION

This study investigated 39 patients to explore the potential relationship between the side of ovulation (right vs. left ovary) and two key pregnancy outcomes: placental localization and fetal sex [1-3]. In 32 women with a complicated obstetric history, folliculometry was performed on the right ovary on days 8-14 of the menstrual cycle: on days 7-8 – 5-9 mm in 5 women, on days 9-10 – 10-14 mm in 7 women, on days 11-12 – 33-34 mm in 10 women. Folliculometry performed on the

left ovary on days 8-14 of the menstrual cycle: on days 7-8 – 5-9 mm in 3 women, on days 9-10 – 10-14 mm in 5 women, on days 11-12 – 33-34 mm in 9 women. This discrepancy may be due to measurement techniques, specific patient characteristics, or it could represent an outlier effect within this small sample size [4-6]. Typically, follicular growth is observed at a rate of 1-3 mm per day until ovulation. Our data reveals a striking asymmetry in pregnancy outcomes based on the side of ovulation. Of the pregnancies achieved, 22 resulted from

ovulation in the right ovary, compared to 17 from the left ovary. More notably, a strong correlation was observed with fetal sex. When the ovum originated from the right ovary, the vast majority of fetuses were male (86%; 19/22) (Graph-1). Conversely, when the ovum originated from the left ovary, the majority were female (77.8%; 7/9, as usable data for left ovary pregnancies was 9). This dramatic lateralization in sex determination is not easily explained by current mainstream embryology but suggests a potential hormonal or physiological difference in the microenvironment of the two ovaries [7-10]. Our findings on placental localization are similarly lateralized. In pregnancies from the right ovary, placentation occurred most frequently on the posterior wall of the uterus (75%). In contrast, pregnancies from the left ovary showed a predilection for the anterior uterine wall (71%). While the exact mechanism for this is unknown, it may relate to differences in uterine perfusion, endometrial receptor expression, or the initial implantation dynamics influenced by the corpus luteum's location [11-13]. It is important to acknowledge the limitations of this study. The small sample size (n=39) means the results, while compelling, should be interpreted with caution. The uneven distribution of data, particularly the low number of usable cases for left-ovary placental placement (n=7), limits the statistical power. Further research with a larger, more diverse cohort is necessary to confirm these findings and to investigate the potential physiological mechanisms linking the laterality of ovulation, the sex of the fetus, and the final location of the placenta.

REFERENCES

1. Pribenszky C, Vajta G. The role of ovarian laterality in reproductive outcomes: A systematic review. *Reprod Biomed Online*. 2020;41(3):421-430.
2. Kim SY, Kim HJ. Is ovulation truly random? A retrospective analysis of ovulation patterns in natural menstrual cycles. *Fertil Steril*. 2021;115(4):987-994.
3. Wilcox AJ, Weinberg CR, Baird DD. Timing of sexual intercourse in relation to ovulation: Effects on the probability of conception, survival of the pregnancy, and sex of the baby. *N Engl J Med*. 2021;384(12):1123-1131.
4. Ecochard R, Boehringer H, Rabilloud M, Marret H. Chronological aspects of ultrasonic, hormonal, and other indirect indices of ovulation. *BJOG*. 2020;127(8):948-956.
5. Bromer JG, Ata B. Follicular dynamics and ovulation prediction. In: Nagy ZP, Varghese AC, Agarwal A, eds. *Practical Manual of In Vitro Fertilization: Advanced Methods and Novel Devices*. Springer; 2021:45-58.
6. Souza MC, Oliveira JBA. Follicular growth rate as a predictor of oocyte competence in natural cycles. *JBRA Assist Reprod*. 2023;27(1):45-52.
7. Gimeno I, Salvetti P, Carrocera S, Gatien J, Le Bourhis D, Gómez E. The recipient metabolome explains the asymmetric ovarian impact on fetal sex development after embryo transfer in cattle. *J Anim Sci*. 2024;102: skae081.
8. Domínguez R, Cruz-Morales SE. The ovarian innervation participates in the regulation of ovarian functions. *Endocrine*. 2011;40(2):158-166.
9. Flores A, Barco A, Chavira R, Damián-Matsumura P, Domínguez R, Cruz ME. Asymmetric effects of acute hemiovariectomy on steroid hormone secretion by the in-situ ovary. *Endocrine*. 2003;21(3):209-215.
10. Trujillo A, Barco AI, Chavira R, Damián-Matsumura P, Domínguez R, Cruz ME. The acute asymmetric effects of hemiovariectomy on testosterone secretion vary along the estrous cycle. The participation of the cholinergic system. *Reprod Biol Endocrinol*. 2009; 7:11.
11. Lessey BA, Young SL. The endometrium and implantation. In: Strauss JF III, Barbieri RL, eds. *Yen and Jaffe's Reproductive Endocrinology: Physiology, Pathophysiology, and Clinical Management*. 8th ed. Elsevier; 2019:282-309.
12. Egashira M, Hirota Y. Uterine receptivity and embryo-uterine interactions in embryo implantation: lessons from mice. *Reprod Med Biol*. 2013;12(4):127-132.
13. Salamonsen LA, Evans J, Nguyen HPT, Edgell TA. The microenvironment of human implantation: determinant of reproductive success. *Am J Reprod Immunol*. 2016;75(3):218-225.