

Eruption Trajectory of Maxillary Canines in Patients Aged 8–10 Years Attended at the DEPEI, School of Dentistry, Between 2018 and 2022

González Núñez Cesar Darío^{1*}, Maldonado Antunez María Guadalupe²

¹Adjunct Professor, Pediatric Dentistry Specialty Program, DEPEI, Faculty of Dentistry, National Autonomous University of Mexico

²Pediatric Dentistry Specialty Student, Division of Postgraduate Studies and Research (DEPEI), Faculty of Dentistry, National Autonomous University of Mexico (UNAM)

DOI: <https://doi.org/10.36347/sjds.2026.v13i06.001>

Received: 01.05.2026 | Accepted: 08.06.2026 | Published: 10.06.2026

*Corresponding author: González Núñez Cesar Darío

Adjunct Professor, Pediatric Dentistry Specialty Program, DEPEI, Faculty of Dentistry, National Autonomous University of Mexico

Abstract

Original Research Article

Ectopic eruption is a common dental anomaly whose prevalence varies among populations and dental groups. The prevalence of ectopic eruption of the permanent maxillary canine has been reported to range from 1% to 3% worldwide, with significant ethnic variations. **Objective:** To determine the most frequent eruption path of maxillary canines using panoramic radiographs and the Ericson and Kuroil method in children aged 8 to 10 years treated at the Pediatric Dentistry Department (DEPEI). **Materials and Methods:** A descriptive, cross-sectional, observational study was conducted. From 790 patient records collected between 2018 and 2022, inclusion and exclusion criteria were applied, resulting in a final sample of 170 panoramic radiographs. Data were processed and analyzed using Microsoft Excel 365 and IBM SPSS Statistics software. **Results:** Of the 170 panoramic radiographs evaluated, 92 (54.1%) corresponded to males and 78 (45.9%) to females. The highest frequency was observed among 9-year-old males (n = 47) and 8-year-old females (n = 40). Female patients showed a greater tendency toward an unfavorable eruption path associated with an increased risk of maxillary canine impaction. **Conclusions:** Early identification of alterations in the eruption path of maxillary canines during the mixed dentition stage may facilitate timely diagnosis and interceptive treatment, potentially reducing the risk of canine impaction and its associated complications.

Keywords: Tooth Cuspid, Tooth Impacted, Tooth Eruption, Radiography Panoramic, Mixed Dentition, Risk Assessment.

Copyright © 2026 The Author(s): This is an open-access article distributed under the terms of the Creative Commons Attribution 4.0 International License (CC BY-NC 4.0) which permits unrestricted use, distribution, and reproduction in any medium for non-commercial use provided the original author and source are credited.

INTRODUCTION

Ectopic eruption is a common dental anomaly whose prevalence varies among populations and dental groups. The prevalence of ectopic eruption of the permanent maxillary canine has been reported to range from 1% to 3% worldwide, with significant ethnic variations. Furthermore, the permanent maxillary canine is the second most frequently impacted tooth after the third molar. In Caucasian populations, the prevalence of ectopic eruption of the permanent maxillary canine ranges between 2% and 3% (Alqerban A *et al.*, 2016). As impacted teeth remain unerupted, the severity of displacement and angulation may increase with age. Therefore, early detection through radiographic assessment, measurements, and angular analyses is essential for identifying deviations in the eruption path. Previous studies have reported a higher prevalence of ectopic eruption and impaction of maxillary canines in females than in males. Failure to diagnose alterations in

the eruption path of maxillary canines at an early stage may increase the risk of ectopic eruption and subsequent impaction.

The etiology of ectopic eruption is multifactorial and has been associated with inadequate arch space, root dilaceration, dental trauma, ankylosis of primary teeth, mesial migration of adjacent teeth following premature loss of primary teeth, ectopic positioning of tooth germs, inflammatory processes, pathological lesions, displacement and resorption of adjacent teeth, among other local factors. Systemic conditions, syndromes, and infections have also been implicated in its development (Becker A *et al.* 2015). Early diagnosis allows clinicians to identify deviations in the eruption path of maxillary canines and implement interceptive treatment strategies when necessary, thereby reducing the risk of impaction and its associated complications (de Mendonça *et al.*, 2012) (Díaz-González L *et al.*, 2022)

Objective

The aim of this study was to determine the most common eruption path of maxillary canines using panoramic radiographs and the Ericson and Kuroi method in children aged 8 to 10 years treated at the Pediatric Dentistry Department (DEPeI).

MATERIALS AND METHODS

Ethical Considerations

This study was reviewed and approved by the Research and Ethics Committee of the Faculty of Dentistry, National Autonomous University of Mexico (UNAM), under approval number CIE/0101/12/2023.

Study Design and Sample Selection

A descriptive, cross-sectional, observational study was conducted. Data were collected from patient records archived by the Pediatric Dentistry Clinic of the Division of Postgraduate Studies and Research (DEPeI), Faculty of Dentistry, UNAM. A total of 790 patient records from 2018 to 2022 were screened. After applying the inclusion and exclusion criteria, a final sample of 170 records was obtained.

Inclusion Criteria

1. Pediatric patients aged 8 to 10 years treated at the Pediatric Dentistry Clinic of DEPeI.
2. Inactive patient records archived between 2018 and 2022.
3. Records containing a signed informed consent form provided by parents or legal guardians.

4. Availability of a panoramic radiograph (orthopantomogram) as a diagnostic aid.

Exclusion Criteria

1. Absence of a signed informed consent form.
2. Absence of a panoramic radiograph.
3. Patients outside the established age range.

Elimination Criteria

Radiographs presenting inadequate image quality, including distortion, elongation, poor density, contrast, sharpness, resolution, or improper positioning of the region of interest, were excluded from the analysis.

Study Variables

The variables analyzed were angular measurements obtained from panoramic radiographs according to the method described by Ericson and Kuroi (1988).

The inclination angle (α) of the permanent maxillary canine relative to the facial midline was measured and classified into three categories:

1. $\alpha < 20^\circ$
2. $\alpha = 21^\circ-40^\circ$
3. $\alpha > 40^\circ$

(Figure 1)

For the purposes of this study, a permanent maxillary canine was considered to present an ectopic eruption path when the angulation exceeded 21° .

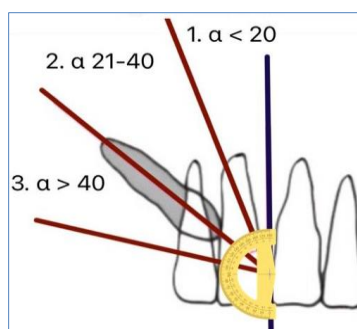


Figure 1: Inclination angle (α) of the permanent maxillary canine relative to the facial midline

Data Collection Procedure

1. Panoramic radiographs were retrieved from the selected patient records and mounted on a 10-watt HSK LED lightbox with a maximum illumination of 4500 lux.
2. The lightbox was positioned vertically against a wall.
3. Images were captured using a Canon EOS Rebel T7 digital camera in automatic mode, without flash, at a standardized distance of 40 cm from the radiograph.
4. Photographs were stored in RAW format.

5. Angular measurements were subsequently traced using Microsoft PowerPoint according to the Ericson and Kuroi method (Figure 2).
6. All measurements were recorded in a Microsoft Excel spreadsheet (Table 1) and exported for statistical analysis.

Statistical Analysis

Data were tabulated in Microsoft Excel 365 and analyzed using IBM SPSS Statistics version 23. Descriptive statistics were calculated, and the results were presented in tables and graphs.

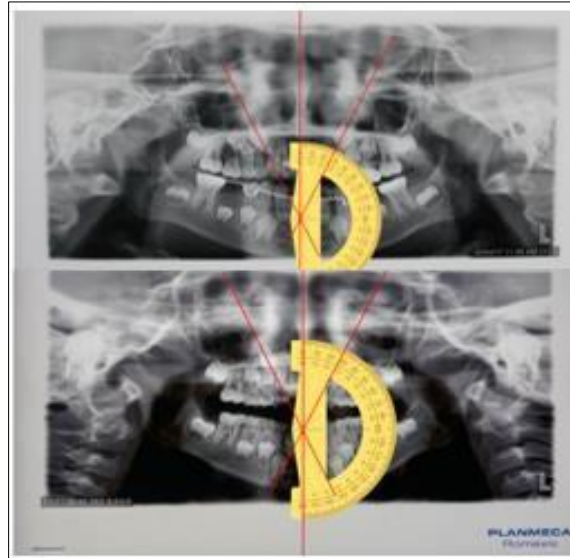


Figure 2: Angular assessment of the eruption path of permanent maxillary canines according to the Ericson and Kurol method. The angle (α) was measured between the long axis of the canine and the facial midline on panoramic radiographs

RX	EDAD	GÉNERO	VÍA DE ERUPCIÓN			
			1. $\alpha < 20^\circ$	2. $20^\circ - 40^\circ$	3. $\alpha > 40^\circ$	
			1	A	2	A
1	9	1	2	35	3	40
2	10	1	2	35	2	39
3	8	2	3	52	3	52
4	9	2	2	21	2	21
5	9	1	1	19	2	27
6	10	1	2	25	2	28
7	9	1	1	15	1	17
8	8	2	2	26	2	26
9	10	2	2	25	2	30
10	9	1	2	24	2	24
11	9	2	2	26	2	24
12	9	1	2	23	2	24
13	8	2	2	26	2	25
14	8	1	2	26	2	27
15	10	1	1	15	2	27
16	10	2	2	25	2	26
17	9	2	2	26	1	2
18	8	2	1	13	1	20
19	10	1	2	24	1	17

Table 1: Data collection sheet used for recording demographic and radiographic variables

RESULTS

A total of 170 panoramic radiographs met the inclusion criteria and were analyzed. Of these, 92 (54.1%) corresponded to male patients and 78 (45.9%) to female patients. Regarding age distribution, the highest frequency among males was observed at 9 years of age ($n = 47$), whereas the highest frequency among females was observed at 8 years of age ($n = 40$). The distribution

of the study sample according to age and sex is presented in Table 2 and Figure 3.

Categorical variables were summarized using absolute frequencies and percentages. Continuous variables were described using means and standard deviations. Cross-tabulation analyses were performed to evaluate the relationship between categorical variables.

Table 2: Distribution of the study sample according to age and sex

	EDAD	GÉNERO		Porcentaje	Total
		MASCULINO	FEMENINO		
	8	33	40	42.9	73
	9	47	26	42.9	73
	10	12	12	14.1	24
Total		92	78	(54.1 + 45.9) 100	170

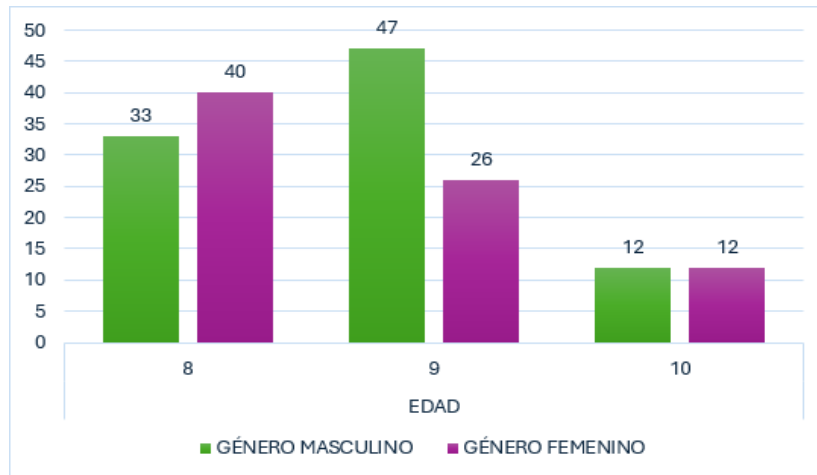


Figure 3: Distribution of the study sample according to age and sex

Consistent with previous reports indicating a higher prevalence of ectopic eruption paths among females, the $\alpha = 21^{\circ}$ – 40° angulation category (Type II) was the most frequently observed in this study,

accounting for 106 of the 170 panoramic radiographs evaluated (62.4%). The distribution of angulation categories according to sex is shown in Table 3 and Figure 4.

Table 3: Distribution of maxillary canine eruption paths according to sex

Angulación α		Frecuencia	Porcentaje	Porcentaje	Porcentaje
				válido	acumulado
Angulación α	0-20	59	34.7	34.7	34.7
	21-40	106	62.4	62.4	97.1
	41-80	5	2.9	2.9	100.0
	Total	170	100.0	100.0	

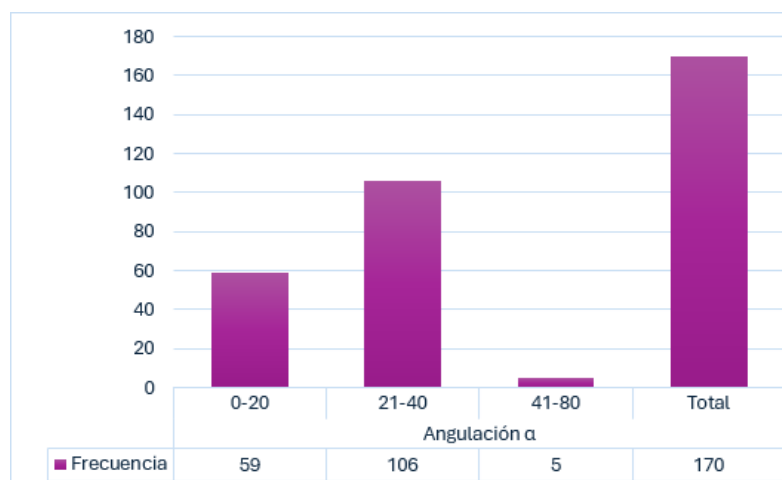


Figure 4: Eruption path distribution

Of the 106 radiographs in which a type II α angle was observed, 57.24% (54 radiographs)

corresponded to the female gender and 55.2% (52 radiographs) to the male gender (Table 4, Figure 5).

Table 4: Eruption pathway by gender

		GÉNERO		Total
		MASCULINO	FEMENINO	
VIA	0-20	37	22	59
	21-40	52	54	106
	41-80	3	2	5
Total		92	78	170

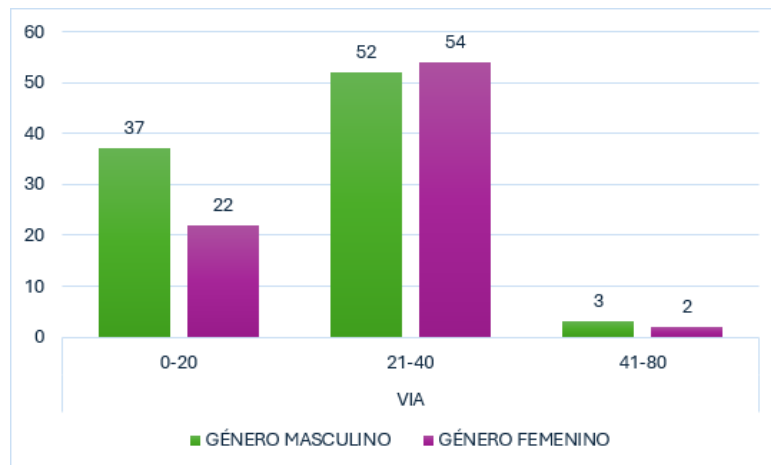


Figure 5: Eruption pathway by gender

The most frequently reported age of affected patients was 8 years (Table 5, Figure 6).

Table 5: Eruption pathway by age

		EDAD			Total
		8	9	10	
VIA	0-20	21	30	8	59
	21-40	50	41	15	106
	41-80	2	2	1	5
Total		73	73	24	170

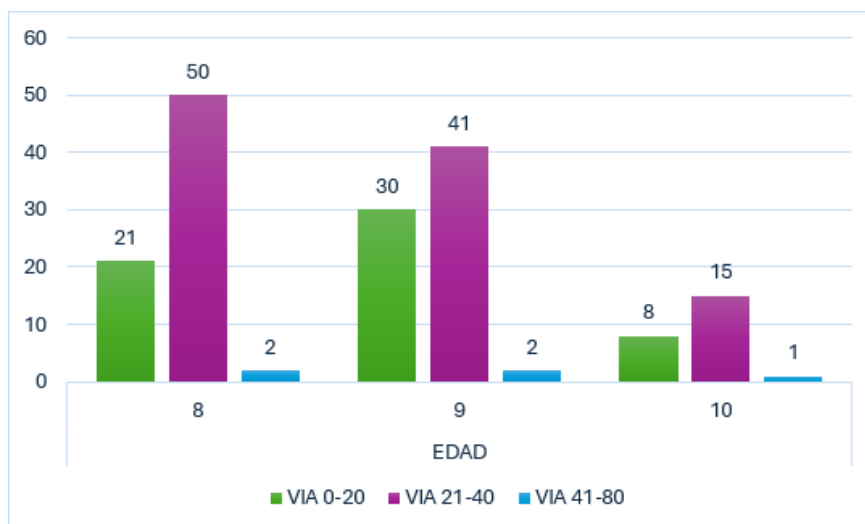


Figure 6: Eruption pathway by age

Based on the mean values obtained, the upper right quadrant (UR) showed 22.47° with a standard deviation of 8.665, while the upper left quadrant (UL) showed 23.51° with a standard deviation of 9.027. These

results indicate that the upper left side is the most affected in terms of eruption pathway (Table 6, Figure 7).

Table 6: Descriptive statistics for a sample

	Mínimo	Máximo	Media	Desv. Desviación	Desv. Error promedio	N
UR	3	80	22.47	8.665	0.665	170
UL	1	80	23.51	9.027	0.692	170

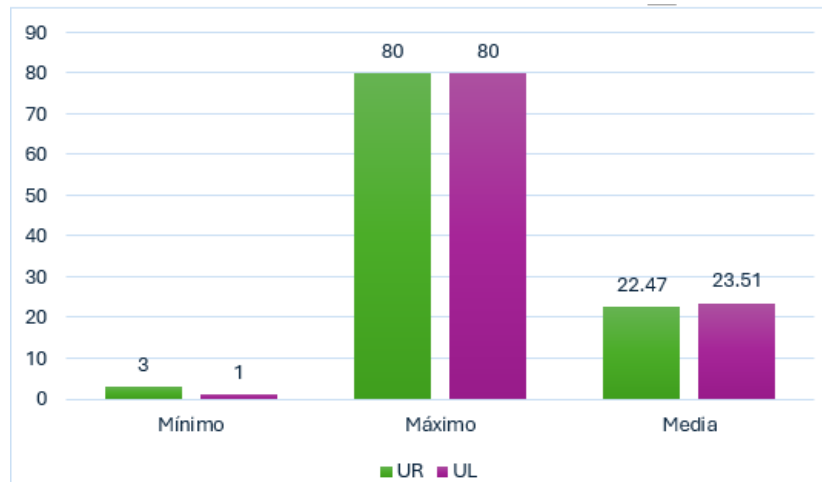


Figure 7: Descriptive statistics for a sample

Therefore, it was found that the most common eruption pathway of maxillary canines, assessed through panoramic radiography using the Ericson and Kuroi method in children aged 8 to 10 years attending the DEPeI pediatric service, ranges from 21° to 40° of angulation, corresponding to a pathway with a tendency toward impaction.

The female gender shows a greater tendency toward impaction of the maxillary canine eruption pathway. The most frequently affected quadrant with an ectopic eruption pathway was the upper left quadrant. The most frequent eruption pathway angulation of the maxillary canines was 22.47° for the upper right quadrant and 23.51° for the upper left quadrant (Figure 8).

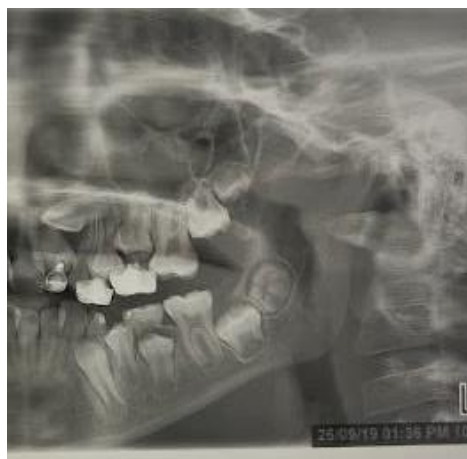

Figure 8: Female patient showing the upper left quadrant with the greatest complication in the eruption pathway

DISCUSSION

The present study was designed to evaluate the most common ectopic eruption pathway of maxillary canines in a pediatric sample of patients aged 8 to 10

years attending the pediatric dentistry clinic of the Faculty of Dentistry, DEPeI, during the period 2018–2022.

Several authors report that the prevalence of impaction is higher in females than in males, and that impacted canines tend to occur more frequently in a unilateral pattern (de Mendonça M *et al.*,2012) (Díaz-González L *et al.*,2022) (Izadikhah I *et al.*,2020) (Kim Y *et al.*,2012). In this study, a higher prevalence was observed in the upper left quadrant, as well as a greater proportion of affected females, reaching 57.24%.

Various authors, such as Anand K. Sajnani and Nigel M. King, agree that depending on the diagnosis and the timing of detection, an impacted maxillary canine may be managed through preventive or interceptive approaches, such as surgical exposure followed by spontaneous eruption or orthodontic traction, among others. These techniques are selected on an individual basis according to the patient's age, the severity of the condition, and/or the degree of impaction (Izadikhah I *et al.*,2020) (Margot R *et al.*,2020) (Sabour S *et al.*,2020) (Sajnani A *et al.*,2012).

According to the reviewed literature, most authors conclude that the main limitation in predicting maxillary canine impaction lies in the use of two-dimensional imaging (orthopantomography), as it may provide limited diagnostic accuracy. In contrast, three-dimensional radiographic studies are considered more precise and reliable for evaluating the eruption pathway (Alqerban A *et al.*,2016) (Shin J *et al.*,2022)

CONCLUSION

The identification of dental alterations in the early mixed dentition that are associated with canine impaction may be key for clinicians to achieve an early diagnosis of this condition. If canine displacement is detected in a timely manner, clinicians should focus on preventive methods to avoid impaction.

If the eruption of the maxillary canine deviates from the normal range or angulation, a more thorough examination or periodic monitoring may be required to prevent impaction.

It is suggested that radiographic examination be performed between 8 and 9 years of age to assess the eruption pathway and its tendency toward impaction.

REFERENCES

1. Alqerban, A., Storms, A. S., Voet, M., Fieuws, S., & Willems, G. (2016). Early prediction of maxillary canine impaction. *Dentomaxillofacial Radiology*, 45(3), Article 20150232. <https://doi.org/10.1259/dmfr.20150232>
2. Becker, A., & Chaushu, S. (2015). Etiology of maxillary canine impaction: A review. *American Journal of Orthodontics and Dentofacial Orthopedics*, 148(4), 557–567. <https://doi.org/10.1016/j.ajodo.2015.06.013>
3. de Mendonça, M. R., Verri, A. C., Martins, L. P., Fabre, A. F., & Cuoghi, O. A. (2012). Interceptive approach to treatment of impacted maxillary canines. *Journal of Craniofacial Surgery*, 23(1), e16–e19. <https://doi.org/10.1097/SCS.0b013e31824207bb>
4. Díaz-González, L., Guinot, F., García, C., Baltà, L., & Chung-Leng, I. (2022). Evaluation of the position of the permanent maxillary canine and its relationship to dental anomaly patterns in the paediatric patient. *European Journal of Paediatric Dentistry*, 23(4), 281–287. <https://doi.org/10.23804/ejpd.2022.23.04.05>
5. Izadikhah, I., Cao, D., Zhao, Z., & Yan, B. (2020). Different management approaches in impacted maxillary canines: An overview on current trends and literature. *The Journal of Contemporary Dental Practice*, 21(3), 326–336.
6. Kim, Y., Hyun, H. K., & Jang, K. T. (2012). The position of maxillary canine impactions and factors influencing root resorption of adjacent teeth in a Korean population. *European Journal of Orthodontics*, 34, 302–306. <https://doi.org/10.1093/ejo/ejr002>
7. Margot, R., Maria, C. L., Ali, A., Annouschka, L., Anna, V., & Guy, W. (2020). Prediction of maxillary canine impaction based on panoramic radiographs. *Clinical and Experimental Dental Research*, 6(1), 44–50. <https://doi.org/10.1002/cre2.246>
8. Sabour, S., & Vahid Dastjerdi, E. (2012). Early prediction of maxillary canine impaction from panoramic radiographs. *American Journal of Orthodontics and Dentofacial Orthopedics*, 142(4), 428–429. <https://doi.org/10.1016/j.ajodo.2012.08.010>
9. Sajnani, A. K., & King, N. M. (2012). Early prediction of maxillary canine impaction from panoramic radiographs. *American Journal of Orthodontics and Dentofacial Orthopedics*, 142(1), 45–51. <https://doi.org/10.1016/j.ajodo.2012.02.021>
10. Shin, J. H., Oh, S., Kim, H., Lee, E., Lee, S. M., Ko, C. C., & Kim, Y. I. (2022). Prediction of maxillary canine impaction using eruption pathway and angular measurement on panoramic radiographs. *The Angle Orthodontist*, 92(1), 18–26. <https://doi.org/10.2319/030121-164.1>