

# Endosonographic Morphological Predictors of Malignancy in Pancreaticobiliary Lesions: A Retrospective Real-World EUS Cohort Study

Addajou Tarik<sup>1\*</sup>, Benhamdane Ahlame<sup>1</sup>, Mrabti Samir<sup>1</sup>, Amine Meriem<sup>1</sup>, Elkoti Ilham<sup>1</sup>, Rouibaa Fedoua<sup>1</sup>, Seddik Hassan<sup>1</sup><sup>1</sup>Department of Digestive Endoscopy, Mohammed V Military Hospital, Rabat, MoroccoDOI: <https://doi.org/10.36347/sjams.2026.v14i06.013>

| Received: 19.04.2026 | Accepted: 01.06.2026 | Published: 11.06.2026

\*Corresponding author: Addajou Tarik

Department of Digestive Endoscopy, Mohammed V Military Hospital, Rabat, Morocco

## Abstract

## Original Research Article

**Background:** Endoscopic ultrasound (EUS) plays a crucial role in assessing pancreaticobiliary lesions and facilitating tissue sampling when there is a concern for malignancy. Nonetheless, the clinical significance of the morphological features reported during EUS in real-world patient populations continues to be important. **Aim:** This study aims to identify EUS morphological indicators that can predict pathology-confirmed malignancy in patients undergoing pancreaticobiliary EUS. **Methods:** We conducted a retrospective analysis of 129 consecutive patients from a prospectively maintained EUS database. The main outcome we focused on was malignancy confirmed by pathology. The EUS variables investigated included the detection of pancreatic lesions, the presence of solid masses, irregular shapes, heterogeneous appearances, signs of vascular involvement, invasion of veins or arteries, lymph node involvement, dilation of the pancreatic duct, and lesions exceeding 30 mm in size. We evaluated associations using Fisher's exact test and calculated odds ratios (OR) along with 95% confidence intervals (CI). A streamlined multivariable logistic regression model was developed using the most significant EUS predictors, and we assessed its discrimination capability through the area under the ROC curve (AUC). **Results:** Malignancy was identified in 28/129 patients (21.7%). The strongest univariate predictors were irregular contours (OR 17.52, 95% CI 5.95-51.60,  $p < 0.001$ ), vascular invasion (OR 15.49, 95% CI 5.32-45.10,  $p < 0.001$ ), venous invasion (OR 14.40, 95% CI 4.47-46.39,  $p < 0.001$ ), heterogeneous aspect (OR 13.82, 95% CI 3.91-48.87,  $p < 0.001$ ), solid pancreatic mass (OR 9.10, 95% CI 3.35-24.75,  $p < 0.001$ ), and lesion size  $>30$  mm (OR 5.89, 95% CI 2.40-14.45,  $p < 0.001$ ). In multivariable analysis, irregular contours (adjusted OR 9.70, 95% CI 3.03-31.05,  $p < 0.001$ ) and vascular invasion (adjusted OR 5.66, 95% CI 1.70-18.83,  $p = 0.005$ ) remained independent predictors. The model achieved an AUC of 0.85. **Conclusion:** Simple EUS morphological features, particularly irregular contours and vascular invasion, strongly predict pancreaticobiliary malignancy. Structured reporting of these findings may improve risk stratification and guide EUS-guided tissue acquisition. **Keywords:** Endoscopic ultrasound, Pancreaticobiliary malignancy, Morphological predictors, Irregular contours, Vascular invasion, Risk stratification.

**Copyright © 2026 The Author(s):** This is an open-access article distributed under the terms of the Creative Commons Attribution 4.0 International License (CC BY-NC 4.0) which permits unrestricted use, distribution, and reproduction in any medium for non-commercial use provided the original author and source are credited.

## INTRODUCTION

Pancreaticobiliary malignancies remain diagnostically challenging because symptoms are often non-specific and cross-sectional imaging may fail to fully characterize small or infiltrative lesions. Accurate risk stratification is essential because tissue confirmation and staging directly influence therapeutic decisions.

EUS provides high-resolution imaging of the pancreas and biliary region and is widely used to detect, characterize, and sample pancreatic solid lesions [1-5]. Current clinical guidelines support EUS-guided

sampling when pathological confirmation is required, particularly for solid pancreatic masses [3-6].

Beyond tissue acquisition, EUS morphology itself may provide valuable diagnostic information. Pancreatic adenocarcinoma is commonly described as a solid, hypoechoic or heterogeneous lesion with irregular borders, and locally advanced lesions may show vascular involvement [1,2,7,8]. However, the magnitude of association between individual EUS morphological features and malignancy may vary across real-world practice settings.

The aim of this study was to identify EUS morphological predictors of malignancy in a real-world pancreaticobiliary EUS cohort and to evaluate the discriminatory performance of a simple morphology-based model.

## METHODS

### Study design and population

We performed a retrospective analysis of a prospectively maintained single-center EUS database. All consecutive patients who underwent pancreaticobiliary EUS and had available pathology data in the registry were included.

### Outcome definition

The primary outcome was pathology-defined malignancy. Malignant diagnoses included adenocarcinoma, cholangiocarcinoma, ampullary adenocarcinoma, neuroendocrine tumor, GIST, and other carcinoma-type diagnoses documented in the pathology field.

### EUS morphological variables

The following EUS morphological variables were extracted from the database: pancreatic lesion detected, solid pancreatic mass, irregular contours, heterogeneous aspect, vascular invasion, venous invasion, arterial invasion, lymph nodes, pancreatic duct

dilation, and lesion size >30 mm. Vascular invasion was defined as either venous or arterial invasion recorded in the EUS report.

### Statistical analysis

Categorical variables were compared using Fisher's exact test. Results are presented as ORs with 95% CIs and p-values. A multivariable logistic regression model was constructed using two clinically relevant high-strength predictors: irregular contours and vascular invasion. Model discrimination was assessed with the AUC. Analyses were exploratory and should be interpreted in light of the retrospective design and sample size.

## RESULTS

### Study population

A total of 129 patients were included. Malignancy was identified in 28 patients (21.7%), while 101 patients (78.3%) had non-malignant or non-diagnostic pathology.

### Univariate EUS morphological predictors

Several EUS features were strongly associated with malignancy (Table 1). The highest ORs were observed for irregular contours, vascular invasion, venous invasion, heterogeneous aspect, solid pancreatic mass, and lesion size >30 mm.

**Table 1: Univariate analysis of EUS morphological predictors of malignancy.**

EUS feature	Feature present	Malignant with feature	OR	95% CI	p-value
Irregular contours	44/129	23/44	17.52	5.95-51.60	<0.001
Vascular invasion	22/129	15/22	15.49	5.32-45.10	<0.001
Venous invasion	17/129	12/17	14.40	4.47-46.39	<0.001
Arterial invasion	13/129	9/13	11.49	3.21-41.16	<0.001
Heterogeneous aspect	63/129	25/63	13.82	3.91-48.87	<0.001
Solid pancreatic mass	51/129	22/51	9.10	3.35-24.75	<0.001
Lesion size >30 mm	38/129	17/38	5.89	2.40-14.45	<0.001
Pancreatic lesion detected	83/129	25/83	6.18	1.75-21.80	0.002
Lymph nodes	36/129	12/36	2.41	1.00-5.79	0.058
Pancreatic duct dilation	10/129	2/10	0.89	0.18-4.47	1.000

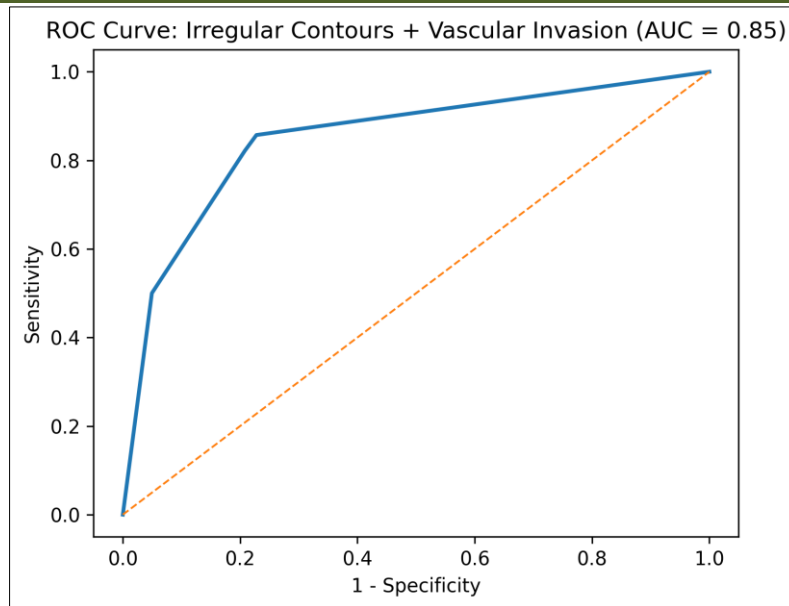
### Multivariable model

In the multivariable model, irregular contours and vascular invasion remained independent predictors

of malignancy. The model achieved an AUC of 0.85, indicating good discrimination.

**Table 2: Multivariable logistic regression model**

Predictor	Adjusted OR	95% CI	p-value
Irregular contours	9.70	3.03-31.05	<0.001
Vascular invasion	5.66	1.70-18.83	0.005



**Figure 1. ROC curve of the multivariable model using irregular contours and vascular invasion (AUC = 0.85)**

## DISCUSSION

This study demonstrates that routinely reported EUS morphological features are strongly associated with pancreaticobiliary malignancy. In this real-world cohort, irregular contours, vascular invasion, venous invasion, arterial invasion, heterogeneous aspect, solid pancreatic mass, and lesion size >30 mm were all significantly associated with malignant pathology. These findings support the clinical value of structured EUS morphology reporting.

The strongest independent predictors were irregular contours and vascular invasion. Irregular contours likely reflect infiltrative tumor behavior and loss of the normal interface between the lesion and surrounding pancreatic tissue. This is concordant with the typical EUS appearance of pancreatic adenocarcinoma, which is often described as a heterogeneous or hypoechoic solid mass with irregular borders [1,2].

Vascular invasion was also independently associated with malignancy. This finding is clinically important because vascular involvement is a major determinant of tumor stage, resectability, and treatment strategy [7,8]. Previous meta-analyses have shown that EUS can provide useful information for vascular invasion assessment in pancreatic cancer, particularly because of its high spatial resolution and close proximity to peripancreatic vessels [7,8]. In our cohort, patients with vascular invasion had a markedly higher malignancy rate, supporting its role as a high-risk EUS feature.

Solid pancreatic mass and heterogeneous aspect were highly significant in univariate analysis but were not retained in the final parsimonious model. This is

likely related to collinearity between morphological descriptors: malignant tumors often share multiple features, including solid morphology, heterogeneous texture, irregular borders, and invasion. From a practical perspective, irregular contours and vascular invasion may capture the most discriminative information among these correlated features.

Lesion size >30 mm was also strongly associated with malignancy. Larger lesions are more likely to show invasive behavior and may be detected after longer clinical evolution. However, size alone should not be interpreted as a substitute for morphology because small pancreatic cancers may also be malignant and clinically relevant [1].

Lymph nodes showed borderline significance in this dataset. This is clinically plausible because lymphadenopathy can occur in both malignant and inflammatory conditions. Therefore, nodal morphology alone may be less specific than tumor margin irregularity or vascular invasion. EUS-guided sampling of lymph nodes may still be useful when the result is expected to change staging or management [5,6].

The two-variable model combining irregular contours and vascular invasion achieved an AUC of 0.85, indicating good discrimination. This supports the concept that EUS morphology is not merely descriptive but predictive. A structured reporting template incorporating these features could help select patients for immediate EUS-guided tissue acquisition, especially when pathology confirmation is needed [3-6].

This study has limitations. It was retrospective and single-center, with a limited number of malignant events. EUS interpretation is operator-dependent, and

some variables may have been incompletely or heterogeneously recorded. The multivariable model was intentionally parsimonious to reduce overfitting, but external validation in larger prospective cohorts is required before clinical implementation.

## CONCLUSION

EUS morphological features are powerful predictors of pancreaticobiliary malignancy. In this cohort, irregular contours and vascular invasion were the strongest independent predictors, with a combined model AUC of 0.85. Structured assessment of these features may improve malignancy risk stratification and guide EUS-guided tissue acquisition.

## REFERENCES

1. Kitano M, Yoshida T, Itonaga M, Tamura T, Hatamaru K, Yamashita Y. Impact of endoscopic ultrasonography on diagnosis of pancreatic cancer. *Journal of Gastroenterology*. 2019;54(1):19-32. doi:10.1007/s00535-018-1519-2.
2. Yousaf MN, Chaudhary FS, Ehsan A, *et al.*, Endoscopic ultrasound and the management of pancreatic cancer. *BMJ Open Gastroenterology*. 2020;7: e000408. doi:10.1136/bmjgast-2020-000408.
3. ASGE Standards of Practice Committee; Machicado JD, Sheth SG, Chalhoub JM, *et al.*, American Society for Gastrointestinal Endoscopy guideline on the role of endoscopy in the diagnosis and management of solid pancreatic masses: summary and recommendations. *Gastrointestinal Endoscopy*. 2024;100(5):786-796. doi:10.1016/j.gie.2024.06.002.
4. ASGE Standards of Practice Committee; Machicado JD, Sheth SG, Chalhoub JM, *et al.*, American Society for Gastrointestinal Endoscopy guideline on role of endoscopy in the diagnosis and management of solid pancreatic masses: methodology and review of evidence. *Gastrointestinal Endoscopy*. 2024;100(5):e1-e78. doi:10.1016/j.gie.2024.06.003.
5. Dumonceau JM, Deprez PH, Jenssen C, *et al.*, Indications, results, and clinical impact of endoscopic ultrasound-guided sampling in gastroenterology: European Society of Gastrointestinal Endoscopy Clinical Guideline - updated January 2017. *Endoscopy*. 2017;49(7):695-714. doi:10.1055/s-0043-109021.
6. Polkowski M, Jenssen C, Kaye P, *et al.*, technical aspects of endoscopic ultrasound-guided sampling in gastroenterology: European Society of Gastrointestinal Endoscopy Technical Guideline - March 2017. *Endoscopy*. 2017;49(10):989-1006. doi:10.1055/s-0043-119219.
7. Puli SR, Singh S, Hagedorn CH, Reddy J, Olyae M. Diagnostic accuracy of EUS for vascular invasion in pancreatic and periampullary cancers: a meta-analysis and systematic review. *Gastrointestinal Endoscopy*. 2007;65(6):788-797.
8. Li JH, He R, Li YM, Cao G, Ma QY, Yang WB. Endoscopic ultrasonography for tumor node staging and vascular invasion in pancreatic cancer: a meta-analysis. *Digestive Surgery*. 2014;31(4-5):297-305.
9. Chung MJ, Park SW, Kim SH, *et al.*, Clinical and Technical Guideline for Endoscopic Ultrasound-guided Tissue Acquisition of Pancreatic Solid Tumor: Korean Society of Gastrointestinal Endoscopy. *Clinical Endoscopy*. 2021;54(2):161-181. doi:10.5946/ce.2021.069.
10. Chen G, Liu S, Zhao Y, Dai M, Zhang T. Diagnostic accuracy of endoscopic ultrasound-guided fine-needle aspiration for pancreatic cancer: a meta-analysis. *Pancreatology*. 2013;13(3):298-304. doi:10.1016/j.pan.2013.01.013.
11. Hewitt MJ, McPhail MJW, Possamai L, Dhar A, Vlavianos P, Monahan KJ. EUS-guided FNA for diagnosis of solid pancreatic neoplasms: a meta-analysis. *Gastrointestinal Endoscopy*. 2012;75(2):319-331.
12. Wang KX, Ben QW, Jin ZD, *et al.*, Assessment of morbidity and mortality associated with EUS-guided FNA: a systematic review. *Gastrointestinal Endoscopy*. 2011;73(2):283-290.