Scholars Journal of Medical Case Reports
Abbreviated Key Title: Sch J Med Case Rep
ISSN 2347-9507 (Print) | ISSN 2347-6559 (Online)
Journal homepage: https://saspublishers.com

OPEN ACCESS

Surgery

Extensive Pharyngolaryngeal Hemangioma with Deep Cervical Space Involvement in an Adult: A Case Report

Dr Zineb Berdi[1*], Dr Zakaria El Hafi[1], Dr Zakaria Arkoubi[1], Pr. Razika Bencheikh[1], Pr. Mohamed Anass Benbouzid[1], Pr. Leila Essakalli[1]

[1]Department of ENT and Head and Neck Surgery – Specialty Hospital / Ibn Sina University Hospital, Rabat, Morocco; Faculty of Medicine and Pharmacy / Mohammed V University, Rabat, Morocco

DOI: https://doi.org/10.36347/sjmcr.2026.v14i11.090 | **Received:** 22.08.2026 | **Accepted:** 25.10.2026 | **Published:** 23.11.2026

***Corresponding author:** Dr Zineb Berdi
Department of ENT and Head and Neck Surgery – Specialty Hospital / Ibn Sina University Hospital, Rabat, Morocco; Faculty of Medicine and Pharmacy / Mohammed V University, Rabat, Morocco

Abstract | **Case Report**

Pharyngolaryngeal hemangioma in adults is a rare benign vascular tumor whose progressive symptoms may delay diagnosis. We report the case of a 43-year-old man with no significant medical history, managed in 2016 for respiratory discomfort worsened in the supine position, dysphonia with a muffled voice, partial dysphagia for solids, and a pharyngeal foreign body sensation. Oral examination revealed a bluish swelling lateralized to the left, narrowing the oropharyngeal lumen. Nasofibroscopy showed an exophytic, vascular-appearing mass extending to the hypopharynx. MRI showed an infiltrative naso-oro-pharyngo-laryngeal process measuring 108 x 48 x 53 mm, extending into the deep cervical spaces. The diagnosis was based on clinical and radiological findings, without biopsy because of the risk of hemorrhage. The patient was treated with propranolol from 2016, as laser and sclerotherapy were not available in our department, with a good clinical course and a decrease in lesion size on follow-up MRI in 2023, without any adverse effects, over a follow-up of 7 years. This case illustrates the value of propranolol as a therapeutic alternative in extensive adult forms when local treatments are not accessible.

Keywords: Hemangioma; pharynx; larynx; propranolol; beta-blockers; MRI.

Copyright © 2026 The Author(s): This is an open-access article distributed under the terms of the Creative Commons Attribution **4.0 International License (CC BY-NC 4.0)** which permits unrestricted use, distribution, and reproduction in any medium for non-commercial use provided the original author and source are credited.

INTRODUCTION

Hemangiomas are benign vascular tumors characterized by endothelial proliferation. Very common in infants, with a predilection for the cervicofacial region, they are rare in adults, particularly in the upper aerodigestive tract [5]. The pharyngolaryngeal location is exceptional and carries a risk of airway compromise, with diagnostic difficulties related to slow progression and nonspecific symptoms. Management is not consensual: observation, surgery, laser, sclerotherapy, embolization and, more recently, medical treatment with beta-blockers [1,5]. We report a case of extensive pharyngolaryngeal hemangioma in an adult, treated with propranolol with a favorable course over 7 years.

CASE REPORT

A 43-year-old man with no significant medical history was managed in 2016 for respiratory discomfort worsened in the supine position, dysphonia with a muffled voice, partial dysphagia for solids, and a foreign body sensation with pharyngeal discomfort.

Oral examination revealed a pharyngeal swelling lateralized to the left, bluish in appearance, narrowing the oropharyngeal lumen. Nasofibroscopy showed an exophytic mass of vascular appearance extending to the hypopharynx.

Cervicofacial MRI showed an infiltrative naso-oro-pharyngo-laryngeal process measuring 108 x 48 x 53 mm, extending into the deep cervical spaces, notably involving the parapharyngeal, pterygoid and prevertebral regions, as well as the tonsillar, lingual and hypopharyngeal regions. The parotid and submandibular glands were spared. There was no cervical lymphadenopathy.

Biopsy was not performed because of the risk of hemorrhage associated with sampling an extensive vascular lesion. The diagnosis of hemangioma was based on the clinical appearance and MRI findings.

Given the extent of the lesion and the unavailability of laser and sclerotherapy in our

department, medical treatment with propranolol was started in 2016, after normal cardiovascular examination and electrocardiogram. The treatment was introduced gradually, at a dose of 40 mg/day during the first week, then progressively increased to 120 mg/day. The patient experienced no adverse effects. The clinical course was favorable, with clinical and nasofibroscopic follow-up. Follow-up MRI performed in August 2023 showed a decrease in the size of the lesion compared with the previous examination. At the last visit in 2023, treatment was still ongoing. The patient was subsequently lost to follow-up, for a total follow-up of 7 years.

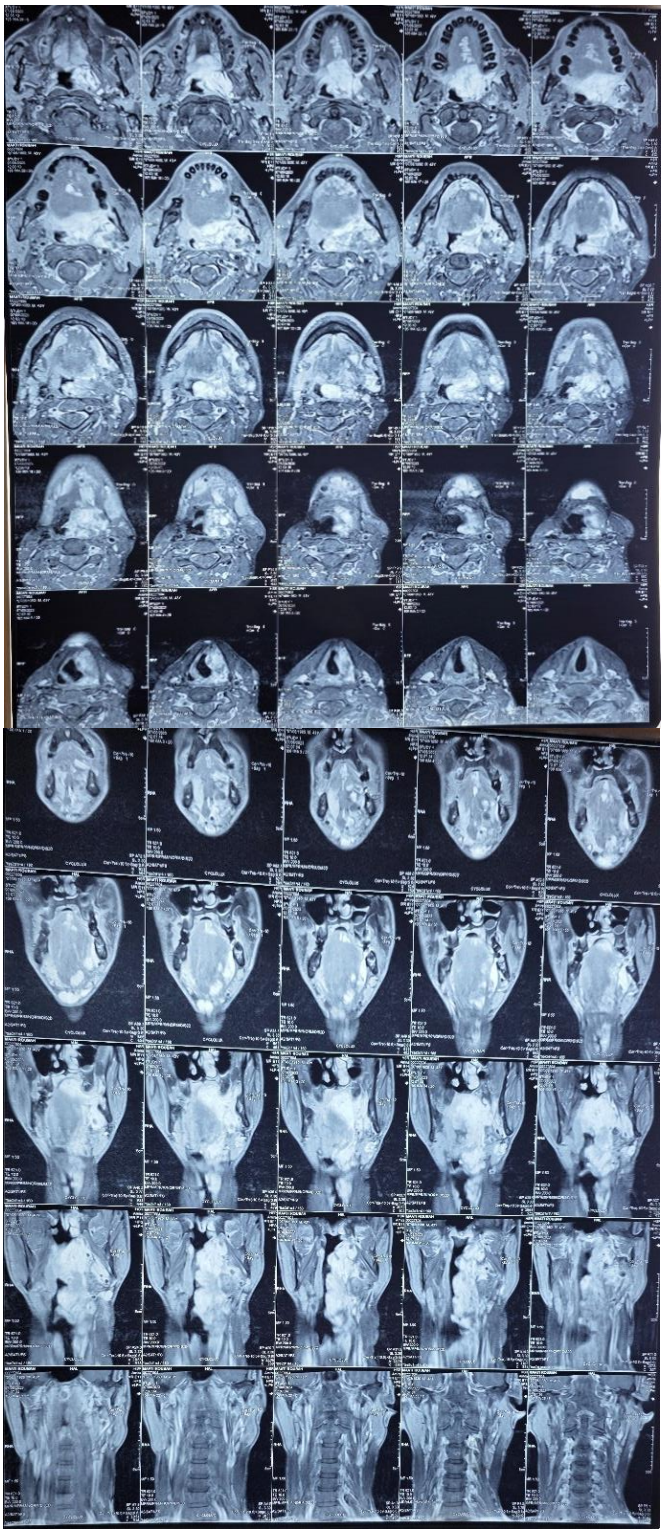

Figure 1: Cervicofacial MRI: infiltrative naso-oro-pharyngo-laryngeal process extending into the deep cervical spaces

DISCUSSION

Hemangioma is a benign vascular tumor resulting from endothelial proliferation. It is very common in infants and children, but its occurrence or persistence in adults is rare, and the pharyngolaryngeal location is even rarer [5]. Our case stands out for the patient's age, the exceptional extent of the lesion (108 x 48 x 53 mm), involving the nasopharynx, oropharynx and hypopharynx with deep neck space involvement, and for the duration of follow-up under medical treatment.

Clinically, symptoms are nonspecific and slowly progressive: respiratory discomfort, dysphonia with a muffled voice, dysphagia and a foreign body sensation. The positional nature of the dyspnea, worsened in the supine position, should raise concern for airway obstruction and warrants an assessment of laryngeal patency. The bluish appearance of the swelling on oral examination and the vascular appearance on nasofibroscopy are major diagnostic clues. Deep, submucosal lesions often appear bluish [9].

The differential diagnosis includes vascular malformations, particularly venous ones, lymphangiomas, minor salivary gland tumors, lymphomas and sarcomas [5,9]. The distinction between vascular tumor and malformation relies on the ISSVA classification, revised in 2018, which separates vascular tumors, characterized by endothelial proliferation, from vascular malformations, which are defects of vascular morphogenesis [8,9]. This distinction is particularly delicate in adults: most lesions formerly designated as "cavernous hemangiomas" are now reclassified as venous malformations [8,9]. Immunohistochemistry, notably the GLUT-1 marker, positive in infantile hemangiomas and negative in vascular malformations, is the reference tool to settle the question [9].

In our case, biopsy was not performed because of the risk of hemorrhage associated with sampling an extensive vascular lesion. The diagnosis therefore rests on clinical and imaging findings.

MRI is the reference examination for characterizing these lesions. It defines the extent, the relationship with adjacent structures and deep spaces, and guides the diagnosis through the signal on T2-weighted sequences and enhancement after injection [9]. In our case, it documented extension to the parapharyngeal, pterygoid, prevertebral, tonsillar, lingual and hypopharyngeal regions, with sparing of the salivary glands and absence of lymphadenopathy.

Therapeutic options are multiple: observation, corticosteroids, surgery, laser, sclerotherapy, embolization and medical treatment [5]. The choice depends on size, location, extent and functional impact. In extensive and deep forms such as ours, surgical excision carries a high hemorrhagic and functional risk, and local treatments (laser, sclerotherapy) cannot treat the entire lesion.

Since Leaute-Labreze *et al.,* described the regression of infantile hemangiomas under propranolol [1], confirmed by subsequent series [2] and then by a randomized controlled trial [3], beta-blockers have become the standard treatment for complicated infantile hemangiomas. The mechanism of action of propranolol is not fully elucidated. It combines an early vasoconstrictive effect, an intermediate inhibition of pro-angiogenic signals (VEGF, bFGF, matrix metalloproteinases MMP-2 and MMP-9) responsible for growth arrest, and a late induction of apoptosis of proliferating endothelial cells, leading to tumor regression [4].

Data in adults are much more limited and rely on isolated cases and small series, with variable results. In a prospective series of ten patients with capillary hemangioma of the head and neck, only one of the two adults responded to propranolol [6]. Conversely, a comparative trial in adults reported a mean volume reduction of more than 90% after 8 weeks of propranolol combined with sclerotherapy using sodium tetradecyl sulfate [7]. These heterogeneous results, obtained with different methodologies and in small hemangiomas, are not directly comparable to our case.

In our case, propranolol, introduced gradually after cardiovascular assessment, led to a good clinical course and a decrease in lesion size on follow-up MRI in 2023, with excellent tolerance over 7 years of follow-up. To our knowledge, a lesion this extensive in the adult pharyngolarynx with such prolonged follow-up under beta-blocker therapy is poorly documented. This case also illustrates the effectiveness of the medical approach which is noninvasive and inexpensive.

CONCLUSION

Pharyngolaryngeal hemangioma in adults is a rare entity, and the diagnosis should be considered in the presence of a bluish lesion of the upper aerodigestive tract associated with positional respiratory discomfort. MRI is essential to define its extent. Propranolol is a relevant noninvasive therapeutic option, particularly in extensive forms and when local treatments are not available. Further studies are needed to clarify its efficacy and the optimal duration of treatment in adults.

REFERENCES

1. Léauté-Labrèze C, Dumas de la Roque E, Hubiche T, Boralevi F, Thambo JB, Taïeb A. Propranolol for severe hemangiomas of infancy. N Engl J Med. 2008;358(24):2649-51. doi:10.1056/NEJMc0708819
2. Sans V, Dumas de la Roque E, Berge J, *et al.,*Propranolol for severe infantile hemangiomas:

follow-up report. Pediatrics. 2009. doi:10.1542/peds.2008-3458

3. Léauté-Labrèze C, Hoeger P, Mazereeuw-Hautier J, *et al.,*A randomized, controlled trial of oral propranolol in infantile hemangioma. N Engl J Med. 2015;372(8):735-46.
4. Storch CH, Hoeger PH. Propranolol for infantile haemangiomas: insights into the molecular mechanisms of action. Br J Dermatol. 2010;163(2):269-74.
5. Buckmiller LM, Richter GT, Suen JY. Diagnosis and management of hemangiomas and vascular malformations of the head and neck. Oral Dis. 2010;16(5):405-18.
6. Dimaguila GAC, Samson ES. Oral propranolol therapy for benign capillary hemangiomas in a series of adult and pediatric patients. Philipp J Otolaryngol Head Neck Surg. 2017;32(2):34-7.
7. Panditray S, Acharya S, Prusty N, Dany SS. Management of head and neck hemangiomas in adults: oral propranolol versus oral itraconazole in conjugation with injection sodium tetradecyl sulphate. Indian J Otolaryngol Head Neck Surg. 2019. doi:10.1007/s12070-018-1410-8
8. International Society for the Study of Vascular Anomalies. ISSVA Classification of Vascular Anomalies. 2018. Available at: issva.org/classification
9. Brahmbhatt AN, Skalski KA, Bhatt AA. Vascular lesions of the head and neck: an update on classification and imaging review. Insights Imaging. 2020 Feb 7;11(1):19. doi: 10.1186/s13244-019-0818-3. PMID: 32034537; PMCID: PMC7007481.