Scholars Journal of Medical Case Reports
Abbreviated Key Title: Sch J Med Case Rep
ISSN 2347-9507 (Print) | ISSN 2347-6559 (Online)
Journal homepage: https://saspublishers.com

OPEN ACCESS

Surgery

Laryngeal Burkitt Lymphoma in an Elderly Patient: A Rare Presentation with Life-Threatening Airway Obstruction

Z. Berdi[1*], Z. El Hafi[1], R. Bencheikh[1], M.A. Benbouzid[1], L. Essakalli[1]

[1]Department of ENT and Head and Neck Surgery, Specialty Hospital / Ibn Sina University Hospital, Rabat, Morocco; Faculty of Medicine and Pharmacy / Mohammed V University, Rabat, Morocco

DOI: https://doi.org/10.36347/sjmcr.2026.v14i11.092 | **Received:** 19.08.2026 | **Accepted:** 24.10.2026 | **Published:** 23.11.2026

***Corresponding author:** Z. Berdi
Department of ENT and Head and Neck Surgery, Specialty Hospital / Ibn Sina University Hospital, Rabat, Morocco; Faculty of Medicine and Pharmacy / Mohammed V University, Rabat, Morocco

Abstract | **Case Report**

Introduction. Primary lymphomas of the larynx are rare and are most often low-grade B-cell lymphomas or diffuse large B-cell lymphomas. Laryngeal Burkitt lymphoma is exceptional, particularly in the elderly. ***Case presentation.*** We report the case of a 77-year-old patient with type 2 diabetes and hypertension who presented with a six-month history of progressively worsening upper dysphagia associated with a right lateral neck mass. Cervical computed tomography showed a laryngeal lesion centered on the right vocal fold. Acute inspiratory dyspnea required an emergency tracheostomy with biopsy. Pathological and immunohistochemical examination (CD20+, CD10+, BCL6−, BCL2−, Ki-67 close to 100%) together with a MYC rearrangement led to the diagnosis of Burkitt lymphoma. The staging work-up (bone marrow aspirate, flow cytometric immunophenotyping of the bone marrow and cerebrospinal fluid, thoraco-abdomino-pelvic CT) found no involvement, but the bone marrow aspirate showed numerous images of hemophagocytosis. The patient received immunochemotherapy combining rituximab, cyclophosphamide, doxorubicin, vincristine, etoposide and prednisolone. The outcome allowed decannulation one month after the start of treatment, and the patient is currently in complete remission. ***Conclusion.*** A lymphoma should be considered in any rapidly progressing laryngeal mass in an elderly patient. A biopsy obtained at the time of the emergency airway procedure allows early diagnosis, and ENT-hematology collaboration determines the prognosis.

Keywords: Burkitt lymphoma; larynx; tracheostomy; elderly; MYC; hemophagocytosis.

Copyright © 2026 The Author(s): This is an open-access article distributed under the terms of the Creative Commons Attribution **4.0 International License (CC BY-NC 4.0)** which permits unrestricted use, distribution, and reproduction in any medium for non-commercial use provided the original author and source are credited.

INTRODUCTION

Lymphomas of the head and neck are the second most frequent extranodal site of non-Hodgkin lymphomas after the gastrointestinal tract. Within this region, involvement of the larynx is rare: lymphomas account for less than 1% of malignant laryngeal tumors, and the reported forms are mostly marginal zone B-cell lymphomas of MALT type and diffuse large B-cell lymphomas.

Burkitt lymphoma is an aggressive B-cell lymphoma characterized by a proliferation of medium-sized cells, a proliferation index close to 100%, and a rearrangement of the MYC gene, most often through translocation with an immunoglobulin gene [1,2]. It occurs in three variants: endemic, sporadic and immunodeficiency-associated. The sporadic form mainly affects children and young adults, but it can occur in the elderly, in whom it raises particular problems of therapeutic tolerance.

Laryngeal localization of Burkitt lymphoma is exceptional. We report a case revealed by acute respiratory distress, and we discuss the diagnostic difficulties, airway management and therapeutic options.

CASE PRESENTATION

We report the case of a 77-year-old male patient with type 2 diabetes treated with metformin and hypertension treated with amlodipine, who presented with a six-month history of progressively worsening upper dysphagia associated with a right lateral neck mass.

Cervical computed tomography revealed a laryngeal lesion centered on the right vocal fold. The course was marked by the onset of acute inspiratory dyspnea, which required an emergency tracheostomy, with biopsy of the laryngeal lesion during the same procedure.

Pathological examination, completed by immunohistochemical study, showed a lymphomatous proliferation expressing CD20 and CD10, without expression of BCL6 or BCL2, with a Ki-67 proliferation index close to 100%. Testing for a MYC gene rearrangement was positive. These findings were in favor of Burkitt lymphoma.

The patient was transferred to the hematology department for further management. The bone marrow aspirate showed numerous images of hemophagocytosis, without blast cells or malignant cells. Immunophenotyping of the bone marrow blood showed a polyclonal lymphocyte population at 17%, with a T-cell (CD3) subpopulation at 70% and a B-cell (CD19) subpopulation at 9%. Immunophenotyping of the cerebrospinal fluid showed neither a blast population nor a lymphoid population. Thoraco-abdomino-pelvic CT was normal. The pre-treatment work-up (hepatitis B and C serologies, HIV, TPHA-VDRL, EBV) and transthoracic echocardiography were normal.

Approximately two weeks after the tracheostomy, the patient received immunochemotherapy combining rituximab, cyclophosphamide, doxorubicin, vincristine, etoposide and prednisolone.

The outcome was favorable. At the one-month ENT follow-up visit, the rapid improvement allowed decannulation. To date, the patient is in complete remission. Follow-up is provided jointly by the ENT and hematology departments.

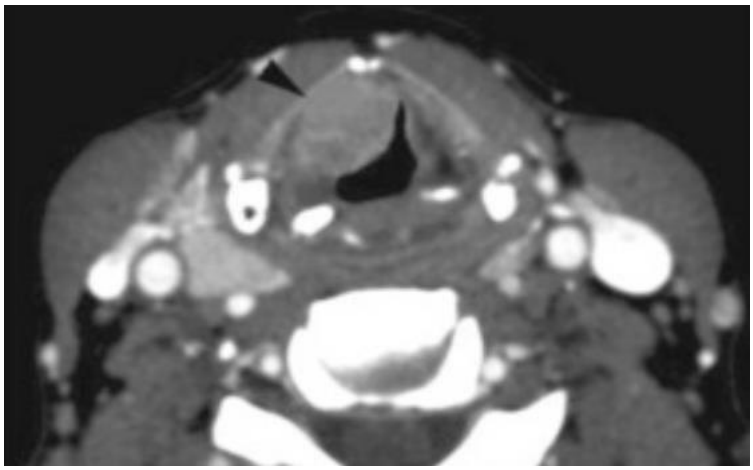

Figure 1: Cervical CT, laryngeal lesion centered on the right vocal fold

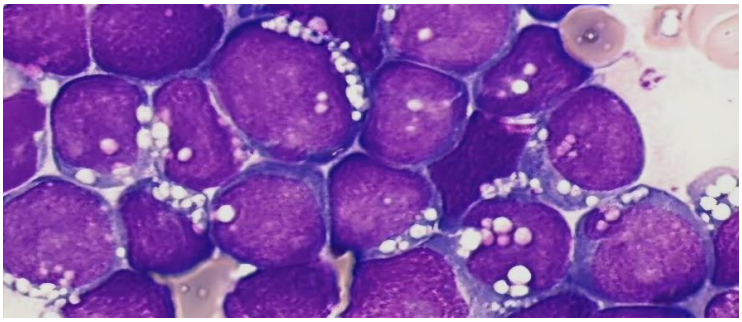

Figure 2: Histological and immunohistochemical appearance

DISCUSSION

Particular features of the case.

Several elements make this case noteworthy: the laryngeal localization of a Burkitt lymphoma, the age of the patient, the mode of presentation with a respiratory emergency requiring tracheostomy, and the presence of bone marrow hemophagocytosis without tumoral marrow involvement.

Clinical presentation and differential diagnosis.

Laryngeal lymphomas present with dysphonia, dysphagia, dyspnea or a neck mass, a nonspecific picture that is easily mistaken for squamous cell carcinoma, which is far more frequent at this age. In our patient, the progressive dysphagia and the lateral neck mass could have pointed toward an epithelial neoplasm. The rapid growth, which led to acute obstruction within six months, is on the other hand consistent with the very high kinetics of Burkitt lymphoma, whose doubling time is among the shortest of all human tumors. A rapidly progressing laryngeal mass in an elderly patient should therefore raise suspicion of lymphoma, and biopsy remains essential, with a fresh specimen or one fixed appropriately for immunohistochemistry and molecular studies.

Pathological diagnosis.

The diagnosis rests on morphology and phenotype. The profile found in our patient (CD20+, CD10+, BCL6−, BCL2−, Ki-67 close to 100%) corresponds to the appearance described in current classifications. The MYC rearrangement, present here, is a central element of the diagnosis [1-3]. The differential diagnosis includes diffuse large B-cell lymphoma, and above all high-grade lymphomas with MYC and BCL2 and/or BCL6 rearrangements (formerly "double-hit"). In our case, the absence of BCL2 and BCL6 expression argues against the latter hypothesis, but only testing for the corresponding rearrangements by FISH can formally exclude it.

Airway management.

The tracheostomy was performed as an emergency, and the biopsy was taken during the same procedure. This approach allowed a rapid diagnosis without delaying hematological management. It illustrates the role of the ENT surgeon in the first phase of these lymphomas with laryngeal localization: securing the airway, obtaining a usable specimen, then referring without delay. Decannulation was possible one month after the start of chemotherapy, thanks to the chemosensitivity of the tumor, which underlines that, in this situation, treatment of the disease is the main means of restoring laryngeal patency, unlike cicatricial stenoses or epithelial tumors.

Hemophagocytosis.

Our patient showed numerous images of hemophagocytosis on the bone marrow aspirate, without any detectable tumor cell in the marrow. B-cell lymphomas, particularly aggressive ones, can be accompanied by macrophage activation syndrome, with a guarded prognosis [4]. In our case, the additional laboratory data that would allow this diagnosis (ferritin, triglycerides, fibrinogen, cytopenias, fever, splenomegaly) are not available, and we therefore cannot conclude to an established hemophagocytic syndrome. Viral serologies, including EBV, were negative, which rules out a classic viral cause. The presence of bone marrow hemophagocytosis should nevertheless prompt, in practice, a systematic search for the criteria of macrophage activation syndrome in any aggressive lymphoma.

Staging work-up.

The bone marrow aspirate, bone marrow immunophenotyping, cerebrospinal fluid study and thoraco-abdomino-pelvic CT found no involvement, which is consistent with a localized form. Neuromeningeal involvement is a major risk in Burkitt lymphoma, and its assessment is systematic. A PET-CT could have completed this work-up.

Treatment in the elderly.

Treatment of Burkitt lymphoma relies on intensive immunochemotherapy protocols, combined with neuromeningeal prophylaxis and prevention of tumor lysis syndrome. These regimens are poorly tolerated in the elderly and in patients with comorbidities. Lower-intensity regimens, such as DA-EPOCH-R, have given good results in adults and in older patients [5]. In our 77-year-old patient with diabetes and hypertension, immunochemotherapy combining rituximab, cyclophosphamide, doxorubicin, vincristine, etoposide and prednisolone was chosen and led to complete remission. The choice of this regimen follows this logic of adaptation to age and comorbidities.

CONCLUSION

Laryngeal Burkitt lymphoma is an exceptional entity that can present with acute airway obstruction in the elderly. In any rapidly progressing laryngeal mass, a lymphoma should be considered, and an appropriate biopsy should be obtained at the time of the emergency airway procedure. The chemosensitivity of these tumors allows rapid decannulation. Close collaboration between ENT surgeons and hematologists, from diagnosis through follow-up, is essential.

Consent. The patient's consent was obtained for publication of this case.

Conflicts of interest. The authors declare no conflicts of interest.

REFERENCES

1. Swerdlow SH, Campo E, Harris NL, *et al.,* WHO Classification of Tumours of Haematopoietic and Lymphoid Tissues, revised 4th edition. Lyon: IARC; 2017.
2. Alaggio R, Amador C, Anagnostopoulou I, *et al.,*The 5th edition of the World Health Organization Classification of Haematolymphoid Tumours: Lymphoid Neoplasms. Leukemia. 2022;36(7):1720-1748.
3. Campo E, Jaffe ES, Cook JR, *et al.,*The International Consensus Classification of Mature Lymphoid Neoplasms. Blood. 2022;140(11):1229-1253.
4. Elghouat G, Karrati I, Nakhli R, Yahyaoui H, Chakour M, Sayagh S. Syndrome d'activation macrophagique révélant un lymphome hodgkinien : à propos d'un cas [Macrophage activation syndrome revealing Hodgkin lymphoma: a case report]. Annales de Biologie Clinique. 2021;79(4):345-348. https://doi.org/10.1684/abc.2021.1655
5. Dunleavy K, Pittaluga S, Shovlin M, *et al.,*Low-intensity therapy in adults with Burkitt's lymphoma. N Engl J Med. 2013;369(20):1915-1925.
6. Lymphome de Burkitt : Expérience du service de médecine interne et d'onco-hématologie du CHU HASSAN II de Fès. Thesis No. 039/25.