Scholars Journal of Medical Case Reports
Abbreviated Key Title: Sch J Med Case Rep
ISSN 2347-9507 (Print) | ISSN 2347-6559 (Online)
Journal homepage: https://saspublishers.com

OPEN ACCESS

Pathology

Malignant Basomelanocytic Tumour: A Pathological Diagnostic Pitfall. A Case Report

Chaimae Ben Omar[1*], Fouad Zouaidia[1], Sara El Ghaffouli[1], Habiba Kadiri[1], Nadia Cherradi[1] and Hafsa El Ouazzani[1]

[1]Department of Pathology HSR, Ibn Sina University Hospital Center, Mohammed V University in Rabat, Morocco

DOI: https://doi.org/10.36347/sjmcr.2026.v14i11.093 | **Received:** 15.09.2026 | **Accepted:** 20.11.2026 | **Published:** 23.11.2026

***Corresponding author:** Chaimae Ben Omar
Department of Pathology HSR, Ibn Sina University Hospital Center, Mohammed V University in Rabat, Morocco
E-mail: shymbo93@gmail.com

Abstract | **Case Report**

Baso-melanocytic lesions of the skin encompass a morphologically heterogeneous and terminologically confusing spectrum, extending from pigmented basal cell carcinoma harbouring benign colonizing melanocytes to genuine combined tumours in which a basal cell carcinoma and a melanoma coexist. Because these possibilities carry sharply divergent prognostic and therapeutic implications, their distinction is one of the more treacherous exercises in dermatopathology. We report the case of a 69-year-old man who presented with an ulcerated, exophytic nasal tumour that had been misdiagnosed as melanoma. This case illustrates a recurring diagnostic pitfall and underscores that the mere immunohistochemical detection of melanocytes within a basaloid tumour does not, in itself, establish a melanocytic malignancy.

Keywords: Basal cell carcinoma; basomelanocytic tumour; melanoma; immunohistochemistry; diagnostic pitfall; case report.

Copyright © 2026 The Author(s): This is an open-access article distributed under the terms of the Creative Commons Attribution **4.0 International License (CC BY-NC 4.0)** which permits unrestricted use, distribution, and reproduction in any medium for non-commercial use provided the original author and source are credited.

INTRODUCTION

The coexistence of epithelial and melanocytic populations within a single cutaneous neoplasm is uncommon. Despite the intimate physiological association of keratinocytes and melanocytes in the basal epidermis and the hair follicle, simultaneous malignant transformation of both lineages is genuinely rare [1]. Based on the tumour composition, these lesions have been organized into four categories that are now broadly agreed upon: collision tumours, in which two independent neoplasms abut while keeping distinct boundaries; combined tumours, composed of two phenotypically distinct yet intermingled malignant populations; colonized tumours, in which one neoplastic population permeates but remains confined within a second; and biphenotypic tumours, arising from a single precursor that undergoes divergent differentiation, the individual cells co-expressing both lineages [1–3]. These categories differ not in semantics alone but in biology and in management, and the morphological overlap among them is precisely what makes the distinction difficult. The initial biopsy in the present case, read as favouring melanoma, exemplifies this difficulty.

We describe a case of malignant basomelanocytic tumour of the nasal tip, to revisit the morphological and immunohistochemical reasoning by which melanocytic colonization is separated from a true biphenotypic malignancy.

CASE REPORT

A 69-year-old man was referred for an ulcerated and exophytic lesion of the tip of the nose that had enlarged progressively over several months. His medical history included Parkinson's disease and benign prostatic hyperplasia under treatment. Standard radiography of the facial skeleton showed a tumoral process occupying the nasal fossa. An initial incisional biopsy was interpreted at an outside assessment as favouring melanoma. The patient subsequently underwent surgical excision of the lesion, and the specimen was submitted to our department for histopathological examination.

On gross examination the excision specimen bore an ulcerated, exophytic lesion measuring 2 cm in its largest dimension, with irregular borders, a crusted yellowish surface and an erythematous peripheral base.

Histological sections showed a superficially ulcerated tumour composed of lobules and thick anastomosing cords of basaloid cells, focally surrounded by the clefting artefact (Figure 1A). The basaloid cells displayed marked cytonuclear atypia, and mitotic activity was brisk (Figure 1B). The proliferation was interrupted by haemorrhagic foci and contained microcystic spaces. The stroma alternated between dense fibrous and loose myxoid areas with an inflammatory component. No lymphovascular emboli and no perineural invasion were identified. The lateral and deep margins were clear.

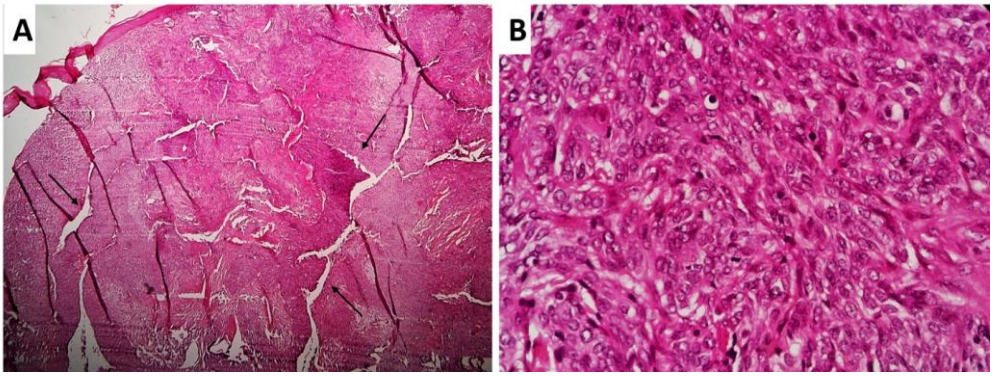

Figure 1: (A) Low-power view (haematoxylin–eosin, ×10): basaloid lobules and thick cords with peripheral stromal retraction (arrows). (B) Higher magnification (haematoxylin–eosin, ×40): basaloid cells with marked cytonuclear atypia

Immunohistochemistry demonstrated a biphasic phenotype combining basaloid epithelial and melanocytic elements. The basaloid epithelial component was strongly and diffusely immunoreactive for CK AE1/AE3, CK5/6 and p40 (Figure 2A, B), while the melanocytic elements expressed melanocytic markers such as Melan-A and HMB-45 (Figure 2C). SOX10 was diffusely positive in the tumour (Figure 2D). EMA and CK7 were negative. The melanocytic cells did not form distinct atypical nests or sheets and showed no autonomous junctional or dermal proliferation independent of the basaloid islands.

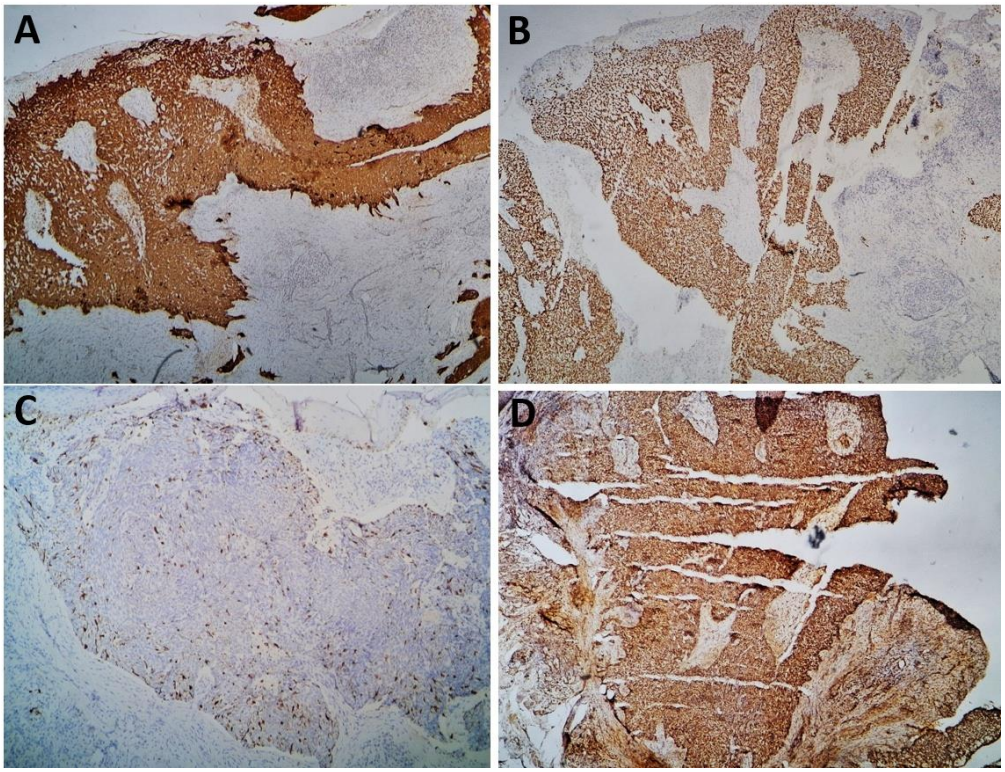

Figure 2: (A) CK AE1/AE3 and (B) p40 immunostains showing strong and diffuse labelling of the basaloid epithelial elements. (C) Melanocytic markers (Melan-A and HMB-45) highlighting the melanocytic elements. (D) Diffuse SOX10 expression in the tumour

The integration of a conventional basal cell carcinoma architecture, a diffuse basaloid immunophenotype (CK AE1/AE3, CK5/6, p40), and a melanocytic immunophenotype (Melan-A, HMB-45,

SOX10) supports the diagnosis of malignant basomelanocytic tumour.

DISCUSSION

The diagnostic difficulty embodied in this case stems from a single fact established three decades ago and confirmed repeatedly since: benign melanocytes are a normal constituent of basal cell carcinoma. In the systematic study by Florell and colleagues, every one of ten basal cell carcinomas examined was populated by dendritic melanocytes, situated either at the periphery of the tumour nests or distributed evenly throughout them; benign Langerhans cells were likewise present [4]. The corollary is operationally important: positivity for SOX10, Melan-A or HMB-45 within a basaloid tumour is the expected baseline state, not a marker of malignancy. Indeed, the pigmentation of pigmented basal cell carcinoma reflects both increased melanin and an increased number of these resident melanocytes, underscoring that a melanocytic presence is intrinsic to the tumour rather than a separate neoplasm [5]. What distinguished the malignant comparator in that same study was not the presence of melanocytes but their behaviour: a markedly higher density and, decisively, their arrangement in clusters of two or more cells, a configuration absent from ordinary basal cell carcinoma [4]. The same density-and-cytology threshold has since been reiterated as the operative criterion separating reactive colonizing melanocytes from a neoplastic melanocytic population [3].

It is this distinction, dispersed single dendritic cells versus dense atypical clusters, that anchors the interpretation of the present case. The melanocytic population here was dispersed, non-clustered and cytologically unremarkable, and it never escaped the confines of the basaloid islands to form an independent proliferation. The dominant neoplastic population was unambiguously keratinocytic, expressing CK AE1/AE3, CK5/6 and p40 in the architectural context (peripheral palisading and retraction clefts) of a basal cell carcinoma. Taken together these features place the lesion within the colonization category rather than among combined tumours.

The terminology deserves explicit attention because the title under which such cases are often filed can prejudge the diagnosis. The designation “malignant basomelanocytic tumour” was introduced for genuinely biphasic neoplasms: Erickson and colleagues first reported the entity under this designation [6], and Rodriguez and colleagues, who described two further cases under the same name, reported tumours in which some cells carried a keratinocytic phenotype (cytokeratins, p63) and others a melanocytic phenotype (HMB-45, MART-1, Melan-A, S100) [7]. The key point, frequently lost in casual usage, is that the two immunophenotypes mark two separate cell populations: in the original reports, no cell co-expressed both lineages, which is why the term “biphasic” is preferred to “biphenotypic” [8]. A truly biphenotypic tumour, one in which the same cell expresses both epithelial and melanocytic markers, ideally confirmed ultrastructurally by coexisting tonofilaments and premelanosomes, is exceptional; co-expression by a single cell is therefore not what defines the basomelanocytic tumour and, when apparently observed, demands scepticism and technical scrutiny [2]. Whether such combined tumours represent true divergent differentiation from a common progenitor or a collision of two clones remains debated, and several authors regard them as collisions rather than divergently differentiating single neoplasms [8].

A separate and dangerous mimic must be kept in mind, particularly in an elderly patient: metastatic melanoma can colonize a pre-existing basal cell carcinoma and reproduce, with considerable fidelity, the pattern of a basomelanocytic tumour [9]. The lesson is that the colonizing melanocytic population must always be interrogated for atypia and for clinical context: a known melanoma elsewhere reframes the entire interpretation. In the present patient no such history was available, and the melanocytic cells lacked the atypia that would prompt this concern.

The distinction also carries direct staging consequences. Where melanocytic involvement is confined to the epithelial tumour, several authors regard it, by analogy with melanoma in situ tracking along adnexal structures, as not constituting true dermal invasion, so that a colonized lesion is staged as in situ rather than invasive; misreading colonization as invasion would wrongly assign a Breslow thickness and a worse prognosis [3,10]. The reverse error is equally consequential, since melanoma that breaches the confines of the carcinoma into the adjacent dermis is, by definition, invasive. Reported outcomes across the heterogeneous published series are correspondingly variable: most colonized and combined lesions behave indolently after complete excision, yet deaths from metastatic melanoma arising within such tumours are on record, and in the absence of any large prospective cohort the biological behaviour of these neoplasms remains, in candour, unpredictable [2,6]. Several practical safeguards follow from this case and from the literature. The melanocytic markers should be read for pattern, density and cytology rather than for mere positivity; SOX10 in particular, although an excellent melanocytic marker, will faithfully label the benign colonizing melanocytes of any basal cell carcinoma and must not be over-interpreted [4]. The epithelial panel (here CK AE1/AE3, CK5/6 and p40) should be deployed to establish the nature of the dominant population, and where a double-label protocol is available it can directly demonstrate that the keratinocytic and melanocytic markers reside in separate cells, as Satter and colleagues showed with paired AE1/AE3 and HMB-45 chromogens [2]. The topographic relationship between the two components should be assessed deliberately. Where the

melanocytic component is dense, atypical or clustered, or where clinical history raises the possibility of melanoma, the threshold for additional work-up, expert consultation or discussion in a multidisciplinary setting should be low [10]. The morphological reasoning matters more than any single stain.

The principal limitation of this report is that of the single observation: the conclusions rest on morphology and a standard immunohistochemical panel, without molecular characterization, and follow-up data are not yet mature. The case nonetheless adds a well-documented example to a small and heterogeneous literature and reiterates a message of continuing relevance to diagnostic practice.

CONCLUSION

Baso-melanocytic lesions remain a source of diagnostic difficulty, and the stakes, distinguishing an indolent colonized carcinoma from a melanocytic malignancy, are high. This case demonstrates that the immunohistochemical detection of melanocytes within a basaloid tumour is, by itself, uninformative, and that the diagnosis depends on the disciplined integration of architecture, the density and cytology of the melanocytic component, its topography relative to the basaloid islands, and the epithelial immunophenotype. Rigorous morphological assessment, a rationally constructed panel and careful clinicopathological correlation remain the safeguards against over-diagnosis of melanoma in this setting.

Funding: No external funding sources are relevant to this submission.

Consent for Publication: Written informed consent for publication of their clinical details and/or clinical images was obtained from the patient.

Ethical Approval: Ethical approval is not required at our institution to publish an anonymous case report.

Competing Interests: The authors declare that they have no competing interests.

Data availability: The data supporting this case report are available from the corresponding author on reasonable request.

Use of AI-assisted technologies: During the preparation of this work, the authors used Claude (Anthropic) to assist with drafting from the authors' own case data, language editing and reference formatting. The authors reviewed and edited all content, verified the references, and take full responsibility for the content of the publication.

REFERENCES

1. Aghighi M, Chercover D, Rahvar M. Collision cutaneous neoplasms consisting of melanoma and basal cell carcinoma. *Dermatol Pract Concept.* 2021;11(3):e2021037. doi:10.5826/dpc.1103a37.
2. Satter EK, Metcalf J, Lountzis N, Elston DM. Tumors composed of malignant epithelial and melanocytic populations: a case series and review of the literature. *J Cutan Pathol.* 2009;36(2):211–219. doi:10.1111/j.1600-0560.2008.01000.x.
3. Mejbel HA, Nelson KC, Pradhan D, *et al.* Cutaneous neoplasms composed of melanoma and carcinoma: a rare but important diagnostic pitfall and review of the literature. *J Cutan Pathol.* 2020;47(1):36–46. doi:10.1111/cup.13551.
4. Florell SR, Zone JJ, Gerwels JW. Basal cell carcinomas are populated by melanocytes and Langerhans cells. *Am J Dermatopathol.* 2001;23(1):24–28. doi:10.1097/00000372-200102000-00004.
5. Brankov N, Prodanovic EM, Hurley MY. Pigmented basal cell carcinoma: increased melanin or increased melanocytes? *J Cutan Pathol.* 2016;43(12):1139–1142. doi:10.1111/cup.12819.
6. Erickson LA, Myers JL, Mihm MC, Markovic SN, Pittelkow MR. Malignant basomelanocytic tumor manifesting as metastatic melanoma. *Am J Surg Pathol.* 2004;28(10):1393–1396. doi:10.1097/01.pas.0000135526.19189.31.
7. Rodriguez J, Nonaka D, Kuhn E, Reichel M, Rosai J. Combined high-grade basal cell carcinoma and malignant melanoma of the skin ("malignant basomelanocytic tumor"): report of two cases and review of the literature. *Am J Dermatopathol.* 2005;27(4):314–318. doi:10.1097/01.dad.0000171600.17692.65.
8. Cornejo KM, Deng AC. Malignant melanoma within squamous cell carcinoma and basal cell carcinoma: is it a combined or collision tumor? A case report and review of the literature. *Am J Dermatopathol.* 2013;35(2):226–234. doi:10.1097/DAD.0b013e3182545e27.
9. Busam KJ, Halpern A, Marghoob AA. Malignant melanoma metastatic to a basal cell carcinoma simulating the pattern of a basomelanocytic tumor. *Am J Surg Pathol.* 2006;30(1):133–136. doi:10.1097/01.pas.0000179118.76904.02.
10. Dinehart M, Abate MS, Jennings T, Kaley JR, Shalin SC. Colliding, colonizing or combining? Four cases illustrating the unique challenges presented by melanoma arising in conjunction with basal cell carcinoma. *J Cutan Pathol.* 2018;45(6):443–452. doi:10.1111/cup.13137.