

Case Report

A Case Report: Neonatal Sigmoid VolvulusDr Niranjan Dash^{*1}, Dr Siddharth Mishra²¹Prof Surgery, PDVP Medical College, Ahmednagar, Maharashtra, India²Assoc Prof Medicine, AFMC, Pune, Maharashtra, India***Corresponding author**

Dr Niranjan Dash

Email: niranjan_dash@yahoo.com

Abstract: Sigmoid volvulus (SV) is an extremely rare cause of bowel obstruction in the newborn period. We report a neonatal case of SV in a one month old girl presented with evidence of small bowel obstruction. At laparotomy, the classical findings of a SV was observed without gangrene of the Gut. The operative procedure consisted of simple derotation followed by sigmoidopexy.

Keywords: Bowel obstruction, newborn, sigmoid volvulus (sv).

INTRODUCTION

Sigmoid Volvulus is the most common large bowel volvulus in adults. However colon volvulus is uncommon in children[1]. SV is a disease of the elderly, often in those who are institutionalized and debilitated with neurologic and psychiatric condition[2]. The first report of SV in a 14 days old boy was published in 1961 where as the youngest patient reported is a 1 day old boy with anal stenosis[3,4]. SV is rarely considered in the differential diagnosis of abdominal pain in neonates and children and this could be responsible for the devastating results. We report a neonate (01 month old) in which acute SV occurred and was successfully managed surgically by derotation and fixing.

CASE REPORT

A one month old female infant presented with pain abdomen (crying and denying food) absolute constipation of one week duration. Vomiting was present for 03 days. Abdominal distention was present for 02 days duration. The laboratory data was unremarkable. Plain abdominal X ray showed distended bowel loops and air fluid level in intestine.[Fig-1] the baby was resuscitated by nasogastric tube, intravenous fluids and broad spectrum antibiotics. She was taken up for emergency surgery for bowel obstruction. Abdominal exploration revealed clock wise SV. Pathological finding consisted of a redundant sigmoid loop rotated around its narrow, elongated mesentery. There was no gangrene. So derotation was done with loop fixation. Recovery was uneventful. The patient was discharged from the hospital after complete oral feeding was resumed. She is doing well for last 06 months of post op follow up.

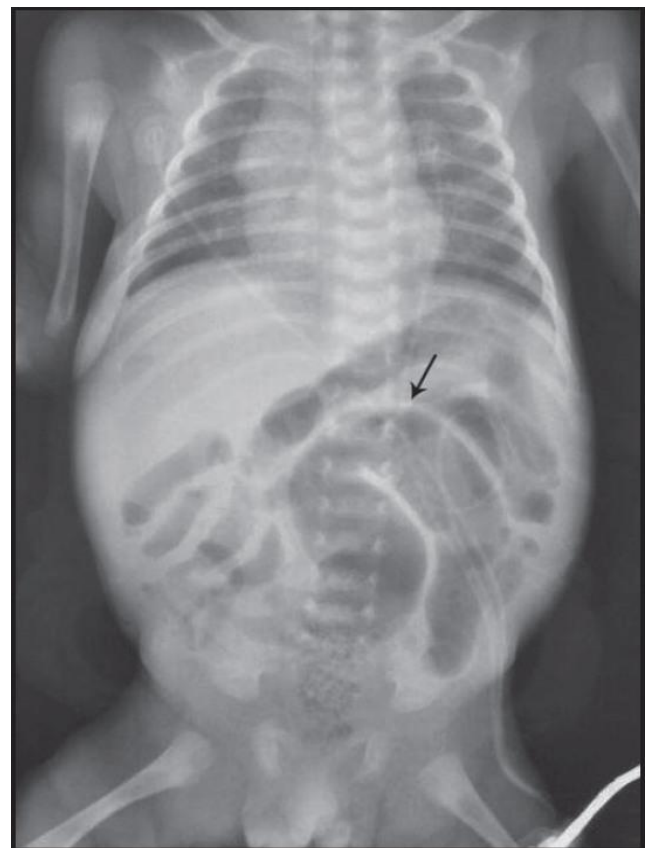


Fig-1: Showing distended loops of both small and Large bowel(sigmoid)

DISCUSSION

SV is a rare cause of bowel obstruction in newborn and children. There is strong male preponderance (Male : Female = 35 : 1) with wide geographic variation[5]. Our patient was a female. The presentation can range from acute to recurrent abdominal pain that is often

relieved by passage of stool or flatus. The diagnosis is usually missed or delayed with devastating consequences[6]. Our patient presented with abdominal pain and diagnosis was quick with good result after surgery. The possibility of SV should be suspected in presence of abdominal pain, constipation, nausea, vomiting with abdominal distention, tenderness and mass. Signs of peritonitis and fever suggests worst condition and perforation. Bowel peristalsis is compromised and rectum is empty[7]. The etiology of SV is different in children and adults with complication being the most common in elderly[8]. Although the etiology in children is not completely understood, the hypothesis is the presence of congenital elongation of the sigmoid colon with pathological long colonic mesentery in association with narrow base or lack of fixation of the part of colon[9]. Constipation can be considered as a cause with progressive colonic redundancy or a result. However in our case either long elongation of sigmoid colon or history of constipation was cause of volvulus.

The diagnosis is often difficult considering history, physical examination and plain abdominal radiograph. The gas pattern on X-ray is nonspecific due to absence of single U-shaped sigmoid colon loop as in adult and the inconsistent presence of the “coffee – bean” sign. The diagnosis is possible by CT scan by whirl pattern caused by dilated sigmoid colon and its meso colon and vessels and a bird peak appearance of the afferent and efferent colonic segment. However, the classic imaging are not uniformly seen. In our case, CT scan was not possible, the reaction time was less and the poor general condition of the patient forced us for emergency laparotomy.

The management of SV remains controversial, partly due to its rare occurrence. Barium enema has both diagnostic and therapeutic importance but can be complicated by perforation and shouldn't be attempted in any patient with possible peritonitis[2]. We did not do this investigation procedure as we took up the case for surgery immediately. Reduction by endoscopy and decompression by rectal tube are other means of non operative procedure, but also carry the risk of perforation. Furthermore, non operative procedures have a high recurrence(35%) and not definitive[10].

The neonate reported here was in very poor general condition with clinical evidence of mechanical obstruction of gut. Hence, taken up for early surgery . Non resection approach with de rotation gave us a good prognosis. A volvulus preventive procedure, like

sigmoidopexy was added to its good prognostic factor[11].

The overall mortality rate for SV is 6% while operative and neonatal mortality has been reported as 8.1% and 14% respectively[5]. The most common cause of death in SV is sepsis. Other causes include pneumonia, intra cranial haemorrhage, malnutrition, renal failure or hepatic failure. However, our patient is doing well for last one year of follow up.

CONCLUSION

In our experience and in accordance to literature review, children with SV do well in experienced hands of surgeon's if operated early (prior to ischemia) in absence of co morbidities.

REFERENCES

1. Pastore V, Basile A, Cocomazzi R, Pastore M, Bartoli F; Sigmoid volvulus in a neonate: Case report and review of literature. *African Journal of Paediatric Surgery* , 2013;10(4):390-392.
2. Valsdottir E, Marks JH; Volvulus : Small bowel and Colon. *Clin colon rectal surg*, 2008; 21 :91-93.
3. Carter R, Hinshaw DB; Acute Sigmoid Volvulus in Children. *Am J Dis Child* ,1961; 101: 631-634.
4. De Caluwe D, Kelleher J, corbally MT; Neonatal sigmoid volvulus: A complication of anal stenosis. *J Pediatr Surg*, 2001; 36: 1079- 1081.
5. Salas S, Angel CA, Salas N, Murillo C, Swischuk L; Sigmoid Volvulus in Children and adolescents. *J Am Coll Surg*, 2000; 190: 717-723.
6. Waseem M, Hipp A; Megacolon: Constipation or volvulus?. *Pediatric emergency care*, 2006; 22(5):346-348.
7. Atamanalp SS, Yildirgan MI, Baroolu M, Kantarci M, Yilmaz I; Sigmoid Coloc Volvulus in Children: Review of 19 cases. *Padiatr Surg Int*, 2004; 20: 492-495.
8. Zeng M, Amodio J, Schwarz S, Garrow E, Xu J, Rabinowitz SS; Hirschsprung disease presenting as sigmoid volvulus: A case report and review of literature. *J Pediatr Surg*, 2013; 48:243-246.
9. Osiro SB, Cunningham D, Shoja MM, Tubbs RS, Gielecki J, Loukas M; The Twisted Colon: A view of Sigmoid volvulus. *Am Surg*, 2012; 78:271-279.
10. Oren D, Atamanalp SS, Aydinli B, Yildirgan MI, Basoolu M, Polat KY, et al.; An algorithm for the management of sigmoid colon volvulus and the safety of primary resection: Experience with 827 cases. *Dis Colon Rectum*, 2007; 50:489-97.
11. Khanna R, Gangopadhyay AN, Sahoo SP, Khanna AK; Sigmoid Volvulus in Childhood: Report of six cases. *Pediatr Surg Int*, 2000; 16(1-2):132-133.