

Research Article

Evaluation of Efficacy of Tube Ileostomy Drainage after Primary Repair/ Resection in Small Bowel Perforation

Deepak Rajput¹, Lokendra Kumar^{2*}, Rajesh Kumar Soni³, Ajit Sinha⁴, Ashwani Gupta⁵

¹Senior Resident, Department of General Surgery, VMMC and Safdarjung Hospital, New Delhi-110029, India

²Consultant General and Laparoscopic surgeon, Department of General Surgery, Park Super-speciality Hospital, Faridabad, Haryana-121006, India

³Associate Professor, Department of General Surgery, VMMC and Safdarjung Hospital, New Delhi-110029, India

⁴Professor and Unit Head, Department of General Surgery, VMMC and Safdarjung Hospital, New Delhi – 110029, India

*Corresponding author

Dr. Lokendra Kumar

Email: lokendrachoudhary1982@gmail.com

Abstract: Although perforation is a worldwide problem, the incidence is much higher in developing countries including India. The move of scientific community towards the management of bowel perforation has changed from a conservative approach in earlier parts of this century to surgery. Despite the availability of modern diagnostic facilities and advances in treatment regimes, this condition is still associated with high morbidity and mortality. Various operative procedures have been advocated by different authors, such as simple repair of perforation, repair of perforation with ileo-transverse colostomy, ileostomy, exteriorization, single layer repair with an omental patch, trimming of ulcer edge & closure, wedge excision & anastomosis and segmental resection and anastomosis. Aim of this study was to evaluate the efficacy of tube ileostomy drainage after primary repair/resection anastomosis in small bowel perforation. A total of 60 patients were evaluated as per the criteria defined and underwent primary closure, resection & anastomosis and T-Tube ileostomy after primary repair/resection anastomosis. After this study it can be said that proximal T-TUBE diversion may be an alternative to open ileostomy in patients with poor general condition at the time of presentation to the hospital where simple primary repair /resection and anastomosis seems to be risky. It seems to be a better procedure than temporary ileostomy due to its cost effectiveness, absence of complications related to ileostomy and the need for second surgery for ileostomy closure.

Keywords: Perforation, Ileostomy, Tube ileostomy, Resection anastomosis.

INTRODUCTION

Overall, morbidity can be reduced and outcome optimized by aggressive resuscitation in all cases of small bowel perforation, and early limited surgery. Thus T-tube ileostomy in patients with multiple ileal perforations and poor general condition can be used as an alternative to open ileostomy. Given the better outcome with T-tube, it may be necessary to include patients with single perforation and poor general condition among those who may benefit from T-tube in future studies. Small bowel perforation is one of the most commonly occurring surgical emergencies with majority of them occurring in the ileal region. Enteric fever & Tuberculosis form the bulk of patients of non-traumatic small bowel perforation in the developing world, whereas non-infectious pathology is more commonly seen in the western population. Surgery is now universally accepted as the definitive treatment of ileal perforation and is the only successful modality, but the choice of procedure continues to be debated. Various strategies being used to deal with ileal

perforation include primary closure, segmental resection and anastomosis with/without defunctioning ileostomy. Primary closure is usually performed for single perforations, those with minimal contamination of the peritoneal cavity and those presenting early to the hospital. Segmental resection & anastomosis is preferred for multiple perforations. Bowel exteriorisation in the form of ileostomy is added for patients with poor general condition, those having massive peritoneal contamination and those presenting late to the hospital.

Severity scoring is a valuable tool for assessing and quantification of severity of acute illness. Currently Acute Physiology and Chronic Health Evaluation (APACHE II) scoring system is the best available method for risk stratification in abdominal sepsis.

Ileostomy although a life saving procedure, is associated with significant morbidity and various

complications such as prolapse, stricture, retraction, skin excoriation and parastomal hernias which contribute to morbidity. Ileostomy functions to protect the intestinal repair done in infected tissues and serves to reduce the risk of anastomotic dehiscence. Of all the post-operative complications faecal fistula remains the most dreaded.

In an attempt to avoid the ileostomy, its subsequent complications and morbidity, and the need for a second surgery; we used a T-tube in its place in patients with poor general condition. The proposed study aims to define the severity of peritonitis based on APACHE II (Acute Physiology and Chronic Health Evaluation) score and determine the feasibility of proximal T-tube drainage in such patients.

MATERIALS AND METHODS

This was a prospective study conducted in Department of General Surgery, VMMC and Safdarjung Hospital, New Delhi, India, from October 2009 to March 2011 (18 months). It was approved by the hospital ethical and postgraduate committee.

Patients presenting in surgical emergency of Safdarjung Hospital on the basis of their diagnosis of small bowel perforation were included in the study. The diagnosis of perforation was suspected on clinical basis and confirmed by gas under the diaphragm in plain abdominal x-ray in erect view and by the presence of free fluid in pelvis on abdominal ultrasound.

We included only those patients of proved ileal perforation for T-Tube placement who were having poor general condition at the time of presentation to the department in which primary closure or resection and anastomosis was judged to be very risky.

The poor general condition was judged on basis of state of shock, such as thready pulse, tachycardia, and tachypnoea, and poor response to verbal or painful stimulus, fever $> 104^{\circ}\text{F}$, need of oxygen supplementation, and requirement of ionotropic support.

APACHE II score was calculated using clinical and biochemical parameters and used to grade severity of disease and prognosis.

Number of patients included in the study were 60; having APACHE II score ≥ 15 . Randomly they were divided into two groups comprising 30 patients each. In one group T-Tube was placed proximally after primary repair/resection and anastomosis (RA) of the ileal perforation; and in the other group only primary repair/resection and anastomosis was done.

Informed and written consent about the procedure and its possible complications was taken from all patients.

Inclusion criteria

Patients with an APACHE II SCORE ≥ 15 and any one of the following criteria's were included in the study:

- Large perforation > 2 cm.
- Patients having more than 2 perforations.
- Perforations in the distal 10 cm of ileum.
- With peritoneal contamination (> 500 ml).
- Patients presenting late (> 48 hrs).

All these patients were considered for primary repair/segmental resection and anastomosis with a proximal T tube diversion.

After initial resuscitation and intravenous antibiotics administration, exploratory laparotomy was performed by midline vertical incision in all the patients. We had accepted peritoneal contamination as severe when the drainage amount was > 1000 ml, moderate when the amount was between 500 and 1000 ml, and mild when the amount was < 500 ml.

After thorough peritoneal decontamination, primary repair was usually done for single perforations; and resection and anastomosis reserved for multiple perforations/long diseased ileal segment.

Primary repair was done with 3-0 vicryl in a single layer (extramucosal).

A wide bore T tube of size (16/18 Fr) was used for proximal diversion and placed about 1feet proximal to the most proximal perforation or impending perforation. It was secured with the parietes with sutures at two points and will be brought out through a separate incision. T tube was removed in second week subject to patient's recovery – return of bowel sounds, passes flatus/stools. In case tube ileostomy diversion failed or the patient developed signs of peritoneal leak, an open ileostomy was made.

Exclusion criteria

- Patients aged ≤ 12 years.
- Traumatic small bowel perforation.
- Perforation associated with malignant disease.

The patients were compared with those patients having APACHE II score ≥ 15 in whom primary closure or resection and anastomosis was performed during the same time period. The evaluation was performed on basis of duration of hospital stay, complications related to T-Tube and overall complications, start of oral feeds, and follow up.

Statistical analysis

Statistical analysis was performed using SPSS® for Windows release 17.0 (SPSS, Chicago, IL, USA). The quantitative variables are presented as mean \pm SD or median (with interquartile range). For comparison between groups; the Mann-Whitney test

and Student's t test were applied for continuous variables and Pearson Chi-square test was employed for discrete variables. Results with $p < 0.05$ were considered statistically significant.

RESULTS

Patients presenting in surgical emergency of Safdarjung Hospital on the basis of their diagnosis of small bowel perforation were included in the study.

Number of patients included in the study were 60; having APACHE II score ≥ 15 . Randomly they were divided into two groups comprising 30 patients each. In one group T-Tube was placed proximally after primary repair/resection and anastomosis of the ileal perforation; and in the other group only primary repair/resection and anastomosis was done.

Age group distribution

Majority of patients were in the age group 20-29 with 23 of 60 patients (38.3%) (Table 1, Fig. 1), these levels were arbitrarily taken. When comparison was done between the two groups i.e. No T-TUBE and T-TUBE; the mean age was 30.13 years in former group and 27.63 years in the latter group against an overall mean of 28.88 years. The range of patient's age was between 14 to 56 years with a standard deviation of 10.064 years. On application of Standard T test and Independent Samples test for age distribution in the two groups, p value came out to be > 0.05 (0.462) which was statistically insignificant thus implying that the two groups were comparable in terms of age distribution.

Gender distribution

Majority of the patients included in the study were males 49 out of 60 patients (81.7%). Male to female ratio was 4.4:1. P value was > 0.05 , thus implying that the two groups were comparable in sex distribution.

Duration of pain

The interval between onset of abdominal pain and presentation to the hospital was taken as duration of pain. Duration was arbitrarily divided into two i.e. < 48 hours and > 48 hours. The more the duration of pain, more severe the illness and worse the prognosis expected. 17 out of 60 patients (28.3%) presented to the hospital within 48 hours whereas majority of them i.e. 43 out of 60 patients (71.7%) presented after 48 hours. There was no statistical difference between the two groups in relation to duration of pain, P value > 0.05 (0.390) stating that the two groups were comparable (Table 2).

History

Patients presenting to the hospital with fever and clinical diagnosis of small bowel perforation have many of times enteric fever as the cause of perforation. It indicated towards a poor prognosis and severity of the disease. Primary repair/Resection and Anastomosis can

be quite risky in such patients without a proximal diversion. Past history or a family history of tuberculosis points towards a probability of tubercular etiology.

Fever

History of fever was present in 49 out of 60 patients (81.7%) whereas 11 out of 60 patients (18.3%) gave no such history. P value came out to be > 0.05 (0.317) which was statistically insignificant.

History of tuberculosis

Past history/family history of TB was present in 10 out of 60 patients (16.7%) while 50 out of 60 patients (83.3%) gave no such history. P value came out to be > 0.05 (0.488) proving that the two groups were comparable (Table 3).

X ray abdomen

All patients suspected of having small bowel perforation underwent x-ray abdomen in erect and supine positions. 23 out of 60 patients (38.3%) had free gas present under the right dome of diaphragm, 2 out of 60 patients (3.3%) had multiple air fluid levels and an equal percentage of patients had other findings in the form of pleural effusion and calcified lesions in both lung fields. There were no significant findings detected in the x-ray abdomen in 33 out of 60 patients (55%).

USG abdomen

All patients clinically suspected of having a small bowel perforation and who had no free gas present under right dome of diaphragm under ultrasound abdomen to confirm the diagnosis. Number of such patients was 37 out of 60 (61.67%). Among these patients 75.7% had free fluid in pelvis, 21.6% had particulate ascites while 2.7% had exudative ascites with mesenteric lymphadenopathy.

Widal test

In all patients presenting to the hospital with clinical diagnosis of small bowel perforation Widal test was performed in the second week from onset of the illness. It was positive in 44 out of 60 patients (73.3%) suggesting an enteric etiology (Table 4).

APACHE II score and number, diameter, location from ileocaecaljunction and peritoneal contamination of the perforation (Table 5)

Applying Mann-Whitney test findings were statistically insignificant in patients of both the groups

Procedure

22 out of 60 patients underwent simple primary repair and resection and anastomosis alone was done in 8 out of 60 patients. In 30 patients whom T-TUBE diversion was placed after Primary repair/RA; 24 patients had primary repair done and 6 patients underwent resection and anastomosis.

Post operative period

The post operative period was uneventful in 23 out of 60 patients (38.3%). Wound dehiscence occurred in 15 out of 60 patients (25%) while 8 out of 60 patients (13.3%) developed burst abdomen; both complications occurring more commonly in patients having a proximal T-TUBE diversion. However 14 out of 60 patients (23.3%) developed post operative leak of which 11 patients were those in whom no proximal T-tube was placed after primary repair/RA (Fig. 2).

Return of bowel sounds and start of enteral feed

Post operatively early return of bowel sounds indicates that the patient is recovering well. Earlier the return of bowel sounds, less are the chances of post operative abdominal distention and consequent development of anastomotic leak. In patients whom proximal T-tube diversion was done after Primary repair/RA, there was an earlier return of bowel sounds usually on the third/fourth post operative day thus facilitating start of enteral feed.

Ileostomy and its complications

In patients whom T-tube was placed proximally after primary repair/resection and anastomosis; 3 out of 30 patients (10%) had slight biliary leak by the side of the tube. 3 out of 30 patients (10%) developed post operative faecal fistula (Fig. 3).

In 30 patients where simple primary repair/resection and anastomosis was done without a proximal diversion; 11 patients (36.67%) developed faecal fistula. An open ileostomy was made in these patients. Among the subsequent complications that developed after an open ileostomy; skin excoriation was present in all patients, bleeding in 2 out of 11 patients (18.18%), retraction was seen in 2 patients (18.18%) and ileostomy prolapsed in 1 patient (9.09%).

Biopsy

Biopsy was sent in only those patients where resection and anastomosis was performed. Number of such patients was 14.

Duration of hospital stay

The mean duration of hospital stay was 16.50 days in patients where simple primary repair/resection and anastomosis was done as compared to 17.47 days in those patients who had a proximal T-tube diversion

after primary repair/RA. This turned out to be statistically insignificant.

OUTCOME

43 out of 60 patients (71.7%) in both the groups recovered completely [table 6]. There was an overall mortality of 16.7%. An open ileostomy was made in 7 out of 60 patients (11.7%); of which only 1 patient was from proximal T-tube diversion group. 8 out of 30 patients (26.7%) died in the group where simple primary repair/resection and anastomosis was done whereas only 2 out of 30 patients (6.7%) expired in the group where a proximal diversion was used after primary repair/RA. These 2 patients had systemic complications and could not survive despite ICU care.

Applying Pearson Chi-square test, P value came out to be < 0.05 (0.007) proving statistical significance.

Thus it can be said that proximal T-TUBE diversion may be an alternative to open ileostomy in patients with poor general condition at the time of presentation to the hospital where simple primary/resection and anastomosis seems to be risky.

Removal of T-tube

Studies in paediatric population of proven typhoid ileal perforation demonstrated removal of T-tube after 2 weeks. Thus in our study also we removed the T-tube near second week subject to patient's good general condition.

The day of removal of t-tube ranged from 10th to 17th post operative day with a mean of 12.96 days. There was no complication seen after removal of T-TUBE.

Follow up

Of the 30 patients in whom T-TUBE was placed proximally after Primary repair/RA only 1 patient followed up in the Safdarjung Hospital OPD for closure of incisional hernia. However he did not complaint of any features suggestive of intestinal obstruction in the post operative period on questioning. The patients who underwent an open ileostomy followed up for ileostomy closure. The mean presentation to the hospital for ileostomy closure was 6.14 months.

Table 1: Age group Cross tabulation

			Age Group				Total
			< 20	20-29	30-39	≥ 40	
Group	No T- Tube	Count	5	12	6	7	30
		% within group	16.7%	40.0%	20.0%	23.3%	100.0%
	T-Tube	Count	7	11	9	3	30
		% within group	23.3%	36.7%	30.0%	10.0%	100.0%
Total		Count	12	23	15	10	60
		% within group	20.0%	38.3%	25.0%	16.7%	100.0%

*T tube and non T tube group

Table 2: Duration of pain Cross tabulation

			Duration of pain		Total
			< 48 hrs	> 48 hrs	
Group	No T- Tube	Count	10	20	30
		% within GROUP	33.3%	66.7%	100.0%
	T-Tube	Count	7	23	30
		% within GROUP	23.3%	76.7%	100.0%
Total		Count	17	43	60
		% within GROUP	28.3%	71.7%	100.0%

Table 3: H/O Tuberculosis cross tabulation

			H/O Tuberculosis		Total
			Present	Absent	
Group	No T- Tube	Count	6	24	30
		% within group	20.0%	80.0%	100.0%
	T-Tube	Count	4	26	30
		% within group	13.3%	86.7%	100.0%
Total		Count	10	50	60
		% within group	16.7%	83.3%	100.0%

Table 4: Widal test Cross tabulation

			Widal Test		Total
			Positive	Negative	
Group	No T- Tube	Count	21	9	30
		% within group	70.0%	30.0%	100.0%
	T-Tube	Count	23	7	30
		% within group	76.7%	23.3%	100.0%
Total		Count	44	16	60
		% within group	73.3%	26.7%	100.0%

Table 5: APACHE II SCORE and number, diameter, location from ileocaecaljunction and peritoneal contamination of the perforation

Group		APACHE II Score	Diameter (cm)	Location (cm)	Contamination
No T- Tube	N	30	30	30	30
	Minimum	15	0	10	400
	Maximum	17	2	60	3000
	Range	2	2	50	2600
	Mean	15.53	.99	29.50	1236.67
	Std. Deviation	.730	.423	13.668	686.437
	Median	15.00	1.00	30.00	1000.00
	Std. Error of Mean	.133	.077	2.495	125.326
T-Tube	N	30	30	30	30
	Minimum	14	0	2	500
	Maximum	20	2	75	4500
	Range	6	2	73	4000
	Mean	16.40	1.33	26.73	1340.00
	Std. Deviation	1.734	.558	16.690	781.841
	Median	16.00	1.00	30.00	1000.00
	Std. Error of Mean	.317	.102	3.047	142.744
Total	N	60	60	60	60
	Minimum	14	0	2	400
	Maximum	20	2	75	4500
	Range	6	2	73	4100
	Mean	15.97	1.16	28.12	1288.33
	Std. Deviation	1.390	.520	15.188	731.284
	Median	15.50	1.00	30.00	1000.00
	Std. Error of Mean	.179	.067	1.961	94.408

Table 6: Outcomes - group Cross tabulation

Outcome	Recovered	Count	Group		Total
			No T- Tube	T-Tube	
Recovered	Recovered	Count	16	27	43
		% within group	53.3%	90.0%	71.7%
Ileostomy	Ileostomy	Count	6	1	7
		% within group	20.0%	3.3%	11.7%
Expired	Expired	Count	8	2	10
		% within group	26.7%	6.7%	16.7%
Total	Total	Count	30	30	60
		% within group	100.0%	100.0%	100.0%

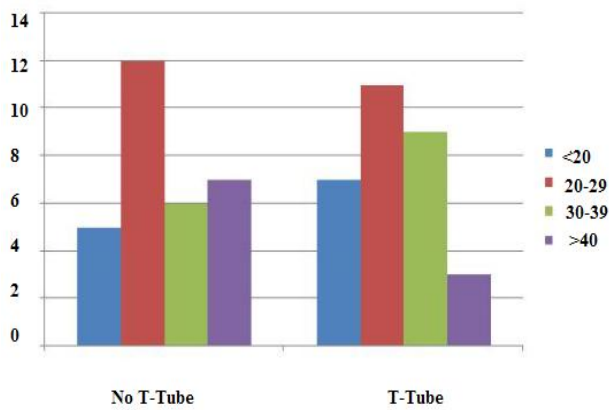


Fig. 1: Bar diagram showing age distribution of patients

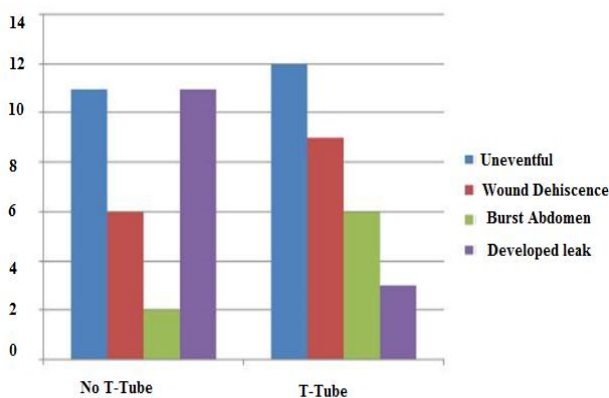


Fig. 2: Showing post operative complications in patients of both groups

Open Ileostomy

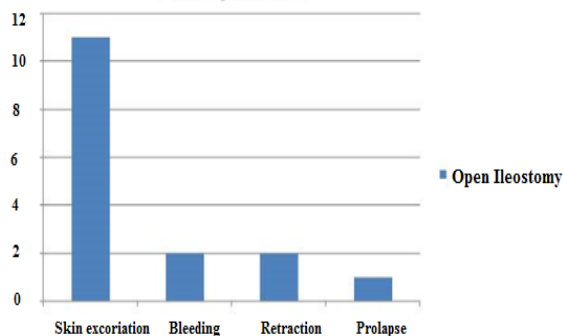


Fig. 3: Bar diagram showing various complications of an open ileostomy

DISCUSSION

Small bowel perforation is still a common cause for peritonitis in developing countries and while in the west it is quite rare. Surgery is the ideal treatment as eliminates soilage of peritoneal cavity in an effort to lessen the toxæmia and enhance the recovery of the patient. However there is no uniformity of standardized operative procedure that is most effective for the offending lesion. The surgical procedures include simple closure of perforation with or without omental patch [1-3] repair of perforation with ileo-transverse

colostomy [3], ileostomy [3, 4], exteriorization, trimming of ulcer edge and closure [5], wedge excision & anastomosis and segmental resection and anastomosis [1,3,5-7].

There are also no criteria which define the type of surgical procedure based on the sepsis score. In the present study, all the patients were scored according to the APACHE II score. It was decided that patients with APACHE II score ≥ 15 would be included in the study. Such patients were randomly divided into two groups: one in which simple primary repair/resection and anastomosis would be done and other group in which a proximal T-Tube diversion would be done after primary repair/RA. The present study is an endeavour in this context to evaluate the efficacy of a proximal tube ileostomy in patients of small bowel perforation with a poor general condition who would otherwise require an ileostomy.

Small bowel perforations most commonly affect young in the prime of their life. In the present study male preponderance was found with male to female ratio of 4.4:1 that is consistent with the ratio of 3:1 reported by Wani *et al.* [2], 4:1 reported by Adesunkamni [11], and Talwar *et al.* [5], 6.4:1 by Beniwal *et al.* [3] and 6.5:1 reported by Prasad *et al.*[17]. The mean age was 28.88 years with range of 14-56 years. The mean age was higher in our study as children below 12 years of age were excluded. Majority of the patients were in the age group 13-29 years (58.3%).

The etiology of perforations was concluded on the basis of history of fever/tuberculosis, Widal reaction, operative findings, histopathological examination. Typhoid accounted for 73.3% ileal perforations and tuberculosis 16.67%. Those patients in whom the diagnosis could not be made and the histopathological examination revealed nonspecific inflammation were labelled as nonspecific (10.03%). The causes for non-traumatic terminal ileal perforation were enteric fever (62%), nonspecific inflammation (26%), obstruction (6%), tuberculosis (4%) and radiation enteritis (1%) as reported by Wani *et al.* [2]. Nadkarni found (56.6%) nonspecific causes, followed by typhoid perforation (25%) and tubercular perforation (9.3%).

Widal test positivity in our study was 73.3%, however variation in positivity has been reported. Beniwal *et al.* [3] reported 80.5% diagnosis positivity, Eggleston *et al.* [8] reported 57.6.

Besides the etiology, the duration of perforation at presentation has an important bearing on the outcome of the management strategy. In our study, about 28.3% of patients presented within 48 hours of perforation and had favourable outcome from those who presented late. The mortality in delayed

presentation was more. Delayed presentation did not necessarily correlate with high APACHE II score. Purohit observed 22.2% mortality in those presenting within 48 hrs and 100% in those presenting after 4 days [9]. Archampong observed 39.6% mortality in those presenting within 48 hours and 80% in those presenting after 4 days [10].

In our study, peritonitis was present in all and the contamination was feco-purulent in nature. The majority of perforations were single (70%), of size around 1 cm, located within 30 cm of terminal ileum and peritoneal contamination around 1300 ml. The terminal ileum is rich in lymphoid follicles (Peyer's patches). These undergo swelling and ulceration as a result of disease process and progress to capillary thrombosis and subsequent necrosis. Adesunkamni observed 86% single perforations and 14% multiple perforations [11]. Wani et al observed 62% had single perforation and rest had multiple perforations. Almost all of the perforations were located on the anti-mesenteric border of last 2 feet of terminal ileum and size observed was 2-22 mm (average 5 mm) [2].

Typhoid perforation is rare under 5 years of age and over 50 years of age. Patients with enteric perforation were admitted throughout the year with highest number in months of July, August and September [3, 11]. Nonspecific perforation of bowel also has been found to affect young males.

In the present study, different operative procedures: simple closure of the perforation, resection-anastomosis and T-TUBE ileostomy were performed keeping APACHE II score ≥ 15 for all patients. 22 out of 60 patients underwent simple primary repair and resection and anastomosis alone was done in 8 out of 60 patients. In 30 patients whom T-TUBE diversion was placed after Primary repair/RA; 24 patients had primary repair done and 6 patients underwent resection and anastomosis. In the literature, simple closure of perforation is recommended for single perforations with less peritoneal contamination [1, 2, 3, 5] while wedge excision, segmental resection & anastomosis, ileo-transverse anastomosis have been recommended for multiple perforations, diseased segment of bowel [1,3, 5-7].

Simple repair of perforation in two layers is the treatment of choice for typhoid perforation. If there are multiple perforations or any other areas of bowel seem unhealthy or liable to perforate, a length of small bowel should be resected, including all the diseased part and a two-layer anastomosis is performed. Shah et al observed it is better to opt for resection-anastomosis irrespective of the number of perforations and found lower complication rate (35.5%) and mortality rate (21.47%) in comparison to simple closure (71.25% complication rate and 42.96% mortality rate) and ileostomy (100% complication rate and 77.77%

mortality rate). Pal reported 6.22% mortality with simple closure and ileo-transverse anastomosis and found it to be better [12]. The post operative period was uneventful in 23 out of 60 patients (38.3%). Wound dehiscence occurred in 15 out of 60 patients (25%) while 8 out of 60 patients (13.3%) developed burst abdomen; both complications occurring more commonly in patients having a proximal T-TUBE diversion. However 14 out of 60 patients (23.3%) developed post operative leak of which 11 patients were those in whom no proximal T-tube was placed after primary repair/RA.

The morbidity rate from ileal typhoid perforation is high irrespective of the surgical procedure. This is related to the virulence of the organism and extent of disease and not necessarily to the surgical procedure [8, 13]. Prognosis is directly related to the degree of septicemia which depends on the resistance of organism, degree of peritoneal contamination and delay in manifestation which is reflected in high APACHE II scores.

In patients whom proximal T-tube diversion was done after Primary repair/RA, there was an earlier return of bowel sounds usually on the third/fourth post operative day thus facilitating start of enteral feed. 3 out of 30 patients (10%) had slight biliary leak by the side of the tube. 3 out of 30 patients (10%) developed post operative faecal fistula. In 30 patients where simple primary repair/resection and anastomosis was done without a proximal diversion; 11 patients (36.67%) developed faecal fistula. An open ileostomy was made in these patients. Among the subsequent complications that developed after an open ileostomy; skin excoriation was present in all patients, bleeding in 2 out of 11 patients (18.18%), retraction was seen in 2 patients (18.18%) and ileostomy prolapsed in 1 patient (9.09%). Ileostomy related complication rate in our study was higher than the previous studies as reported by Bakx et al [14], Pearl et al and Leong et al [15].

The mean duration of hospital stay was 16.50 days in patients where simple primary repair/resection and anastomosis was done as compared to 17.47 days in those patients who had a proximal T-tube diversion after primary repair/RA.

43 out of 60 patients (71.7%) in both the groups recovered completely. There was an overall mortality of 16.7%. 8 out of 30 patients (26.7%) died in the group where simple primary repair/resection and anastomosis was done whereas only 2 out of 30 patients (6.7%) expired in the group where a proximal diversion was used after primary repair/RA. These 2 patients had systemic complications and could not survive despite ICU care.

An open ileostomy was made in 7 out of 60 patients (11.7%); of which only 1 patient was from

proximal T-tube diversion group. P value came out to be < 0.05 (0.007) proving statistical significance. The patients who underwent an open ileostomy followed up for ileostomy closure. The mean presentation to the hospital for ileostomy closure was 6.14 months.

Studies in paediatric population of proven typhoid ileal perforation demonstrated removal of T-tube after 2 weeks [16]. Thus in our study also we removed the T-tube near second week subject to patient's good general condition.

The day of removal of t-tube ranged from 10th to 17th post operative day with a mean of 12.96 days. There was no complication seen after removal of T-TUBE. Of the 30 patients in whom T-TUBE was placed proximally after Primary repair/RA only 1 patient followed up in the Safdarjung Hospital OPD for closure of incisional hernia. However he did not complain of any features suggestive of intestinal obstruction in the post operative period.

Thus it can be said that proximal T-TUBE diversion may be an alternative to open ileostomy in patients with poor general condition at the time of presentation to the hospital where simple primary/resection and anastomosis seems to be risky. It seems to be a better procedure than temporary ileostomy due to its cost effectiveness, absence of complications related to ileostomy and the need for second surgery for ileostomy closure.

CONCLUSIONS AND RECOMMENDATIONS

Typhoid perforation continues to be a scourge in developing countries. The perforation results from necrosis of Peyer's patches in the terminal ileum. It usually occurs during the second or third week of fever. Surgery is the accepted mode of treatment; but there is no general agreement regarding the choice of procedure, but ileostomy has been suggested for patients with delayed presentation and severe abdominal contamination.

The ileostomy has been in practice since 1793 for emergency management. It became a standard procedure by virtue of its low immediate mortality and ease of performance, but it necessitates staged procedures for closure with repeated hospital admissions and prolonged hospital stay. It has been associated with multiple complications, such as prolapse, stricture, parastomal hernia, and perforation. In a tropical country like ours, ileostomy diarrhoea can lead to a lethal sequence in the summer season. However it is still needed in emergency when peritoneal cavity is severely contaminated and resection-anastomosis is not safe. We used the criteria of mild, moderate, and severe contamination on the basis of volume of peritoneal fluid present at the time of laparotomy.

The use of T-Tube in these patients can be advantageous because it promotes decompression of bowel, prevents further complications of hypoperistalsis and stasis, and allows an uneventful healing of the site of perforation. Parietal fixation of the T-tube was done after it was secured by purse-string suture; hence, the chances of leakage are minimal. In our study, no such case was observed. We would also like to say that proper closure of the perforation is as important as securing it to the parietal wall. The goal of the T-tube is simultaneous decompression of the bowel along with normal flow of ileal content to the distal bowel. We believe that the T-tube acts as a vent and stent in such a condition as it does in the common bile duct.

T-tube ileostomy combines advantages of enterostomy, such as intestinal decompression, early feeding, and rapid technique with those of primary anastomosis, such as restoration of intestinal continuity and avoiding secondary operation. The oral intake was in form of liquids on the fourth to sixth day followed by semisolid food for the next 2 days and then full oral feeds and hence the chance of blockade of T-tube was minimal; moreover as the ileal contents are liquid during the early part of recovery period and chances of tube block were not much. The removal of the tube after 12 to 14 days was based on the assumption that the tube tract is formed during this period thereby preventing the chances of peritoneal contamination.

Although there were complications in our series, they were not related to the use of the T-tube. The theoretical chances of injury to the friable bowel by the application of purse-string sutures were not noticed in any of our patients. Majority of our patients had an uneventful recovery with the use of the T-tube, suggesting that T-tube ileostomy can be used as an effective alternative to ileostomy and preventing its long-term morbidity. The two patients who expired in T-tube group had other systemic complications such as ARDS and ARF.

REFERENCES

1. Pal DK; Evaluation of best surgical procedures in typhoid perforation-an experience of 60 cases. *Trop-Doct.* 1998 Jan; 28(1):16-18.
2. Wani RA, Parray FQ, Bhat NA, Wani MA, Bhat TH, Farzana F; Nontraumatic terminal ileal perforation. *World J Emerg Sug.* 2006; 24: 1:7.
3. Beniwal U, Jindal D, Sharma J, Jain S, Shyam G; Comparative study of operative procedures in typhoid perforation. *Indian J Surg*, 2003; 65(2):172 – 177.
4. Sharma D, Bhansali M, Saxena A, Raina VK; Treatment of typhoid ileal perforation by resection and temporary ileostomy. *Indian J Gastroenterol*, 2002; 21(5):205-206.
5. Talwar S, Sharma RK, Mittal OK, Prasad P; Typhoid enteric perforation. *Aust NZ J Surg*, 1997; 67(6):351-353

6. Athie CG, Gulzar CB, Alcantara A V, Alcaraz GH, Montalvo EJ; Twenty-five years of experience in the surgical treatment of perforation of the ileum caused by Salmonella typhi at the General Hospital of Mexico City. Mexico. Surgery, 1998; 123(6):632-636.
7. Saxe JM, Cropsey R; Is operative management effective in treatment of perforated typhoid? Am J Surg. 2005;189(3):342-344.
8. Eggleston FC, Santoshi B, Singh CM; Typhoid perforation of the bowel. Experiences in 78 cases. Ann Surg, 1979;190(1):31-35.
9. Purohit PG; Surgical treatment of typhoid perforation: Experience of 1976 Sangli epidemic. Indian J Surg, 1978; 40:227-238.
10. Archampong EQ; Typhoid ileal perforations: why such mortalities? Br J Surg, 1976; 63(4):317-321.
11. Adesunkanmi ARK, Badmus TA, Fadiora FO, Agbakwuru EA; Generalised peritonitis secondary to typhoid ileal perforation: Assessment of severity using modified APACHE II score. Indian J Surg, 2005; 67(1):29-33.
12. Shah AA, Wani KA, Wazir BS;The ideal treatment of the typhoid enteric perforation-resection anastomosis. Int Surg, 1999; 84(1):35-38.
13. Eggleston FC, Santoshi B; Typhoid perforation: choice of operation. Br J Surg, 1981; 68(5):341-342.
14. Bakx R, Busch OR, Bemelman WA, Veldink GJ, Siors JF, van Lanschot JJ; Morbidity of temporary loop ileostomies. Dig Surg, 2004; 21(4):277-281.
15. Leong AP, Londono-Schimmer EE, Phillips RK; Life-table analysis of stomal complications following ileostomy. Br J Surg. 1994 May; 81(5):727-729.
16. Pandey A, Kumar V, Gangopadhyay AN, Upadhyaya VD, Srivastava A, Singh RB; A pilot study on the role of T- Tube in typhoid ileal perforation in children. World J Surg, 2008; 32(12): 2607-2611.
17. Prasad PB, Choudhury DK, Prakash O; Typhoid perforation treated by closure and proximal side-to-side ileo-transverse colostomy. Journal of the Indian Medical Association, 1975;65(11):297-299.