

Case Report

Trocar Site Hernia after Laparoscopic Ovarian Cystectomy: A Case Report and Literature Review

Dr.Shanta B Patil¹, Dr.Dharmaprakash N K², Dr.Vinayak Ingalalli³

¹Associate professor, Department of Surgery, M.R. Medical College, Kalaburagi

^{2,3}PG student in General Surgery, M.R. Medical College, Kalaburagi

*Corresponding author

Dr.Dharmaprakash NK

Email: dhasha88@gmail.com

Abstract: The field of surgery has been revolutionised with the introduction of laparoscopy. Though it is widely accepted and practised it is not devoid of complications. One such rare complication is port site hernia. We report the case of a 36-year old woman who underwent emergency explorative laparotomy on 13th postoperative day after laparoscopic ovarian cystectomy. Surgery showed a small bowel herniation through the 12mm trocar incision site at umbilicus which was adherent, viable and had to be released, and then hernia orifice repaired. Trocar Site Hernia(TSH) can present in immediate postoperative period or later. Symptoms depend on whether hernia contains omentum or bowel and an emergency surgical approach is often required. It is necessary to repair the fascial and peritoneal layers to prevent port site hernia. High index of suspicion, prompt investigation and early intervention may reduce unfavorable events.

Keywords: Trocar site hernia, laparoscopic ovarian cystectomy, laparotomy

INTRODUCTION

With the introduction of laparoscopy, surgical practice has been revolutionised, and an increasing number of complex procedures are being performed using this technique. Benefits include decreased postoperative pain, improved cosmesis, quicker return to normal activity, and less postoperative complications. However a rapid expansion in the volume and complexity of laparoscopic surgery has parallelly increased accompanying complications, many of which are specific to abdominal access. One such rare complication is the development of port site hernias, which is associated with significant morbidity [1-7]. Visceral herniation into the abdominal trocar entry sites is occasionally mentioned, but seldom reported. We hereby report one such rare case which presented in our hospital in acute form.

CASE REPORT

We report the case of a 36 year old woman who presented to the emergency department with pain abdomen 12 days, vomiting 12 days following laparoscopic ovarian cystectomy done at a different centre 13 days ago. History revealed that the patient developed pain abdomen on postoperative day 1 following laparoscopic procedure, which was sudden in onset, gradually increasing in severity, spasmodic in nature and more around the umbilical region. This was followed by non-projectile vomiting, multiple episodes

in a day, containing ingested material and making the patient intolerable to oral feeds. Patient was reassured about the symptoms and discharged but the symptoms did not subside. She had constipation for the past 12 days with infrequent passage of little hard stools. At presentation the patient was tachycardic with pulse rate 110/min, BP was normal 130/90mmHg. Examination revealed 3 recent small scars of previous laparoscopic procedure: one at umbilicus and one in each flank. Abdomen was non-distended, soft and there was no visible or palpable swelling. Abdomen was diffusely tender with maximum tenderness in the epigastric and umbilical region, with no guarding or rigidity. Severe tenderness precluded the detailed examination of port sites and fascial defect or cough impulse could not be appreciated. Abdomen was tympanic on percussion. Bowel sounds were present on auscultation. USG abdomen revealed herniation of part of the bowel wall through an umbilical defect. Erect X-ray abdomen showed few air fluid levels with dilated small bowel loops suggestive of intestinal obstruction. The patient was posted for emergency exploratory laparotomy on the same day. Per operatively a small bowel herniation through the umbilical 12 mm trocar incision site was seen (Figure 1); the antimesenteric border with circumference of jejunum was adherent but viable and had to be released (figure 2, 3). The hernia orifice was repaired in separate layers for peritoneum and fascial

defects and abdomen closed in layers. Post operative period was uneventful.

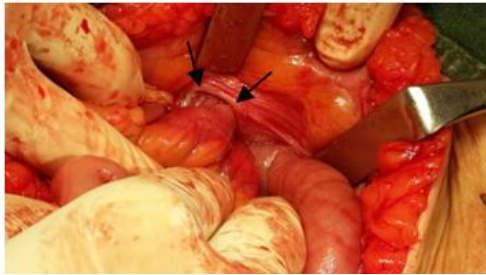


Fig-1: Arrow heads pointing at the edge of the hernia defect.

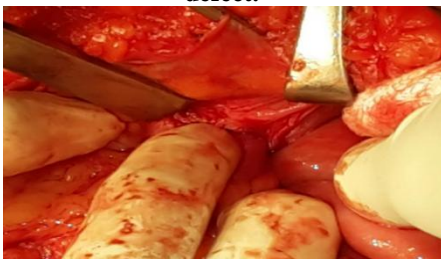

Fig-2: Releasing the adherent bowel by blunt dissection.

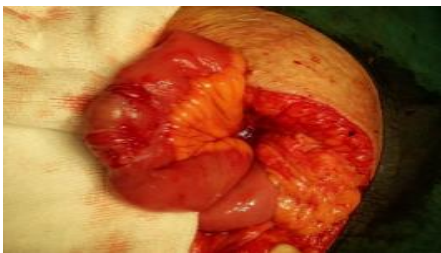

Fig-3: Viable bowel after complete release from adhesion.

DISCUSSION

Trocar site hernias have been reported since the early days of laparoscopy [2-4]. The incidence of trocar site hernia is estimated to be between 0.65% and 2.80% [4-6].

Risks for developing a trocar-site hernia include advanced age, increased BMI, smoking status, uncontrolled diabetes mellitus, port-site infection, peritoneal defect greater than the trocar size, midline insertion of the port especially near the umbilicus, excessive manipulation of the trocar site, site of trocar placement (lower quadrant port sites are more prone to hernia due to the absence of posterior rectus sheath), size of trocar, number of trocars used and type of trocar tip (bladed, nonbladed, radially expanding). The incidence of hernias is lower with radially expanding trocar sheaths.[6,8-16] Other risk factors are incomplete closure of fascia at the trocar site, the effect of a partial vacuum while port withdrawal and poor nutrition.

Three types of trocar site herniations have been described: (1) fascial and peritoneal separation

(associated with early presentation), (2) fascial separation with intact peritoneum (associated with a later presentation), and (3) herniation of the entire abdominal wall (seen at the time of trocar removal or shortly after surgery) [6].

Most hernias present within 10 days from the procedures, even though delayed hernias have been reported up to a year from the initial operation [1,5,6,17,18]. Another classification (Tonouchi) has been suggested depending on the time of presentation from the index operation.[6] The early onset type was within two weeks, most commonly with small bowel obstruction. The late onset type occurred after two weeks and had dehiscence of fascial plane with a sac consisting of peritoneum. The third category included special types of ventral abdominal hernia. The clinical course of port site hernia can be varied and depends on the extent and nature of the herniated content [1,6].

Patients can have a port-site hernia, but without bowel involvement and without symptoms. Once bowel or omentum gets involved, patients may present with gastrointestinal symptoms (nausea, vomiting, port-site pain, abdominal pain, fever). Either small or large bowel can be involved depending on the site of hernia. Bowel involvement can occur in the form of incarcerated bowel, bowel obstruction, or bowel evisceration. All of these are considered surgical emergencies that can present a few days to weeks after surgery. For patients who present with gastrointestinal symptoms after recent laparoscopic surgery, the differential diagnosis should include internal bowel hernia with or without incarceration/strangulation. The workup should include a computed tomographic scan (CT scan), which is usually helpful in the diagnosis [19].

Bowel evisceration is an obvious diagnosis and should be managed aggressively. The management of most of these hernias includes access to the hernia by extending the trocar site, laparoscopy or an explorative laparotomy and then reduction of the hernia and further surgeries based on the bowel viability [1,4,5,6,17,20].

Nezhat *et al.* [21] reported on 5,300 patients who underwent laparoscopy from January 1988 through June 1996. Ten women were evaluated for incisional hernias, and 11 hernias were found (incidence of 0.2%), omentum herniated in 7 cases and bowel herniated in 4 cases. In one case, the sigmoid epiploicae irreducibly herniated through the peritoneum and not the fascia. The hernia occurred through a 5-mm trocar incision site in 5 cases. Delayed recognition of bowel hernia through 5-mm trocar sites in adult patients was reported in 3 patients only.[21] Kader *et al.*[22] reported a 0.17% of port-site hernia in a multicenter report of 3,560 operative laparoscopies. The risk of hernia through a 12-mm trocar site (3.1%) was approximately 13-fold

greater than that for a 10-mm trocar site (0.23%). No comment on 5-mm port sites was given.

In a Bioke *et al.* [23] study and review of the literature, bowel herniation occurred when a ≥ 10 mm trocar site was used. Lateral ports were the most common sites of hernia.

A study done by Tanouchi *et al.* showed that 86.3% of hernias occurred in sites where the trocar diameter was 10 mm or more [6].

Tips to help prevent port-site hernias may include [19].

- Close all port sites despite trocar size, especially if the surgery was long and excessive manipulation of the trocars was done.
- Remove all ports under visualization.
- Deflate the abdomen carefully when removing ports. If this is not done, escaping CO₂ can draw the bowel or omentum into the port sites.
- Remove ports before deflation of CO₂. Deflating the CO₂ before trocar removal will compromise trocar removal under laparoscopic visualization.
- Examine all port sites carefully before closing the skin defect for any potential visceral herniation.
- Obese patients need close attention to closure. Blind closure of the trocar site risks failed closure or visceral injury.
- Slow return of bowel function should alert the physician to a possible bowel hernia.
- Tunnel drains rather than placing them through the same 5-mm port sites, because a few cases of bowel hernias have been reported when drains were removed [19].
- Fascial closure techniques using fascial closure device, suture carrier, Deschamps needle, port plugs are the other techniques described to reduce the chances of trocar site herniations [24-30].
- Some authors have also reported a lower incidence of hernias with the use of a paramedian incision and non bladed trocars, but these are not foolproof as has been shown by a recent case report [28-31].

CONCLUSION

In conclusion, it is necessary to repair the fascial and peritoneal layers to prevent port site hernia. High index of suspicion, prompt investigation and further intervention may reduce unfavorable events if a port site hernia is suspected. The knowledge of such a complication and its early diagnosis are important to avoid complications.

REFERENCES

1. Mayol J, Garcia-Aguilar J, Ortiz-Oshiro E, De-Diego Carmona JA, Fernandez-Represa JA; Risks of the minimal access approach for laparoscopic surgery: multivariate analysis of morbidity related to umbilical trocar insertion. *World J Surg*, 1997; 21: 529–533.
2. Schiff I, Nattolin F; Small bowel incarceration after uncomplicated laparoscopy. *Obstet Gynaecol*, 1974;43:674–675.
3. Bourke JB; Small intestinal obstruction from a Richter's hernia at the site of insertion of a laparoscope. *Br Med J*, 1977; 2:1393–1394.
4. Montz FJ, Holschneider CH, Munro MG; Incisional hernias following laparoscopy: a survey of the American Association of Gynecologic Laparoscopists. *Obstet Gynecol*, 1994;84:881–884.
5. Sanz-Lopez R., Martinez-Ramos C., Nunez-Pena J.R., Ruiz de Gopegui M., Pastor-Sirera L., Tamames-Escobar S. Incisional hernias after laparoscopic vs open cholecystectomy. *Surg Endosc*, 1999; 13: 922–924.
6. Tonouchi H, Ohmori Y, Kobayashi M, Kusunoki M; Trocar site hernia. *Arch Surg*, 2004; 139:1248–1256.
7. Moran DC, Kavanagh DO, Sahebally S, Neary PC. Incidence of early symptomatic port-site hernia: a case series from a department where laparoscopy is the preferred surgical approach. *Ir J Med Sci*, 2012; 181(4):463-466.
8. Freedman AN, Sigman HH; Incarcerated paraumbilical incisional hernia and abscess: complications of a spilled gallstone. *J Laparoendosc Surg*, 1995;5:189–191.
9. Boughey JC, Nottingham JM, Walls AC; Richter's hernia in the laparoscopic era: four case reports and review of the literature. *Surg Laparosc Endosc Percutan Tech*, 2003; 13:55–58.
10. Montz FJ, Holschneider CH, Munro MG; Incisional hernia following laparoscopy: a survey of the American Association of Gynecologic Laparoscopists. *Obstet Gynecol*, 1994; 84:881–884.
11. Hass BE, Schragar RE; Small bowel obstruction due to Richter's hernia after laparoscopic procedures. *J Laparoendosc Surg*, 1993; 3:421–423.
12. Kulacoglu IH; Regarding: Small bowel obstruction and incisional hernia after laparoscopic surgery: should 5-mm trocar sites be sutured? *J Laparoendosc Adv Surg Tech A*, 2000; 10:227–228.
13. Liu CD, McFadden DW. Laparoscopic port sites do not require fascial closure when nonbladed trocars are used. *Am Surg*, 2000; 66: 853–854.
14. Leibl BJ, Schmedt CG, Schwarz J, Kraft K, Bittner R; Laparoscopic surgery complications

- associated with trocar tip design: review of literature and own results. *J Laparoendosc Adv Surg Tech A*, 1999;9:135–140.
15. Bhoyrul S, Payne J, Steffes B, Swanstrom L, Way LW; A randomized prospective study of radially expanding trocars in laparoscopic surgery. *J Gastrointest Surg*, 2000; 4:392–397.
 16. Sanz-Lopez R, Martinez-Ramos C, Nunez-Pena JR, Ruiz de Gopegui M, Pastor-Sirera L, Tamames-Escobar S; Incisional hernias after laparoscopic vs open cholecystectomy. *Surg Endosc*, 1999; 13:922–924.
 17. Ashwini K; Trehan Richter's hernia following operative laparoscopy. *Gynaecol Endosc*, 1996;5:353–354.
 18. Abdel-Halim MRE, Higgs SM, Niayesh MH; Early port site hernia causing small bowel obstruction after laparoscopic appendectomy. *Grand Rounds*, 2007; 7:64–66.
 19. Nauman Khurshid, MD, Maurice Chung, MD, Terrence Horrigan, MD, Kelly Manahan, MD, John P. Geisler MD; 5-Millimeter Trocar-Site Bowel Herniation Following Laparoscopic Surgery. *JLS*, 2012; 16(2): 306–310.
 20. Rao P, Ghosh K, Sudhan D; Port site hernia: a rare complication of laparoscopy. *MJAFI*, 2008; 64:187–188.
 21. Nezhat C, Nezhat F, Seidman DS, Nezhat C; Incisional hernias after operative laparoscopy. *J Laparoendosc Adv Surg Tech A*, 1997;7:111–115.
 22. Kadar N, Reich H, Liu CY, Manko GF, Gimpelson R; Incisional hernias after major laparoscopic gynecologic procedures. *Am J Obstet Gynecol*, 1993;168:1493.
 23. Boike GM, Miller CE, Spirtos NM, Mercer LJ, Fowler JM, Summitt R, Orr JW; Incisional bowel herniations after operative laparoscopy: a series of nineteen cases and review of the literature. *Am J Obstet Gynecol*, 1995; 172(6): 1726-1733.
 24. Susmallian S, Ezri T, Charuzi I; Laparoscopic repair of access port site hernia after Lap-Band system implantation. *Obes Surg*, 2002; 12:682–684.
 25. Di Lorenzo N, Coscarella G, Lirosi F, Gaspari A; Port-site closure: a new problem, an old device. *JLS*, 2002; 6:181–183.
 26. Leibl BJ, Schmedt CG, Schwarz J, Kraft K, Bittner R; Laparoscopic surgery complications associated with trocar tip design: review of literature and own results. *J Laparoendosc Adv Surg Tech A*, 1999; 9:135–140.
 27. Kolata RJ, Ransick M, Briggs L, Baum D; Comparison of wounds created by non-bladed trocars and pyramidal tip trocars in the pig. *J Laparoendosc Adv Surg Tech A*; 1999; 9:455–461.
 28. Liu CD, McFadden DW; Laparoscopic port sites do not require fascial closure when nonbladed trocars are used. *Am Surg*.2000; 66:853–854.
 29. Shafer Z; Port closure techniques. *Surg Endosc*, 2007; 21:1264–1274.
 30. Moreno-Sanz C, Picazo-Yeste JS, Manzanera-Díaz M, Herrero-Bogajo ML, Cortina-Oliva J, Tadeo-Ruiz G; Prevention of trocar site hernias: description of the safe port plug technique and preliminary results. *Surg Innov*; 2008; 15:100–104.
 31. Patel MS; Laparoscopic Port Site hernia at a 12 mm non-bladed ethicon endopath Excel VersaStep™ trocar site. *World J Colorectal Surg*, 2010; 2(1): 3.