

## Case Report

**Adenocarcinoma of the Cervix: A Case Report**

M. El Mangad, K. Khabtou, K. Fichtali, M. Ennachit, M. El Kerroumi

Department of Gynaecology-Obstetrics B, Ibn Rochd University Hospital, Hassan 2 University, Faculty of Medicine and Pharmacy, Casablanca, Morocco

**\*Corresponding author**

M. El Mangad

Email: [fz.elmangad@gmail.com](mailto:fz.elmangad@gmail.com)

**Abstract:** The clear cell carcinoma of the cervix is a rare tumor. We present a new case with literature review. This is a patient of 40 years who consulted for metrorrhagia average abundance, yellowish vaginal discharge, burning urination and pelvic pain lasting for three months. The review found a tumor of the cervix 3 cm, burgeoning extended anterior vaginal fornix, classified IIa. The cervical biopsy showed a clear cell carcinoma of the cervix. The patient received brachytherapy, followed by an adénocolpo hysterectomy. The evolution was marked by a recurrence. The patient died thirty months after diagnosis.

**Keywords:** in utero exposure to DES, clear cell adenocarcinoma of the cervix, treatment

**INTRODUCTION:**

Adenocarcinomas account for 5 to 25% of cervical carcinomas [1]. Currently, there is an increase in frequency, especially in young women (under 35 years). At least 50% of adenocarcinomas associated with CIN or carcinoma infiltrating epidermoid [4]. There is a close correspondence between the use of DES in utero and the appearance of clear cell adenocarcinoma [1]. HPV, including HPV 18, are found in virtually all adenocarcinomas.

**CASE REPORT**

This is a patient 40 who had consulted for symptoms made of medium bleeding abundance, yellowish vaginal discharge, burning of voiding and pelvic pain lasting for three months. The gynecological examination had found a tumor of the cervix 3 cm, burgeoning with involvement of the anterior vaginal fornix, classified IIa according to the classification of the International Federation of Gynecology and Obstetrics (FIGO). A biopsy of the neck, it was a clear cell carcinoma of the cervix. The pre-therapeutic assessment was unremarkable. The patient received utero-vaginal brachytherapy dose 60Gray followed by extended-adénocolpo hysterectomy. Histological examination of the surgical specimen has noted post-radiation alterations fibro-inflammatory neoplasm with no residual invaded lymph node taken among the new. Postoperative radiotherapy was planned but the patient was lost sight of. The evolution was marked by the appearance of a huge centro-pelvic recurrence involving bone and retro-peritoneal two years after the end of treatment. After a course of chemotherapy (5-fluorouracil and Platamine), the patient died from progressive

continuation of his illness and this thirty months after diagnosis.

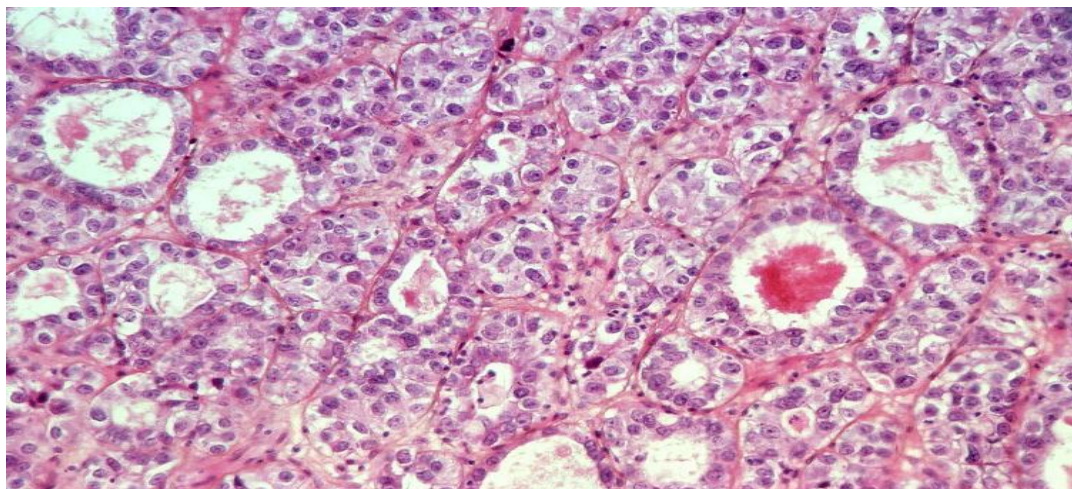
**DISCUSSION:**

The clear cell adenocarcinoma has a frequency of 4 to 20% [2]. It most often occurs at a young age: with an average of 22 years and extremes of 7-43 years [3]. If exposure in womb to DES: the average age is 20.8 and extremes of 15-28 years. In the series of Hanslar, DES was implicated in 57.7% of cases. The DES would be in the girl by the immune system depression with reduced response of the cells "killer". A second hypothesis involves the product or its metabolites in cell damage during embryogenesis fetogenesis or more with increased risk of degeneration into adenocarcinoma [1]. Promoting the role of "Human Papillomavirus" in the genesis of cervical cancer is explained by the production of proteins that inactivate tumor suppressor genes and facilitate their development [2].

No studies demonstrated an increased risk through the use of oral contraception. However; accelerating the transition from dysplasia to carcinoma in situ and a higher risk of progression has been reported [4]. There is a positive correlation between smoking and sexual factors. Cancer incidence is higher in women who had sex before age 17 years [6]. Sexually transmitted infections are also implicated. The delay between the onset of symptoms and the diagnosis ranged from 1 month to 12 months with a mean of 5 months [7]. The revealing symptoms are dominated by bleeding; followed by dyspareunia; leucorrhoea [7]. The data of the clinical examination of cervical

adenocarcinoma Clear cell are the same as those of the general cervical cancer [8]. The Pap smear can highlight cellular abnormalities in the cervical epithelium. Colposcopy with the help of staining lugol

can locate the seat of the lesions; to specify the degree of atypical transformation and direct biopsies to confirm the diagnosis.



**Fig. 1: Histology of adenocarcinoma invasive clear cell (magnification x100)**

At the end of staging; the tumor may be classified according to the classification of the International Federation of Gynecology and Obstetrics (FIGO). In 85% of cases, patients with stage I or II at diagnosis [4]. Macroscopically, about half of the cases appear polypoid, exophytic papillary. On the microscopic level, a variable glandular differentiation is observed according to the degree of differentiation. The diagnosis of infiltration is mainly based on the architecture and layout of glands. It can be associated with other lesions vaginal adenosis (50% of cases) or cervicovaginal abnormalities (20% of cases). [13]. This extension is comparable to that of squamous cell carcinomas. The local extension and lymph node metastases and visceral seem remote, however earlier [15]. After intracavitary treatment, it is more common to find a residual tumor with squamous cell carcinoma [14]. Treatment depends on the stage of the disease. The treatment of early stages most often call for surgery alone, or radio surgical association, even to the exclusive RT, with identical results. In these early stages, it is acceptable to adapt the treatment depending on the age of the patient and in particular fertility desire and power in very specific cases preserve ovarian function and even fertility [6, 11]. The existence of a more advanced stage tumor contraindicated pure surgical treatment and all operations to preserve fertility, and a number of surgical approaches, such as vaginal or laparoscopic surgery. Several parameters can influence the prognosis stage, lymph node metastasis, tumor mass, depth of infiltration, vascular invasion, histological type, histological grade, aneuploidy [9]. Overall, survival was lower than squamous cell carcinomas [10]. Clear cell type could be more pejorative, especially if it is not related to DES [12]. Screening for cervical cancer is effective through the practice of the Pap smear. The

HPV vaccination and screening are the two key components in prevention.

#### CONCLUSION :

The clear cell adenocarcinoma is rare; Its epidemiology is closely related to the use of DES; however, this factor is not responsible alone carcinogenesis of this cancer; This uses of Other factors, both exogenous qu'endogène; in the process of developing clear cell adenocarcinoma of the cervix. The clinical picture and the staging is not different from the rest of cervical cancers On the therapeutic plan; Conservative treatment is indicated for limited stages, especially since the target population is young Prognosis forms upon exposure to DES in utero is better compared to other cases.

#### REFERENCES:

1. Tomographie par émission de positons au (18F)-fluorodésoxyglucose dans les cancers du col utérin : évaluation ganglionnaire et valeur pronostique/prédictive des données de la tumeur primitive Cancer/Radiothérapie, 2012; 15(8) : 699-708.
2. Cancer du col utérin invasif et grossesse : cinq cas observés à Lille de 2002 à 2009. Évaluation des pratiques en référence aux recommandations françaises Journal de Gynécologie Obstétrique et Biologie de la Reproduction, 2011 ; 40(6) : 514-521.
3. Adénocarcinomes du col utérin. Difficultés du diagnostic des formes précoces et corrélations cyto-colpo-histologiques Annales de Pathologie, 2011 ; 31(5) :S107-S108.
4. Traitement des adénocarcinomes in situ du col utérin Annales de Pathologie, 2011 ; 31(5) : S109-S110

5. Querleu D, Leblanc E. Rôle de la coelioscopie et nouveaux concepts dans le traitement des cancers du col aux stades I et II. *Encycl Méd Chir (Elsevier SAS, Paris), Gynécologie*, 605-A-70, 2008 ; 5.
6. Fotiou S, Rodolakis A. Récurrence du cancer du col : facteurs de risque et traitement. *Encycl Méd Chir (Elsevier SAS, Paris), Gynécologie*, 605-A-85, 2007 ; 5.
7. Zhang Y, Shen K, Gao JS, Wu M, Huang HF, Pan LY, *et al.*; Clinical features and treatment of cervical malignant tumor in young women. *Zhongguo Yi Xue Ke Xue Yuan Xue Bao* 2006;25:391-5.
8. Rouanet JP, Filhastre M, Mares P, Maubon A ; Anatomie IRM du pelvis féminin. Principales applications en pathologie gynécologique. Montpellier: Sauramps médical; 2005.
9. Hricak H, Gatsonis C, Chi DS, Amendola MA, Brandt K, Schwartz LH, *et al.*; Role of imaging in pretreatment evaluation of early invasive cervical cancer: results of the intergroup study American College of Radiology Imaging Network 6651-Gynecologic Oncology Group 183. *J Clin Oncol* 2005; 23:9329-37.
10. Grahek D, Barranger E, Darai E, Uzan S, Talbot JN; Intérêt de la tomographie par émission de positons au fluorodésoxyglucose dans le diagnostic, le bilan d'extension et la recherche de récurrence des cancers gynécologiques et mammaires. *Gynecol Obstet Fertil* 2005;33: 371-81.
11. Jackson KS, Das N, Baik R, Lopes AD, Godfrey KA, Hatem MH, *et al.*; Laparoscopically assisted radical vaginal hysterectomy vs radical abdominal hysterectomy for cervical cancer: a match controlled study. *Gynecol Oncol* 2004; 95:655-61.
12. Steed H, Rosen B, Murphy J, Laframboise S, de Petrillo D, Covens A; A comparison of laparoscopic-assisted radical vaginal hysterectomy and radical abdominal hysterectomy in the treatment of cervical cancer. *Gynecol Oncol* 2004;93:588-93.
13. De la Motte Rouge T, Pautier P, Hamy AS, Duvillard P, Bruna A, Castaigne D, *et al.*; Medical treatment of metastatic or recurrent cancer of the cervix. *Bull Cancer* 2003; 93:263-70. C.
14. Classe JM, Rauch P, Rodier JF, Morice P, Stoeckle E, Lasry S, *et al.*; Surgery after concurrent chemotherapy and bradytherapy for the treatment of advanced cervical cancer: morbidity and outcome: result of a multicenter study of the GCCLCC. *Gynecol Oncol* 2002; 102.