

Case Report

## Giant Inguinal Hernia- A Great Escape From Second Abdomen: Report of a Case and review of different surgical techniques

Dr. Ashok Kumar<sup>1</sup>, Dr. Pukh Raj Choudhary<sup>2</sup>, Dr. Ajay Gandhi<sup>3</sup>, Dr. Mahendra Jalthania<sup>4</sup>, Dr. Sitaram Gothwal<sup>5</sup>

<sup>1</sup>Associate Professor, <sup>2</sup>Final Year PG, <sup>3,4</sup>Assistant Professor, <sup>5</sup>Professor, S.P. Medical College, Bikaner, Rajasthan, India

**\*Corresponding author**

Dr. Ashok Kumar

Email: [drashokraj1@yahoo.co.in](mailto:drashokraj1@yahoo.co.in)

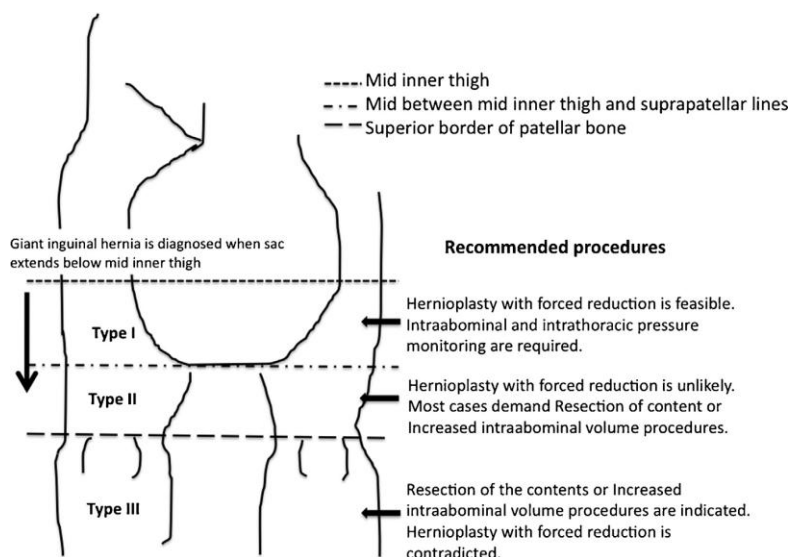
**Abstract:** Inguinal hernia is one of the most common surgical diseases. Giant inguinal hernia is defined as an inguinal hernia that extends below the midpoint of inner thigh when the patient is in standing position. Giant inguinal hernia is more unusual and significantly challenging in terms of surgical management. The main challenging part is that of returning herniated viscera to an abdominal cavity which is accustomed to being empty, also known as loss of domain. In our case, we present a case of Type-III giantinguino-scrotal hernia which was repaired by hernioplasty after resection of herniated contents. There were several repair techniques such as resection of the content and increased intra-abdominal volume procedure. Many key factors for management of the giant inguinal hernia were discussed. A new classification of the giant inguinal hernia was described. Surgical repair for the giant inguinal hernia is challenging and correlated with significant morbidity and mortality due to increased intra-abdominal pressure.

**Keywords:** Inguinal hernia, abdominal cavity, Surgical repair

### INTRODUCTION

Hernia is one of the most common surgical disease in general practice, and its repair was originated in our ancient era[1]. Giant inguino-scrotal hernias are

uncommon. They are defined as hernias extending below midpoint of the inner thigh in the standing position [2]. Giant inguinal hernias are classified in three types by AttthaphornTrakarnsagna et al[3].



**Fig. 1: New classification of giant inguinal hernia and recommended procedure**

They usually present with significant decrease in patients' quality of life, including difficulties with mobility, retention of urine, bowel obstruction and scrotal skin ulceration. Reduction of hernial contents may produce alterations in intra-abdominal and intra-

thoracic pressures, precipitating cardiac or respiratory failure [4, 5]. These kinds of hernias also carry the risk of wound dehiscence and hernia recurrence is also greater with forced closure with a recurrence rate of up to 30% [6]. No treatment is adopted as a standard

procedure for management of giant hernia, it includes from advanced laparoscopic procedure to conventional open hernia repair. Choosing a particular procedure is very difficult and decision has to be made intra-operatively. Various techniques include loss of abdominal domain, phrenectomy, creation of a ventral hernia with repair using Marlex mesh and scrotal skin flaps and preoperative artificial pneumoperitoneum [6, 7,8].

### CASE REPORT

A 75-year-old man presented with over 30-year history of a right inguino-scrotal hernia which eventually became irreducible with increasingly difficulty in micturition. His quality of life had become significantly affected over the past few years when he had recurrent episodes of acute urine retention that required catheterization. The patient also had significant issues with his mobility. Examination revealed a massive right inguino-scrotal hernia that descended to below the level of his knees in the standing position. There was no evidence of inflammation, excoriation or ulceration of the scrotal skin and no focal tenderness over the hernia. The blood investigations showed Hb: 11.7g/dl, TLC: 12,100/cu.mm. RBS-94mg, BU-68mg, Creatinine-2.2mg, LFT was within normal limit.

Intra-operatively we found that the hernial sac is containing most of the omentum, right colon and small bowel with only the proximal jejunum and duodenum lying within the abdomen. Hernial sac was also containing right ureter and retroperitoneal fat. Dense inter-bowel adhesions were found. During adhesiolysis we experienced with an iatrogenic perforation at terminal ileum and we had decided to respect the terminal ileum with caecum and part of ascending colon along with omentectomy and end to end ileo-ascending anastomosis. Anastomosed part along with remaining ileum and transverse colon was repositioned back in peritoneal cavity. Ureter was also repositioned. Redundant sac was excised. Proline mesh was applied in inguinal canal. Abdominal drain and scrotal drain were put to avoid post-operative collection.

Postoperatively, the patient had continuing respiratory support in high dependency unit, with physiotherapy and scrotal support. Recovery was satisfactory with early return of bowel movement and mobilization. He had no significant postoperative complications and was discharged home with an indwelling urinary catheter on postoperative day 08.

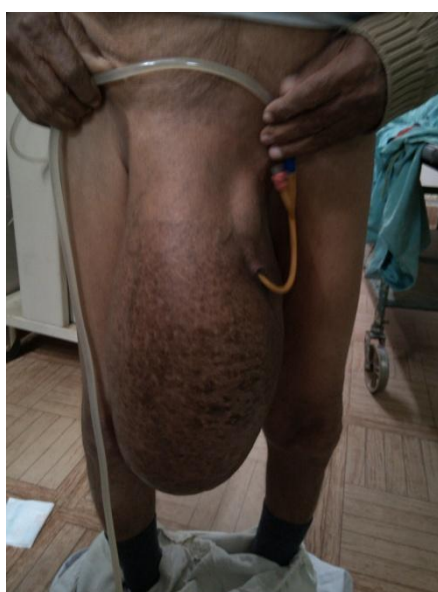

Fig. 1: Pre-operative

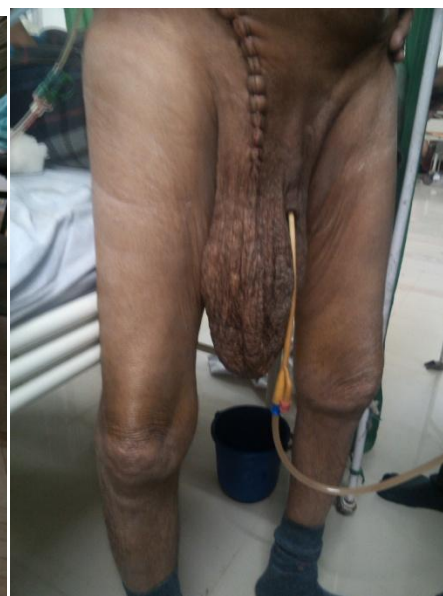

Fig. 2: Post-operative

### DISCUSSION

In high-income countries, the diagnosis of inguinal hernia is usually made early, when the patient notices the development of swelling or groin pain. Given the potential hernia strangulation, surgical correction is often carried out without delay. Consequently, giant inguino-scrotal hernias have become extremely rare and are currently seen in clinical practice only after years or even decades of self-neglect [10,11]. In addition to the classical complications of inguinal hernias, the massive size of giant hernias often causes difficulty in walking, sitting, or lying down, with

mobility dramatically restricted. The penis may be buried inside the scrotum causing dribbling of urine over the scrotal skin, which is already congested by lymphatic and venous edema, leading to excoriation, ulceration, and secondary infection [12, 13]. Patients may also complain of difficulty in voiding and recurrent urinary tract infections, especially when the bladder is contained within the hernia sac. These specific problems severely impair the patient's quality of life, with considerable psychological and social impact [14]. Giant inguino-scrotal hernias always present as a challenging surgical problem and are associated with

high morbidity and mortality due to returning of herniated viscera to an abdominal cavity which is accustomed to being empty, also known as loss of abdominal domain.[7,9]. With careful planning, and multi-disciplinary team approach, appropriate resection of omentum and bowel, presents as a good surgical alternative to address the problem of loss of domain in those patients with less morbidity and mortality.

#### **Certain Key factor in the management of giant inguinal hernia**

Always Preoperative colonic evaluation should be considered. Statistics indicates that colon cancer is detected by preoperative barium enema in 1.8-2.5% of patients who are older than 40 years and have undergone inguinal hernia repair.[15,16,17]. Moreover, as colonic resection may be required as a part of treatment of giant inguinal hernia. From our point of view, barium enema is more of a preferred method than colonoscopy in the colon within hernia sac, is associated with high risk of colonic perforation [18].

Bowel preparation should be considered in all cases, especially the ones where hernia sac extends beyond the imaginary line between superior borders of patellar bone. Colonic resection may be necessary as a part of the treatment. [3].

Attempts must be made to prevent to excessive intra-abdominal and intrathoracic pressure caused by reduction of massive contents in to limited domain of abdominal cavity [3].

Spermatic cord can be easily stretched as a result of long standing of hernia. In some cases the spermatic cord is twisted, causing testicular atrophy. Therefore, preoperative testicular examination should be performed in all patients and orchidectomy may be needed to prevent undesirable events[3].

Scrotal hematoma is commonly found after the operation. Dense adhesion is usually detected due to the chronicity of the disease. Extensive lysis of adhesion can cause hematoma. Given these circumstances, a closed drainage system should be implemented. It is important to note, though, that such system cannot always prevent postoperative hematoma. Meticulous hemostasis and close observation are the most important steps towards prevention and early detection [3].

An informed consent is needed to cover all possible operative procedures because final decision will be made intra-operatively. All of these options must be explained to the patient as well as their family members[3].

#### **Intra-abdominal hypertension**

Intra-abdominal hypertension can develop because of the disproportion of abdominal domain of

the large amount of content in the hernia sac. The high rate of mortality is clearly observed following forced reduction of giant inguinal hernia [19]. Intra-abdominal hypertension can immediately develop after reduction of contents or later in the postoperative period due to ileus of the bowel.

Excessive increase of intra-abdominal pressure generally affects regional blood flow in abdominal cavity, other organs outside abdomen, as well as the cardiovascular and respiratory system. Intra-thoracic pressure is raised as a result of cephalic displacement of diaphragm through the increase of intra-abdominal pressure[20].

Venous return, cardiac output and blood pressure are decreased by this phenomenon. Moreover, increase of intra-thoracic pressure causes increase of inspiratory rate and mean airway pressure, while tidal volume and pulmonary compliance are reduced [20]. Therefore, vital signs and urine output should be closely monitored. Respiratory support may be needed until ileus starts resolve[21].

According to previous literatures, hernioplasty with forced reduction is feasible for the treatment of giant inguinal hernias extending below mid inner thigh but above imaginary line at lower thigh, the line between the middle point of inner thigh and suprapatellar. [22, 23] Intra-abdominal and intra-thoracic pressure must be closely observed after the reduction as mentioned above

Most hernial sacs, which extend below the imaginary line at lower thigh but above the line between superior borders of patellar bone, require additional procedures rather than simple hernioplasty alone[21,24,25], except only one case reported by Coetzee et al[24]. The additional operations were introduced to prevent intra-abdominal hypertension. In cases that the hernial sac extends below the line between superior borders of patellar bone, additional procedures are almost always needed in addition to forced reduction and simple hernioplasty. The two major techniques required are resection of hernia contents and intra-abdominal volume increase procedure.

#### **Surgical techniques**

##### **Resection of the contents**

Giant inguinal hernia is a type of hernia with massive contents inside the hernia sac and limited domain of abdominal cavity. The surgeon's decision regarding the prevention of intra-abdominal hypertension is a crucial stage of overall management. Forced reduction is feasible in cases with mild form of this disease [type 1]. Resection or debulking of the contents is a portion to prevent intra-abdominal hypertension, with resected organs usually being the colon, the small bowel, or the omentum. The benefit is

that it is a single stage operation. The limitations are rate of the failure of anastomosis, the changing of bowel function and the infection of prosthesis from resection of the bowel[3].

#### **Intra-abdominal volume increase procedure**

Loss of domain of intra-abdominal cavity is one of the main problems in the management of giant inguinal hernia. Forced reduction and simple hernioplasty may not be the appropriate procedure for moderate and severely enlarged giant inguinal hernia [type II and III]. Several techniques were proposed to avoid bowel resection, including preoperative progressive pneumoperitoneum and lengthening of the abdominal wall by mesh or rotation of viable tissue [3]. The enlargement of the peritoneal cavity by progressive preoperative pneumoperitoneum has been highly recommended in the past [8, 9], but usually it causes expansion of the thin hernia sac rather than the contracted abdominal cavity, requires prolonged preoperative hospitalization, and fails several times.

#### **Preoperative progressive pneumoperitoneum**

Moreno first reported the application of preoperative progressive pneumoperitoneum to ventral hernias [34] and this technique was subsequently applied to giant inguinal hernia repair[35]. The concept is to preoperatively ensure adequate room in abdominal cavity by pneumoperitoneum before reduction of the hernial contents. The contraindications are abdominal infection, decompensated cardiac condition, small neck of the hernia and strangulation. This technique involves gradually insufflating the gas into abdominal cavity via placed catheter in situ, usually increments from 500 cc to 2000 cc per day over 7-14 days[19,36], from previous literature, gas choices include natural ambient air oxygen[19], carbon dioxide and nitrous oxide[37].The contraindication are abdominal infection,decompensated cardiac conditions, small neck of hernia and strangulation[19]. The limitations of this technique are prolonged preoperative hospitalization, spread of air in to hernia sac and technical unsuccessful [3]

#### **Rotation of viable tissue**

Rotation of viable tissue is the other technique to increase intra-abdominal volume by increasing surface of the abdominal wall. Several techniques have been proposed in the literatures,For scrotal skin flap [9, 29], midline anterior abdominal defect was created to increase space of abdominal cavity. Inguinal hernia orifice and midline anterior abdominal wall defect was repaired by prosthetic mesh, then cover midline mesh with myocutaneous scrotal flap. A modification was proposed by using hernia sac as peritoneal flap and cover with mesh on top at anterior midline defect[37]. Similarly, tensor fascia lataemusculocutaneous flap was alternatively used to cover mesh at anterior abdominal wall defect[21]. Component separation technique is one used to advanced rectus muscle by freeing external

oblique musclefrom internal oblique muscle[25]. The advantage of rotation of viable of tissue is that is a single stage procedure but surgical expertise is required to prevent complication.

In our patient, the small bowel with its mesentery, cecum with ascending colon, and greater omentum were found in a right-sided inguinoscrotal hernia, together with dilated right ureter. Such a case has not been reported in the medical literature to date, to the best of our knowledge.

Repair of a giant inguinal hernia is a real challenge, even for experienced surgeons. Abrupt and forced reduction of massive contents of the hernia sac into the limited space of the peritoneal cavity leads to a sudden increase of intraabdominal and intrathoracic pressures. This can cause abdominal compartment syndrome, resulting in compromised respiratory and cardiac function due to splinting of the diaphragm and reduction of venous return [7]. This syndrome is associated with a worsening of morbidity and mortality rates. In addition, reintroduction of the intestine into the abdomen may also cause intestinal obstruction.

#### **REFERENCES**

1. Lau WY; History of treatment of groin hernia. *World J Surg.*, 2002; 26(6):748–759.
2. Hodgkinson DJ, McIlrath DC; Scrotal reconstruction for giant inguinal hernias. *SurgClin North Am.*, 1980;64:307–313.
3. Trakansagna A et al; Giant inguino-scrotal Hernia: Report of a case and reviews of surgical techniques. *international journal of Surgery Case Reports*, 2014; 5: 868-8727.
4. Mendez-Fernandez MA, Hollan C, Frank DH, Fisher JC; The scrotal myocutaneous flap. *Plast Reconstr Surg.*, 1986;78:676–8.
5. Tournoff ASW;Phrenectomy as aid to repair of large abdominal hernias. *JAMA*, 1954;154:330–33.
6. Stoppa RE; The treatment of complicated groin and incisional hernias. *World J Surg.*, 1989;13:545–54.
7. Forrest J; Repair of massive inguinal hernia.–8 *Arch Surg.*, 1979;114:1087.
8. Moreno IG; The rational treatment of hernias and voluminous chronic eventrations: preparation with progressive pneumoperitoneum. In: Nhylus LM, Condon RE, eds. *Hernia*, 2nd edn. Philadelphia: J.B. Lippincott Co., 1978;536–50.
9. Merrett ND, Waterworth MW, Green MF; Repair of giant inguinoscrotal inguinal hernia using marlex mesh and scrotal skin flaps. *Aust N Z J Surg.*, 1994;64:380–83.
10. Panagiotakis GI, Spyridakis KG, Chatziioannou MN, Kontopodis NG, Kandyllakis SE; Repair of an inguinoscrotal

- hernia containing the urinary bladder: a case report. *J Med Case Rep.*, 2012;6:90.
11. Patsas A, Tsiaousis P, Papaziogas B, Koutelidakis I, Goula C, Atmatzidis K; Repair of a giant inguinoscrotal hernia. *Hernia.*, 2010;14:305–7.
  12. Dinesh HN, Kumar CDJ, Shreyas N; Giant inguinoscrotal hernia repaired by Lichtenstein's technique without loss of domain - a case report. *J ClinDiagn Res.*, 2014;8:ND07–8.
  13. Karthikeyan VS, Sistla SC, Ram D, Ali SM, Rajkumar N; Giant inguinoscrotal hernia—report of a rare case with literature review. *Int Surg.*, 2014;99:560–4.
  14. Petersen LF, Luu MB; Giant inguinal scrotal hernia containing the sigmoid colon. *Am Surg.*, 2014;80:e185–6.
  15. Terezis NL, Davis WC, Jackson FC; Carcinoma of the colon associated with inguinal hernia. *N Engl J Med.*, 1963;268:774–776.
  16. Maxwell JW, Davis WC, Jackson FC; Colon carcinoma and inguinal hernia. *SurgClin North Am.*, 1965;45(5):1165–1171.
  17. Day T, Ferrara JJ; Preoperative barium contrast enema in patients with inguinal hernia. *South Med J.*, 1986;79(11):1339–1341.
  18. Leisser A, Delpre G, Kadish U; Colonoscopy incarceration: an avoidable event. *GastrointestEndosc.*, 1990;36(6):637–638.
  19. Barst HH; Pneumoperitoneum as an aid in the surgical management of giant inguinal hernia. *Br J Surg.*, 1972;59(5):360–364.
  20. Papavramidis TS, Marinis AD, Pliakos I, Kesisoglou I, Papavramidou N; Abdominal compartment syndrome-intraabdominal hypertension: defining, diagnosing and managing. *J Emerg Trauma Shock*, 2011;4(2):279–291.
  21. Mehendale FV, Taams KO, Kingsnorth AN; Repair of a giant inguinoscrotal hernia. *Br J Plast Surg.*, 2000;53(6):525–529.
  22. Tsutsumi N, Guntani A, Rikimaru T, Watanabe A, Kohnoe S; Giant inguinal hernia containing right colon repaired using the prolene hernia system. *ANZ J Surg.*, 2008;78(3):219.
  23. Tay E, Gray E, Morgan MW; Repair of a massive inguinal hernia. *J R Soc Med.*, 1999;92(11):586–587.
  24. Coetzee E, Price C, Boutall A; Simple repair of a giant inguinoscrotal hernia. *Int J Surg Case Rep.*, 2011;2:32–35.
  25. Valliattu AJ, Kingsnorth AN; Single-stage repair of giant inguinoscrotal hernias using the abdominal wall component separation technique. *Hernia*, 2008;12(3):329–330.
  26. Kovachev LS, Paul AP, Chowdhary P, Chowdhary P, Filipov ET; Regarding extremely large inguinal hernias with a contribution of two cases. *Hernia*, 2010;14(2):193–197.
  27. Monestiroli M, Bondurri A, Gandini F, Lenna G, Vellini S, Danelli P; Giant inguinoscrotal hernia. *Tech Coloproctol.*, 2007;11(3):283–285.
  28. El Saadi AS, Al Waden AH, Hamerna S; Approach to a giant inguinoscrotal hernia. *Hernia*, 2005;9(3):277–279.
  29. Ek EW, Ek ET, Bingham R, Wilson J, Mooney B, Banting S; Component separation in the repair of a giant inguinoscrotal hernia. *ANZ J Surg.*, 2006;76(10):950–952.
  30. Imisairi AH, Hadi SM; Giant inguinal hernia. *ANZ J Surg.*, 2011;81(6):488.
  31. King JN, Didlake RH, Gray RE; Giant inguinal hernia. *South Med J.*, 1986;79(2):252–253.
  32. Patsas A, Tsiaousis P, Papaziogas B, Koutelidakis I, Goula C, Atmatzidis K; Repair of a giant inguinoscrotal hernia. *Hernia*, 2010;14(3):305–307.
  33. Vasilliadis K, Knaebel HP, Djakovic N, Nyarangi-Dix J, Scahmidt J, Bucher M; Challenging surgical management of a giant inguinoscrotal hernia: report of a case. *Surg Today*, 2010;40(7):684–687.
  34. Moreno IG; Chronic eventrations and large hernias; preoperative treatment by progressive pneumoperitoneum; original procedure. *Surgery*, 1947;22(6):945–953.
  35. Connolly DP, Perri FR; Giant hernias managed by pneumoperitoneum. *J Am Med Assoc.*, 1969;209:71–74.
  36. Mayagoitia JC, Suarez D, Arenas JC, Diaz de Leon V; Preoperative progressive pneumoperitoneum in patients with abdominal-wall hernias. *Hernia*, 2006;10(3):213–217.
  37. El Dessouki NI; Preperitoneal mesh hernioplasty in giant inguinoscrotal hernias: a new technique with dual benefit in repair and abdominal rooming. *Hernia*, 2001;5(4):177–181.