

Bilateral Asynchronous Spontaneous Achilles tendon Rupture in Alkaptonuria: A Case Report

Ammar Eltayeb Mahdi Awad^{1*}, Hozifa Mohammed Ali Abdelmaged², Hassan Elshami Hassan Mohamed Ahmed³, Adnan Ayman Mohammed Adnan Alnaser⁴, Saad Elnour Hag Eltayeb Mukhtar⁵

¹Foot and ankle consultant, Omdurman teaching hospital, Fellowship foot and ankle surgery UM /MALAYSIA, MD ortho /Sudan

²Orthopedic Resident, Omdurman Teaching Hospital; Teaching assistant at Elzaeim Elazhary University-Sudan

³Omdurman Islamic University Omdurman, Sudan

^{4,5}Orthopedic Resident, Omdurman Teaching Hospital Sudan

DOI: [10.36347/sjams.2020.v08i12.001](https://doi.org/10.36347/sjams.2020.v08i12.001)

Received: 18.11.2020 | Accepted: 30.11.2020 | Published: 03.12.2020

*Corresponding author: Ammar Eltayeb Mahdi Awad

Abstract

Case Report

Introduction: Alkaptonuria (AKU) is a rare autosomal recessive disorder result from a deficiency of homogentisate 1, 2 dioxygenase (HGD), and leading to the accumulation of homogentisic acid (HGA) in the tissue. The deposition of excess oxidized HGA in the connective tissues causes pigmentation (ochronosis) and degeneration of the joint (ochronotic arthropathy) and tendons (ochronotic tendinopathy). There is no effective therapy for this disorder a side of symptomatic treatment. **Case:** we report our 43-year-old male farmer, who presents with bilateral asynchronous spontaneous Achilles tendon rupture (5 months apart) with no history of trauma or drug use, nonspecific low back pain, and apparent black pigments in the sclera, with a positive family history of similar condition. **Diagnosis:** laboratory investigations revealed black urine upon long-standing. A blackish degenerative tendon found during the operation. In addition, the Intraoperative Histopathological study shows dark stains and fibrosis with presence of inflammatory cells consistent with Alkaptonuria. **Interventions:** debridement of the distal end of the tendon was done; repair was done with augmentation of repair by anchor suture to calcaneus. **Outcomes:** The patient recovered very well after the operation with the restoration of full activity.

Keywords: Alkaptonuria (AKU), homogentisic acid, ochronosis, Histopathological study.

Copyright © 2020 The Author(s): This is an open-access article distributed under the terms of the Creative Commons Attribution 4.0 International License (CC BY-NC 4.0) which permits unrestricted use, distribution, and reproduction in any medium for non-commercial use provided the original author and source are credited.

INTRODUCTION

Alkaptonuria (AKU) is a rare autosomal recessive disorder result from a deficiency of homogentisate 1, 2 dioxygenase (HGD); an intermediate enzyme in the phenylalanine and tyrosine degradation pathway within the liver, leading to an increase in the level of homogentisic acid (HGA) in the body [1]. Alkaptonuria caused by mutations within the HGD gene mapped to the human chromosome 3q21-q23 [2]. HGA is excreted in the urine (homogentisic aciduria) or oxidize and polymerize to Benzoquinoneacetate (BQA), which deposited in the connective tissues, also known as Ochronosis or within the joint (Ochronotic arthropathy). The other organs involved are the cardiovascular system, kidneys, skin, glands, tendons and ligaments, osteopenia, and fracture [3]. The worldwide prevalence of AKU is ranging from 1:200,000 to 1:1,000,000 births. The highest prevalence of the disease (1:19,000) was in Slovakia, the Dominican Republic and recently Jordan and India showing increase in incidence of AKU patients [2].

However, in Middle East and Africa there is about 120 reported case of AKU [4].

The earliest manifestation of AKU is black urine during childhood. Arthropathy, tendinopathy, and osteoporosis are the main musculoskeletal manifestations (Ochronotic osteoarthropathy) in AKU patients, especially at the third to fourth decade of life due to decreased renal excretion of the HGA with aging [5]. AKU characterized by early involvement and degeneration of articular cartilage, therefore misdiagnosed as osteoarthritis. Meanwhile, Kyphosis and scoliosis may appear as the disease progresses, resembling the presentation of Ankylosing spondylitis. Since the tendon has a high collagen content, HGA accumulates and binds irreversibly in the type I collagen, and polymerized to form a dark pigment, which gives a characteristic ochre or yellow-like appearance to the tissues. Furthermore, HGA inhibits collagen cross-linking, leading to a decrease in the integrity of collagen, and therefore increasing the risk of spontaneous rupture [6].

We aimed to demonstrate a unique rare case presented with a bilateral asynchrons spontaneous rupture of Achilles tendon. This report provides new aspect of information crucial for the study of this rare condition.

CASE REPORT

A 43-year-old male farmer presented to our casualty after a sudden onset of giving way, weakness, and mild pain in the back of the left ankle for Three days duration. The pain increased on walking, long-standing, and relieved by rest. He also complains of backache of long duration. He has no history of a direct injury, no history of fluoroquinolone, or steroid use recently. The patient has a history of Achilles tendon repair on the right side five months ago treated by a general surgeon. The patient mentioned that his brother has ruptured both Achilles tendon. Furthermore, children within the family carry black spots on their sclera, but they do not investigate for Alkaptonuria.

On clinical examination, the patient has dark pigmentation of the sclera in his eyes and ears (Figure 1) There was a diffuse swelling over the Achilles tendon area with a palpable defect (gap) over the tendon proximal to its insertion, and there were no external injuries (indicating rupture). The affected side was dorsiflexed in resting position compare to the unaffected side. The patient was unable to perform a single heel raise test on the affected side and loss of ankle plantarflexion on calf compression. He also had smooth kyphosis and reduced movement of the lumbosacral spine (Figure 2). On radiographic

examination, the lateral ankle radiographic showed Haugland deformity in the calcaneus. The x-ray of the lumbar spine (Figure 3) showed narrowing of the disc spaces with calcification and degenerative changes of intervertebral discs. Laboratory examination revealed that the patient's urine turned dark-black color upon standing for 24 hours (Figure 4). A diagnosis of Achilles tendon rupture was made and the patient planned for surgery.

We start surgical intervention with the patient placed in a prone position, a skin incision (L-shape) was performed. The Achilles tendon found avulsed from it is the insertion and the tendinous portion of the Achilles tendon showed black discoloration (figure 5). A biopsy from black tissues at the rupture site shows fibrous tissue fragments with foci of degeneration and mixed inflammatory cells infiltration with the presence of brown/ochre pigment deposition (Figure 6). Approximately >1 cm of the discolored Achilles tendon was excised. The Haglund's deformity and was excised. The distal end of the Achilles tendon was also debrided. With the foot plantarflexed, the tendon re-attached to the calcaneus using two titanium anchors 0.5 mm under image control (Figure 7). Finally, a long leg cast applied with the ankle in plantar flexion and the knee in 30 degrees of flexion. Three weeks postoperatively, all sutures were removed and the skin incision was intact (Figure 8). However, the degree of plantarflexion was reduced weekly. In the fourth week after surgery, the ankle was in a neutral position and the patient could perform complete dorsiflexion and plantarflexion. After 2 weeks in a walking cast, active dorsiflexion exercises and full weight-bearing were allowed with walker boot.

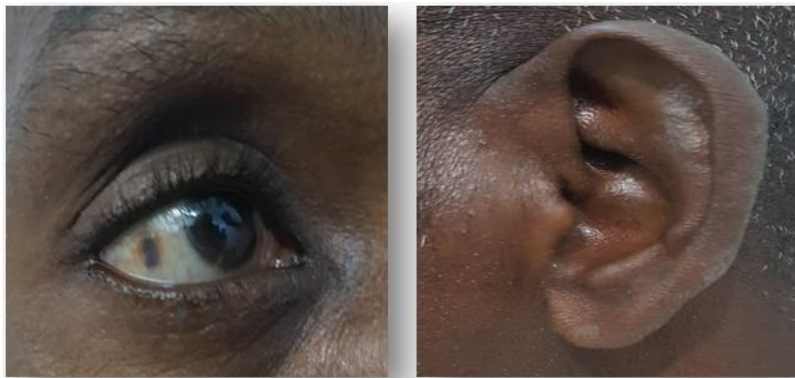

Fig-1: View of the patients showing black pigmentation on eye and ear

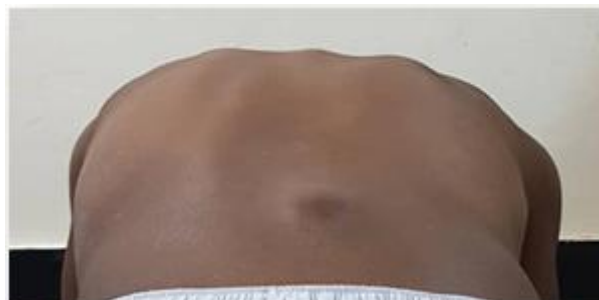

Fig-2: View of the patients showing smooth kyphosis of lumbosacral spine

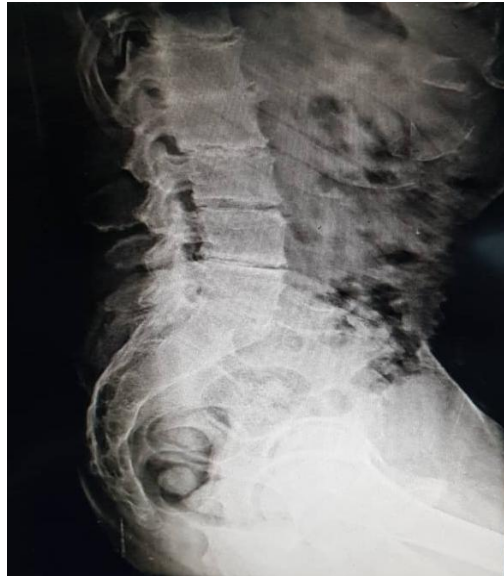

Fig-3: Lateral radiograph of the spine



Fig-4: Urine samples from the patient: fresh sample (left) and upon standing for 24 hours (right)

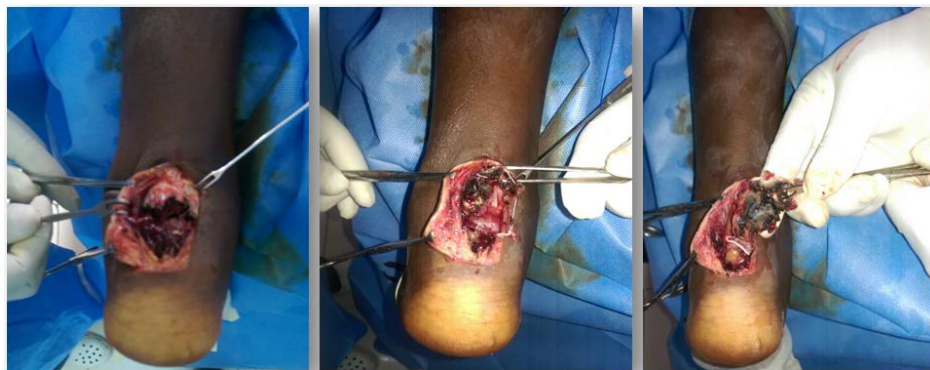

Fig-5: Intraoperative view showing black discoloration of the Achilles tendon

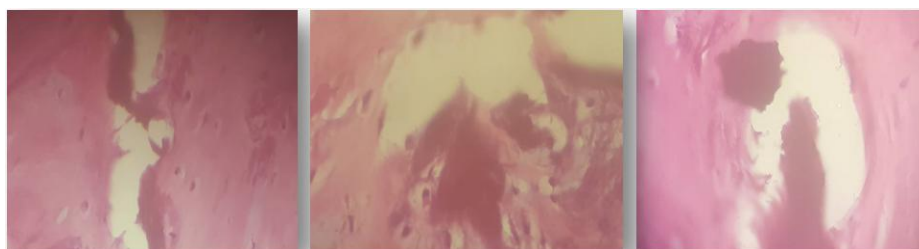

Fig-6: Slide showing fibrous degeneration and inflammatory cells infiltration with brown/ochre pigment deposition

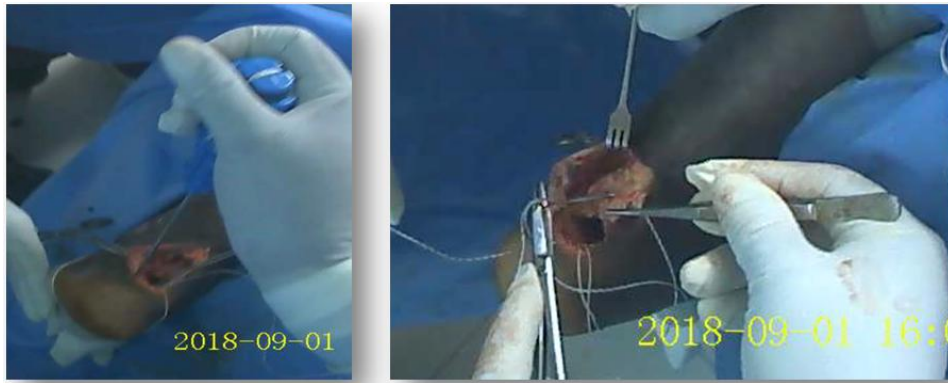


Fig-7: Intraoperative view showing fixation of the two titanium anchors

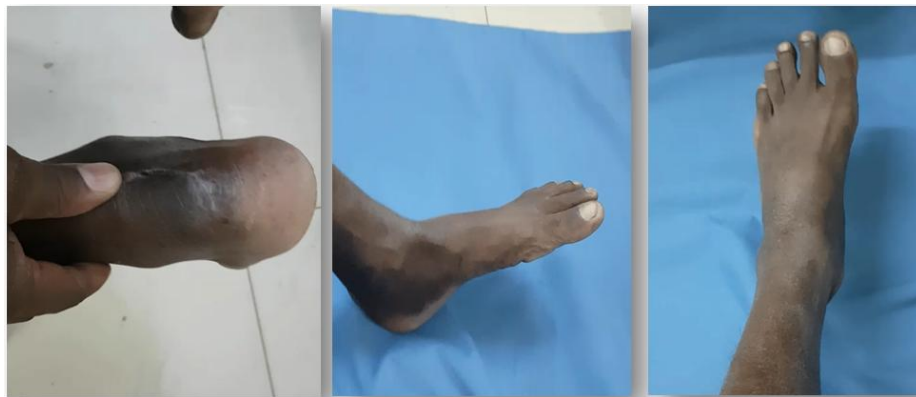

Fig-8: Postoperative photo shows postoperative intact wound and natural position of the ankle

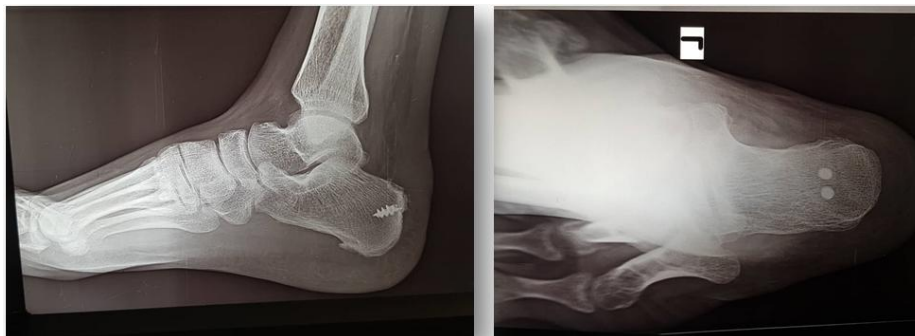

Fig-8: Postoperative radiographic picture of ankle (lateral and axial harris view) showing anchor

DISCUSSION

Alkaptonuria (AKU) is a metabolic disorder caused by a deficiency of homogentisate 1, 2-dioxygenase enzyme (HGD); which results in the deposition of homogentisic acid (HGA) Alkaptonuria usually affects large tendons (Achilles and patellar tendons). The prevalence of spontaneous tendons or ligament ruptures is estimated to be nearly 20%-30% in ochronotic tendons [7]. The musculoskeletal symptoms of AKU typically occur before the usual presentations of AKU, and delayed until the fourth decade of life due to diminished renal clearance of HGA with age [8]. Our case was unique because of the asynchronous rupture of both Achilles tendons, which did not mention by any reviewed reports. There are 11 reported cases in the literature of Achilles tendon rupture in AKU patients. Most cases were reported in India and Middle East [9,10].

As in a majority of the reviewed cases [7,9,11–13], the diagnosis of our patient was made according to the clinical picture, family history, and black urine after 24 hours standing, which raise the suspicion of AKU and confirmed by the presence of ochronotic tissue in the affected Achilles tendon during the operation. Furthermore, the Histopathological study reports a presence of fibrous tissue fragments with foci of degeneration and mixed inflammatory cells infiltration and, presence of brown/ochre pigment deposition as mentioned in previous cases [12–14]. In addition, the common characteristic radiographical finding is the calcification of the intervertebral discs and narrowing of the space, which suggestive of ochronosis as seen in our patient.

However, we did not use any further imaging modalities (Ultrasound or MRI) as in other reported

cases. Our case presented by non-traumatic (Spontaneous) Achilles tendon rupture, whereas; Lifeng Jiang *et al.* [12], report a patient with Achilles tendon ruptured after minor trauma. In addition, our case did not mention any other musculoskeletal related complain excepting a long history of nonspecific back pain as seen in most of the literature reports.

Currently, there is no specific treatment for AKU, and management is usually symptomatic which involves physiotherapy, surgical intervention, pain control, and multivitamins therapy. Despite the studies that indicate the effectiveness of vitamin C in treating patients with AKU; as it reduces the conversion of HGA to BQA polymers via oxidation, the research revealed that it did not affect urinary excretion of HGA. Moreover, it is found to increase HGA production and therefore contributing to the formation of renal oxalate stones, exaggerating the preexisting risk of stones formation in AKU patients [1]. In our case, we deride the distal end of the tendon (> 1 cm) and the approximate and strength the tendon end using two titanium anchors 0.5 mm under image control made to achieve adequate stability for the tendon. However, the recovery plan for our patient involved a gradual reduction of the degree of plantar flexion and then putting the ankle in a natural position, and the patient could perform complete dorsiflexion and plantarflexion. After weeks, in a walking cast, active dorsiflexion exercises and full weight-bearing were allowed with walker boot.

CONCLUSION

Alkaptonuria is a rare metabolic disorder. Alkaptonuria should always include in differential diagnosis of spontaneous Achilles tendon rupture. A meticulous history and physical examination is a cornerstone in patent with a ruptured Achilles tendon. Early detection and repair of the disorder will improve patient outcome and reduce further complication.

Ethical Considerations

Written consent was taken from the patient, and the patient agrees to share his medical information and images.

REFERENCES

- Mistry JB, Bukhari M, Taylor AM, Mistry JB, Bukhari M, Taylor AM. Alkaptonuria Alkaptonuria. *Rare Dis (Austin, Tex)* [Internet]. 2015; 5511(October):e27475. Available from: <https://www.ncbi.nlm.nih.gov/pmc/articles/PMC3978898/?report=abstract%0Aht>
- Nemethova M, Radvanszky J, Kadasi L, Ascher DB, Pires DEV, Blundell TL. Twelve novel HGD gene variants identified in 99 alkaptonuria patients: Focus on “black bone disease” in Italy. *Eur J Hum Genet.* 2016; 24(1):66–72.
- Disorders H, Medicine N, Serv- U, Branch MG, Human N. an Lk a P Tonur Ia Natural History of Alkaptonuria. *English J.* 2002; 347(26):2111–21.
- Ranganath L. Alkaptonuria : Current Perspectives. 2020; 37–47.
- Perry MB, Suwannarat PIM, Furst GP, Gahl WA, Gerber LH. Musculoskeletal Findings and Disability in Alkaptonuria. 2006;
- Abate M, Schiavone C, Salini V, Andia I. Occurrence of tendon pathologies in metabolic disorders. *Rheumatol (United Kingdom).* 2013; 52(4):599–608.
- Manoj Kumar RV RS. Spontaneous tendon ruptures in alkaptonuria. *J Bone Jt surgery* [Internet]. 2003;British Vo. Available from: <https://europepmc.org/article/med/12931812>
- Truzzi M. Polyarticular Ochronotic Arthritis : A Case Report. 2019; 1–13.
- Alajoulin OA, Alsbou MS, Jaafreh SO, Kalbouneh HM. Spontaneous Achilles tendon rupture in alkaptonuria. *Saudi Med J.* 2015; 36(12):1486–9.
- Isaac Jebaraj AR. Ochronosis, Achilles tendon enthesopathy in. *J Postgrad Med* [Internet]. 2006;52(1):47–8. Available from: <https://www.jpgmonline.com/article.asp?issn=0022-3859;year=2006;volume=52;issue=1;spage=47;epage=48;aulast=Jebaraj>
- Baca E, Kural A, Ziroglu N, Kural C. Alkaptonuria: Spontaneous Achilles tendon rupture: Case report. *Eklemler Hast ve Cerrahisi.* 2019; 30(3):325–8.
- Jiang L, Cao L, Fang J, Yu X, Dai X, Miao X. Ochronotic arthritis and ochronotic Achilles tendon rupture in alkaptonuria: A 6 year’s follow-up case report in China. *Medicine (Baltimore).* 2019; 98(34):e16837.
- Tanoğlu O, Arıcan G, Özmeriç A, Alemdaroğlu KB, Çaydere M. Calcaneal Avulsion of an Ochronotic Achilles Tendon: A Case Report. *J Foot Ankle Surg.* 2018; 57(1):179–83.
- Wu K, Bauer E, Myung G, Fang MA. Musculoskeletal manifestations of alkaptonuria: A case report and literature review. *European Journal of Rheumatology.* 2019 Apr;6(2):98.