

Original Research Article

Analysis of Outcome of Surgical Management of Thoracolumbar Fractures with Spinal Cord Injury

Dr. R Prabhakar Singh¹, Dr. Major Kamalanathan²¹Senior Assistant Professor, Department of Orthopaedics, Govt. Kilpauk Medical College and Hospital, Chennai-600010²Associate Professor of Orthopedics, Government Coimbatore Medical College and Hospital, Coimbatore-641018.

*Corresponding author

Dr. R Prabhakar Singh

Email: rpsingh.msortho@gmail.com

Abstract: Thoracolumbar fractures with spinal cord rupture are devastating injuries occurring from motor vehicle accidents, fall from height and injuries related to occupation and recreational activities. It has major functional, medical, psychosocial and financial effects on the injured person, family and society. Recent trends towards open reduction, arthrodesis, and stable internal fixation of spinal fractures are to allow rapid mobilization of patients, reduced reliance on orthotic containment and protection against spinal malalignment or neurological injury when the patient was ambulant and to decrease the complications of prolonged bed rest. The aim was to analyze the functional outcome and neurological recovery following surgical management of thoracolumbar fractures with spinal cord injury. The objective was to analyze the influence of timing of surgery in the chance of neural recovery in traumatic spinal cord rupture. A Prospective descriptive study was carried out from June 2008 to June 2010 in patients with post traumatic thoracolumbar fractures with spinal cord injury in Government Coimbatore Medical College and Hospital, Coimbatore. Total of 25 patients [20 males and 5 females] with a mean age of 34.7, were operated and followed for a period of 6 months to 24 months. The commonest type of fracture was Burst fracture (64%). Five patients (20%) had Fracture dislocation and four (16%) had Compression fracture. Post-operatively, the patients were followed in the first, third, sixth, twelfth and eighteen month with clinical and radiological examination. Frankel's grade improved to Grade E in five patients (20%) and Grade Din twelve patients (44%), six months after surgery. The neurological status remained static in six patients (Grade A - 3 patients and Grade B – 3 patients). No intra-operative complications were observed. Post-operatively, six (24%) had sacral bed sores, four (16%) had respiratory infection and three (12%) had surgical site wound infection. All the six cases of sacral bed sores healed well after flap cover. Respiratory and wound infections settled with appropriate antibiotics. Severity of primary cord damage at the time of accident constitutes major factor in the neurological recovery of the patients. Earlier the intervention and less number of transfers of patients from place to place (less secondary neurological damage) gives good prognosis.

Keywords: Key Messages, Thoracolumbar fractures, Surgical Management, Spinal Cord

INTRODUCTION

Thoracolumbar fractures with spinal cord rupture are devastating injuries occurring from motor vehicle accidents, fall from height and injuries related to occupation and recreational activities. It has major functional, medical, psychosocial and financial effects on the injured person, family and society.

Management of thoracolumbar fractures with or without spinal cord injury is one of the controversial areas in modern spine surgery and continues to evolve. An unstable fracture of vertebrae produces spinal instability and narrowing of the spinal canal producing neurological deficit. The surgical spinal stabilization is indicated in these conditions to maintain the anatomical position, to promote the early bony fusion, early mobilization and neurological recovery.

Recent trends towards open reduction, arthrodesis, and stable internal fixation of spinal fractures are to allow rapid mobilization of patients, reduced reliance on orthotic containment and protection against spinal malalignment or neurological injury when the patient is ambulant and to decrease the complications of prolonged bed rest.

In the past, non-operative care in the form of either a body cast or a brace in stable thoracolumbar fractures without neurological deficit, avoids a major surgical intervention with its attendant morbidity. The optimal treatment of patients with mild-to-moderate deformity, an incomplete neurological deficit and residual spinal canal compromise after conservative or surgical management remains a grey area.

During the past 25 years, the field of spine surgery has seen a dramatic increase in the operative management of thoracolumbar fractures with anterior or posterior spinal instrumentation. The development of biomechanically sound instrumentation to provide stable internal fixation, has rapidly changed the concepts of patient management.

In this prospective study aim was to analyze the functional outcome and neurological recovery following surgical management of thoracolumbar fractures with spinal cord injury and to analyze the influence of timing of surgery in the chance of neural recovery in traumatic spinal cord rupture.

SUBJECTS AND METHODS

This prospective study was carried out from June 2008 to June 2010 in patients with post traumatic thoracolumbar fractures with spinal cord injury in the Department of Orthopaedics, Coimbatore Medical College Hospital, Coimbatore, and Tamil Nadu.

A total of 25 patients [20 males and 5 females] with a mean age of 34.7, were operated and followed for a period of 6 months to 24 months.

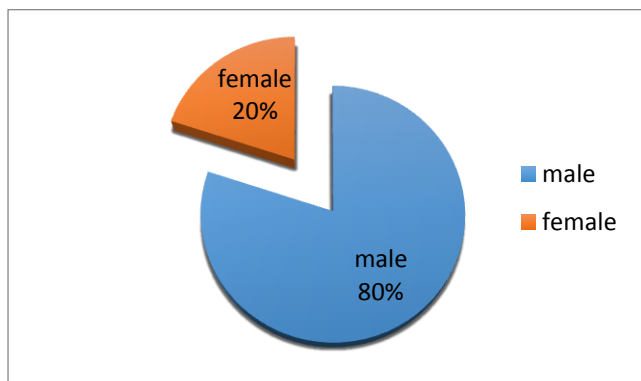


Fig-1: Sex Distribution

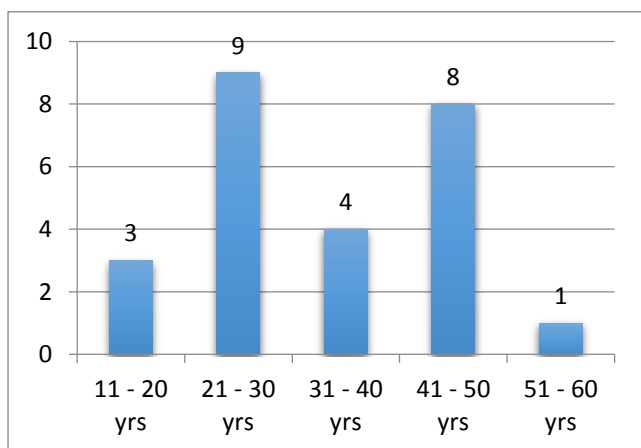


Fig-2: Age Distribution

The commonest mode of injury was fall from height. The other mechanisms being road traffic accidents and fall of heavy object on the back.

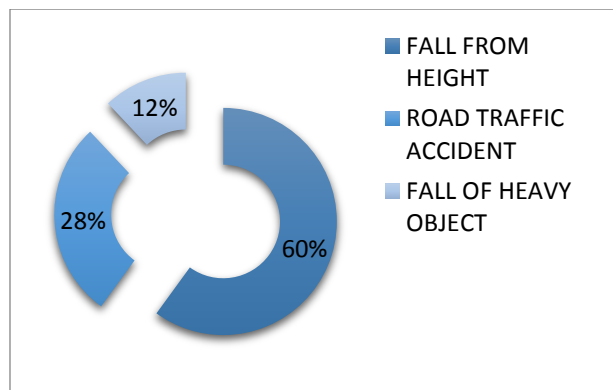


Fig-3: Mode of Injury

Of the 25 patients admitted, fourteen had complete paraplegia and eleven had incomplete spinal cord injury.

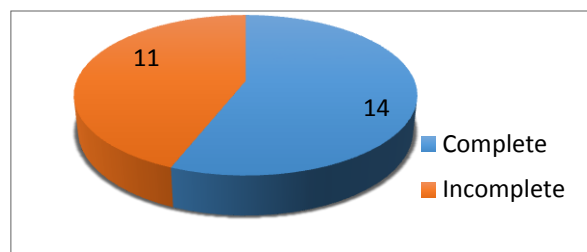


Fig-4: Neurological Pattern on Admission

On admission, fourteen patients were Grade A, seven - Grade B, two patients each in Grade C and D. Regarding the level of vertebral fracture, D11,D12 and L1 were the commonest sites, comprising 76% of the total number of cases.

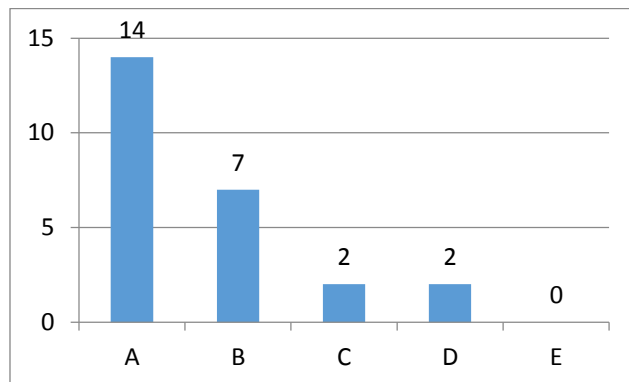


Fig-5: Frankel's Grade on Admission

Table 1: Vertebral Fracture Level

Level	Number of patients
D7	1
D8	0
D9	1
D10	2
D11	4
D12	5
L1	10
L2	2

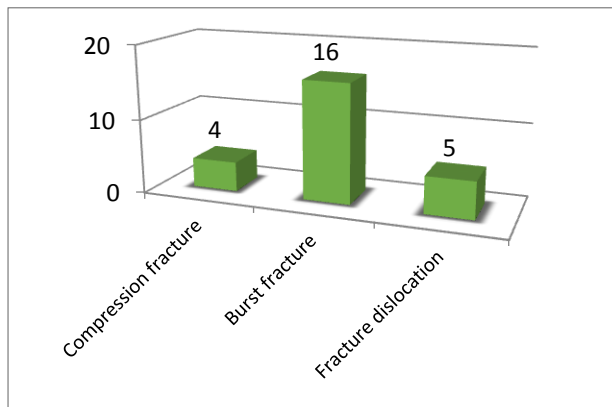


Fig-6: Classification of Vertebral Fracture

The commonest type of fracture was Burst fracture (64%). Five patients (20%) had Fracture dislocation and four (16%) had Compression fracture. Calcaneal and Pubic rami fractures were the commonest associated injuries in our study.

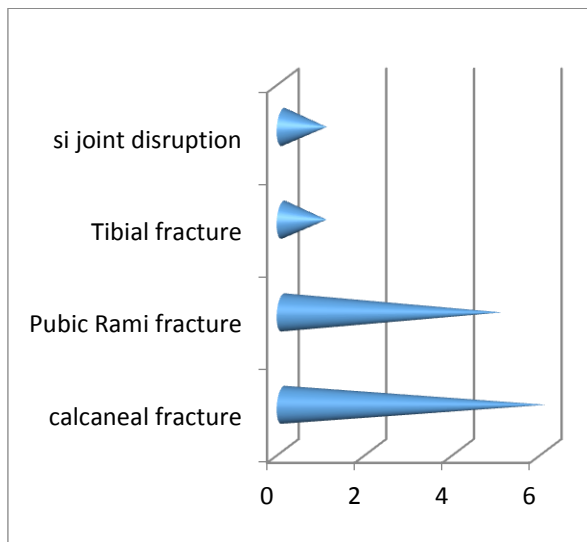


Fig-7: Associated Injuries

Timing of surgery

Of the twenty five patients, seven were operated within the first week of injury, eleven patients between first and second week and seven between second and third week.

METHODS

Initial assessment of a patient included the mode of injury and extrication, a thorough physical examination, and an accurate assessment of the patient's neurological status and spinal stability. Emergency management included resuscitation of patient, and treatment of life-threatening injuries, followed by surgical stabilization of the injured osteoligamentous column. All patients were administered with methylprednisolone beginning with a bolus of 30 mg/kg over one hour and continued at an infusion at a rate of

5.4 mg/kg/hour for next 47 hours, according to NASCIS III International protocol.

Inclusion criteria

- a) Traumatic fractures of the thoracolumbar region with spinal cord injury
- b) Presentation less than three weeks after the time of the injury
- c) Age between eighteen and sixty-years.

Exclusion criteria

The following patients were excluded from our study

- (a) Patients with head injury
- (b) Open fractures,
- (c) Fractures due to osteoporosis (pathological fractures),
- (d) Patients with cancer, systemic infection, bleeding disorder, extensive skin disease.

Full neurological examination (sensation, motor, anal tone) was done and repeated at periodical interval to look for and pick up neurological improvement or deterioration. Resuscitation with protection of the spinal column was instituted simultaneously. Pattern and level of neurological injury were determined and Cord injury graded by Frankel's Classification.

Plain radiographs, CT scans, and MRI if needed were carried out to identify all injuries (fractures, dislocations, facet subluxation, pedicle rotation, malalignment, soft tissue swelling) and to assess the severity and nature of the injury. The level and type of fractures were classified according to Dennis and McAfee classification

The factors that were considered in choosing the method of instrumentation and approach of surgical treatment were:

- 1. Stability of the Spinal column
- 2. Level of cord injury
- 3. Patient factors (health, age, weight, premorbid, associated injuries)

Stabilization was done with one of the following instrumentation,

- 1. Hartshill Rectangle with sub laminar wires,
- 2. Transpedicular Screws and rods
- 3. Vertebral screws and rods.

Surgical procedures

All patients received per operative broad-spectrum antibiotics half an hour before anaesthesia. The patient under the effect of general anaesthesia was positioned on the fracture table. Antero-posterior and lateral images obtained.

1. Anterior decompression by corpectomy, strut grafting, spinal stabilization with vertebral screws and connecting rods.

Patient positioned in the lateral decubitus position. The surgical approach was planned according to the level of the damaged segments by doing thoracotomy. Parietal pleura incised and reflected it off the spine, one vertebra above and one below the involved segments for adequate exposure. Spinal cord decompressed by corpectomy with disc and end plates material above and below the damaged segments removed and bed prepared for bone graft. The tricortical strut graft from iliac crest or cage filled with bone graft are placed over corpectomy site of the intervertebral space. Two vertebral screws placed laterally over vertebral body one above and one below the involved segments, which is parallel to the vertebral plates. The screws are connected and compressed to the inter connecting rod. Screws placement is confirmed by radio graphs. Fat graft placed over the dura and nerve roots and wound closed over a suction drain along with inter costal drainage.

2. Posterior decompression by laminectomy, postural reduction, and translation of retro pulsed fragments anteriorly with spinal fusion and spinal stabilization with sub laminar wires and connected rods [Hartshill rectangle].

Patient placed in prone position and images obtained to identify the fractured vertebrae. A posterior midline incision was made and Paraspinal muscles were erased and freed to the outer margin of the transverse process, exposing two levels above and two levels below the fractured vertebra. Cord decompressed by laminectomy and the retro pulsed fragment translated anteriorly. Postural reduction obtained and spinal fusion done after removing articular facet joint which is filled with bone graft. Hartshill rectangle of appropriate length selected and contoured and placed between the spinous processes after excising the interspinous ligaments two vertebrae above and two vertebrae below the fractured vertebrae. It is secured to the spine by means of doubled 16 or 18 gauge sub laminar wires and were tightened. Fat graft was placed over the dura and nerve roots and wound closed over a suction drain, after obtaining proper haemostasis.

3. Posterior decompression by laminectomy, postural reduction, and retro pulsed fragments translated anteriorly. Spinal stabilization with pedicle screws and connecting rods.

Patient placed in prone position and images obtained to determine the direction of pedicle and disc spaces. Posterior midline incision was made and Para spinal muscles were erased and freed to the outer margins of the transverse process, exposing at least three vertebral levels. Cord decompressed by laminectomy and the retro pulsed fragment translated anteriorly. Postural reduction obtained and by using x ray control, pedicles were located and marked. With

help of pedicle probe, the intramedullary canal entered. Under x ray control, screws length and placements were performed. Two pedicle screws distally and two pedicle screws proximally placed in relation to the fractured vertebrae and connected to two parallel rods with one inter connecting rod. Fat graft was placed over the dura and nerve roots and wound closed over a suction drain after obtaining complete haemostasis.

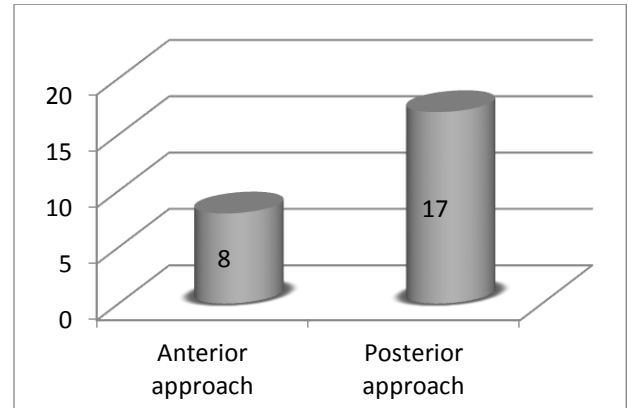


Fig-8: Surgical Approach

Follow up

Post-operative intravenous antibiotics were given for 72 hours, sutures removed on 15th day and patients discharged after thorough education regarding back care, bladder care and rehabilitation protocol. Patients were followed in the first, third and sixth month with complete neurological evaluation (Frankel’s grading) and radiographs obtained. The longest follow up was 24 months and shortest 6 months with a mean of 13 months.

RESULTS

Post-operatively, the patients were followed in the first, third, sixth, twelfth and eighteen month with clinical and radiological examination. Longest follow up was 24 months, shortest 6 months with a mean of 13 months.

Frankel’s grade improved to Grade E(A-E:2, B-E:1, D-E:1, C-E:1) in five patients (20%) and Grade D(A-D:4, B-D:6, C-D:1, D-D:1) in twelve patients (44%), six months after surgery. The neurological status remained static in six patients (Grade A - 3 patients and Grade B - 3 patients)

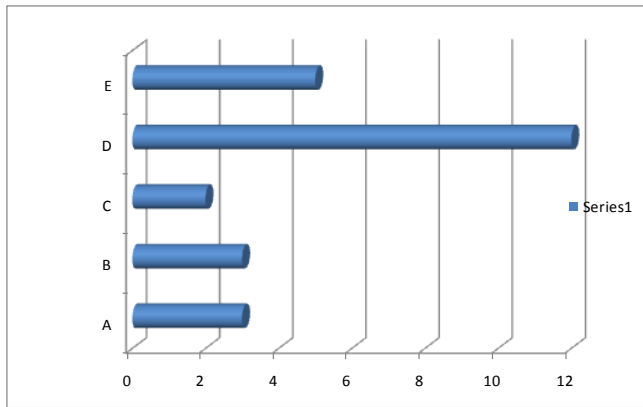


Fig-9: Post-operative Frankel's Grade (6 months)

TIMING OF SURGERY

Of the twenty five patients, seven were operated within the first week of injury, eleven patients between first and second week and seven between second and third week.

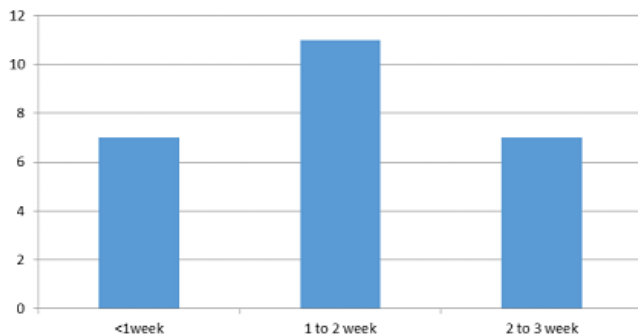


Fig-10: Timing of surgery

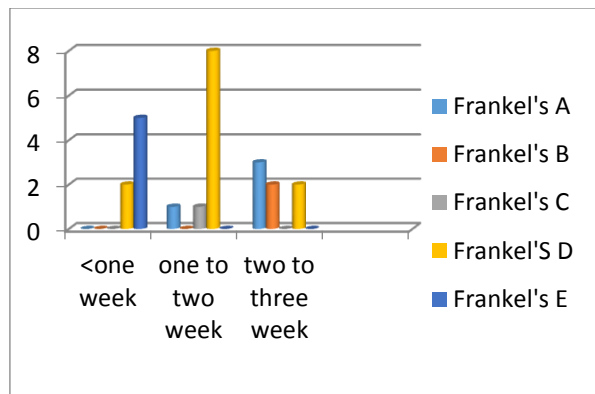


Fig-11: Influence of timing of surgery in neurological recovery

In the seven patients who were operated within one week, all of them had good neurological recovery with Frankel's grade improved to grade E in five patients and grade D in two patients.

Four patients stabilized within 72 hours of injury had good neurological recovery, with Frankel's grade improved to grade E in three patients and grade D in one patient.

Level of vertebral fractures

In our study, regarding the level of vertebral fracture, D11 (4 Patients-16%) D12 (5 patients -20%) and L1 (10 patients – 40%) were the commonest site.

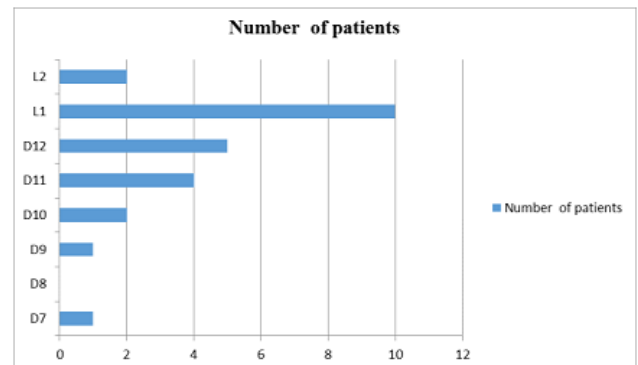


Fig-12: Level of vertebral fractures

Role of level of vertebral fracture in neurological recovery

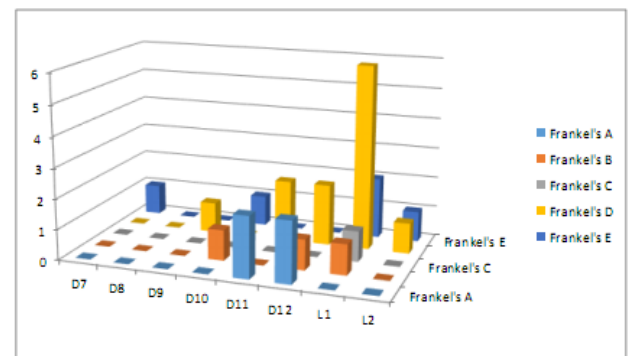


Fig-13: Recovery of Frankel's grade compared with fracture level

Of the ten (40%) patients who sustained L1 fracture, eight (32%) of them neurologically recovered to Frankel's grade E and D and were walking independently. Similarly, the two patients who sustained L2 fracture were improved to Frankel's grade E and D

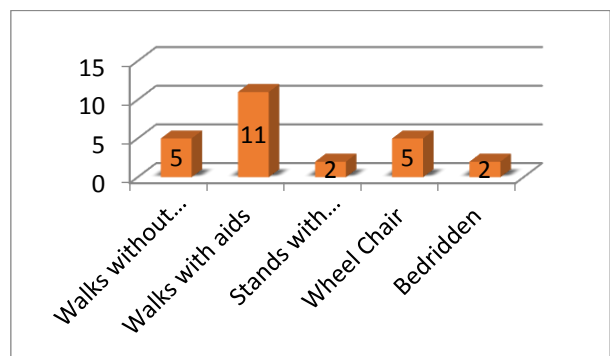


Fig-14: Functional outcome

Bladder and bowel sensation improved in sixteen patients (64%) after six months, and the remaining patients were trained for self-intermittent

catheterization, and condom drainage. On six months follow up, five (20%) were able to walk independently and eleven (44%) with aids. Five (20%) were able to ambulate using wheel chair and two remained bedridden.

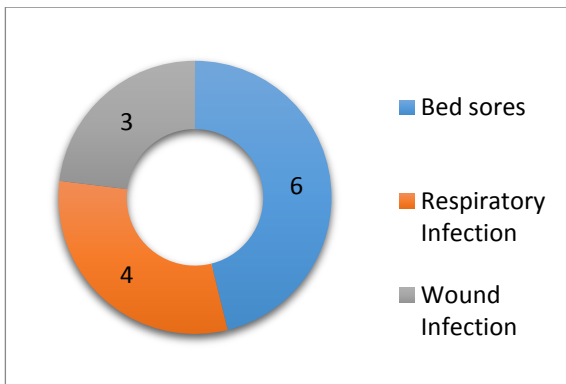


Fig-15: Post-operative Complication

No intra-operative complications were observed. Post-operatively, six (24%) had sacral bed sores, four (16%) had respiratory infection and three (12%) had surgical site wound infection. All the six cases of sacral bed sores healed well after flap cover. Respiratory and wound infections settled with appropriate antibiotics.

The complications like implant loosening displaced screw, broken implants, presence of bony fragments in the spinal canal, non-correction of the angulations, and collapse at the fracture union were not occurred in our study. These patients whose neurological status remained static where followed with post-operative MRI, which revealed severe spinal cord atrophy.

DISCUSSION

The unique transitional anatomy of the thoracolumbar spine renders it vulnerable to the high-energy deceleration trauma associated with fall from height and motor-vehicle collisions [1]. The primary objectives of initial evaluation and diagnosis include characterization of the injury and identification of any neurological deficit. The goal of the treatment of thoracolumbar fractures, regardless of the selected method, are the restoration of the stability of the vertebral column and the decompression of the spinal canal, leading to earlier mobilization of the patient and enhances the chances of neurological recovery.

In 1975 Krauss *et al* [2] noted that the most commonly injured region of the spine is dorsolumbar junction. About 16% of Dorsolumbar injuries occur between T1 and T10, 52% between T11 & L1 and 32% between L1& L5. In our study, regarding the level of vertebral fracture, D11 (4 Patients-16%), D12 (5 patients -20%) and L1 (10 patients – 40%) were the commonest site (Table.1). The commonest type of fracture was Burst fracture (64%) (Fig-6).

In 1991 Carpenter *et al* [3] described that the injuries are sustained commonly by middle aged and younger individuals .They are almost always due to high energy trauma such as fall from height and motor vehicle accidents . The commonest mode of injury in our study was fall from height (60%). The other mechanisms being road traffic accident and fall of heavy object (fig.3).

Males have four fold increased risk than females in most of the studies. We too observed a male preponderance (80%) with the mean age of 34.7yrs (fig.1).

In 1983 Post and Green [4] reported that 5 % to 20% of patients with spinal injuries, contiguous & non-contiguous spinal injuries are also present. Calenoff *et al* [5] emphasized that failure to detect non-contiguous concomitant injuries can lead to delayed instability and neurological deterioration. In our study no associated vertebral fractures were encountered.

In the study by Colter *et al* [6] in 1986 and Court-brown *et al* [7] in 1988 described that depending on the type of dorsolumbar spine injury, associated spinal and non-spinal injuries occur in up to 50% of patients .Intra thoracic injuries occur in about 20% of patients while intra-abdominal injuries occur in 10% and associated skeletal injuries occur in up to 20% of patient. The most common of these are calcaneal fractures. Calcaneal (24%) and Pubic rami (20%) fractures were the commonest associated injuries in our study (fig.7).

The treatment of thoracolumbar fractures with cord injury remains a controversial issue. Early reports of decompression and stabilization inpatients with neurological deficit and thoracolumbar fracture demonstrated improvement that was equal to that of non-operative results in the literature' With the advent of newer instrumentation techniques and aggressive direct anterior decompression, the degree of neurological recovery appears more favourable than earlier reports.

McLain [8] studied patients with severe spinal fractures treated with segmental fixation and described its advantages viz. immediate mobilization of patients with less dependence on bracing, the distribution of corrective forces over multiple levels and the reduction of the likelihood of implant failure.

Indication for surgical intervention is the presence of progressive neurological deterioration in the presence of spinal cord compression. When direct spinal canal decompression is promptly performed in such an injury, neurological recovery has been observed [9, 10, 11]. Of the twenty five patients in our series, ten (40%) were operated within the first week of injury,

nine patients (36%) in the second week and six (24%) in the third week (fig.10). In the seven patients who were operated within one week, all of them had good neurological recovery with Frankel's grade improved to grade E in five patients and grade D in two patients. Four patients stabilized within 72 hours of injury had good neurological recovery, with Frankel's grade improved to grade E in three patients and grade D in one patient (Fig: 11.).

Excellent spinal canal decompression can be achieved by either a posterolateral, transpedicular, or an anterior approach [12, 13]. In our study, spine was exposed through Posterior approach in the majority of cases (68%). Eight patients (32%) were approached anteriorly (fig.8).

In the presence of a non-progressive neurological deficit the evidence supporting surgical decompression is conflicting. Most of the surgeons feel that canal compromise in the absence of a neurological deficit is not an indication for surgery, since canal remodelling can occur with time, in patients whose fractures are surgically reduced and stabilized [10, 11, 14-18].

Dai *et al* [19] found the degree of spinal canal stenosis was similar in those treated non-operatively as compared to operatively. In a comprehensive review of the literature, Boerger *et al* [16] failed to find support for canal clearance. Mohanty *et al* [20] found in a prospective study that there was no correlation between neurological recovery and the degree of canal compromise. These studies go on to recommend nonoperative treatment for patients with none or mild neurological impairment. Boerger *et al* [16] go as far as to state that in the absence of instability any canal clearance by surgical intervention would be causing a patient a disservice. There is no role of isolated laminectomy for decompression of thoracolumbar fractures, since laminectomy disrupts the posterior elements contributing to further instability.

Regarding the level of fusion many authors agree the long segment fusion (instrument two or more levels above and below a fractured vertebra) is stronger and stiffer (higher ultimate failure strength) than Short Segment fixation (instrumentation one level above and below a fractured vertebra); however it sacrifices spinal motion. In our study, of the ten (40%) patients who sustained L1 fracture, eight (32%) of them neurologically recovered to Frankel's grade E and D and were walking independently. (Fig: 13.) Similarly, the two patients who sustained L2 fracture were improved to Frankel's grade E and D. It revealed that the functional outcome of neurological recovery in patients who sustained lumbar fractures were good which were correlated with other studies [21].

The location of the fracture can influence the surgeon's choice of fusion. A long fusion in the upper and middle thoracic spine does not reduce patient's spinal mobility and function very much. However, the thoracolumbar and lumbar spines are functionally very important. Preservation of mobility in these segments of the spinal column is fundamental particularly in manual workers whose jobs require increase demands on the spine.

With regard to stabilization after decompression, when a single vertebral body is highly comminuted, anterior reconstruction of the spinal column and anterior instrumentation is superior to posterior fixation [21-25]. The pedicle screw rod systems, by virtue of direct fixation through middle and anterior columns, are able to reduce fractures of these columns by ligamentotaxis [26-30]. Transpedicular screw rod construct is currently the standard in segmental fixation of thoracolumbar spine [19, 31, 32]. Posterior surgery with pedicle screw constructs over a short segment stabilizes the fracture and allows early mobilization, much as non-operative regimes do. Recent prospective randomized studies comparing these two treatment options suggest there is no clinical advantage of surgery over non-operative care [22, 23]. Surgery corrects deformity but modest recurrence is common, even with attempts to perform transpedicular bone grafting, as the anterior column remains deficient [24]. Anterior decompression will be more effective for decompressing the spinal cord in burst fractures. Anterior decompression has been shown to increase axoplasmic flow, decrease ischemia, and lead to improvement of neurological function. The disadvantage of posterior approaches to achieve anterior decompression include the need to resect major portions of the neural arch (often uninjured) to obtain access to the middle column. Finally, it is difficult to reconstruct the anterior and middle columns after a posterior approach has been used to decompress a burst fracture, and there is significant incidence of construct failure [25].

Our experience with short segment pedicle screw-based fixation has been excellent. We utilized Short Segment fixation for young healthy people with isolated spinal injuries. While out of bed the patient must wear a brace, for 6-8 weeks until the fusion consolidates. Stabilization was done with Hartshill rectangle with sub laminar wires in thirteen patients (52%), Pedicle screw instrumentations in four patients (16%) and anterior stabilization with vertebral screws and rods with bone graft (cage / strut graft) (32%) in our series. We used a full-thickness autologous iliac strut graft to reconstruct the spinal column with excellent results. We preferred a modular and stackable cage spacer filled with auto graft from the vertebrectomy and excised rib, with the same type of dual rod/screw implants. Use of the cage avoided the large iliac crest donor site pain.

Regardless of the fixation system used, we were careful not to over distract the fracture site. The normal sagittal and coronal spinal alignments were restored, with or without fully correcting the vertebral height. Overzealous distraction using a principle of ligamentotaxis creates a gap (empty space) at the fracture site which further decreases the load sharing of the axial forces between the implants and the fractured body, and hence avoided.

Post-surgical kyphosis is a clinical and radiological condition, which results following a failure after operative stabilization. It can develop due to failure to recognize or under-estimation of translational injuries, poor bone quality, inadequate spinal bracing or follow up, or errors in surgical technique or spinal healing. It can be mild, moderate or very severe. Patients can present with mechanical or neurological symptoms. Back pain is the most common presenting feature an indication for intervention. In our study, we were fortunate for not encountering postsurgical kyphosis.

Six patients who did not improved clinically, whose neurological status remained same were followed up with post-operative MRI, which revealed severe cord degenerative changes. Post-operative Frankel's grade improved to Grade E(A-E:2, B-E:1, D-E:1, C-E:1) in five patients (20%) and Grade D(A-D:4, B-D:6, C-D:1, D-D:1) in twelve patients (44%) , six months after surgery Which were consistent with most of the major studies.

In the seven patients who were operated within one week, all of them had good neurological recovery with Frankel's grade improved to grade E in five patients and grade D in two patients.

Four patients stabilized within 72 hours of injury had good neurological recovery, with Frankel's grade improved to grade E in three patients and grade D in one patient.

CONCLUSION

1. Severity of primary cord damage at the time of accident constitutes major factor in the neurological recovery of the patients.
2. Earlier the intervention and less number of transfers of patients from place to place (less secondary neurological damage) gives good prognosis.
3. The most commonly injured region of the spine is dorsolumbar junction. LI constitutes majority (40%) of the fracture.
4. In most patients we stabilized spine through Posterior approach and we achieved good neurological recovery and there by fewer complications and better functional outcome.

5. Early timing of decompression and stabilization played a major role in the neurological recovery.
6. Majority of the patients (64%) is walking independently and resumed to their normal activities with good neurological recovery.

Hence, early surgical decompression and adequate spinal stabilization gives good results in spinal cord injury

REFERENCES

1. Wood K, Buttermann G, Mehbod A, Garvey T, Jhanjee R, Sechriest V; Operative Compared with Nonoperative Treatment of a Thoracolumbar Burst Fracture without Neurological Deficit. *The Journal of Bone and Joint Surgery*, 2003; 85:773-781.
2. Kraus JF, Franti CE, Riggins RS, Richards D, Borhani NO; Incidence of traumatic spinal cord lesions. *J Chronic Dis.*, 1975; 28:471-492.
3. Carpenter MB; Core text of neuroanatomy, 4th edn. Wilkins & Wilkins, Baltimore, MD, 1991.
4. Post MJD, Green BA; the use of computed tomography in spinal trauma. *Radiol Clin North Am.*, 1983; 21:327-375.
5. Calenoff L, Chessare JW, Rogers LF, Toerge J, Rosen JS; multiple level spinal injuries: importance of early recognition. *AJR Am J Roentgenol.*, 1978; 130:665-669.
6. Colter JM, Vernace Jr, Michalski JA; The use of Harrington rods in thoracolumbar fractures. *Orthop Clin North Am.*, 1986; 17:87-103.
7. Gertzbein SD, Court-Brown CM; Flexion-distraction injuries of the lumbar spine: mechanism of injury and classification. *Clin Orthop.*, 1988; 227:52-60.
8. McLain RF, Benson DR, Burkus K; Segmental Instrumentation for Thoracic and Thoracolumbar Fractures: Prospective Analysis of Construct Survival and Five Year Follow-up. *Spine J.*, 2001; 1:310.
9. Bohlman HH, Kirkpatrick JS, Delamarter RB, Leventhal M; Anterior Decompression for Late Pain and Paralysis after Fractures of the Thoracolumbar Spine. *Clin Orthop.*, 1994; 300:24-9.
10. Maiman DJ, Larson SJ, Benzel EC; Neurological Improvement Associated With Late Decompression of the Thoracolumbar Spinal Cord. *Neurosurgery*, 1984; 14:302-7.
11. McAfee PC, Bohlman HH, Yuan HA; Anterior Decompression of Traumatic Thoracolumbar Fractures with Incomplete Neurological Deficit Using a Retroperitoneal Approach. *J Bone Joint Surg Am.*, 1985; 67:89-104.
12. Been HD, Bouma GJ; Comparison of Two Types of Surgery for Thoraco-Lumbar Burst Fractures: Combined Anterior and Posterior Stabilisation Vs. Posterior Instrumentation Only. *Acta Neurochir Wien*, 1999; 141:349-57.

13. Yazici M, Atilla B, Tepe S, Calisir A; Spinal Canal Remodelling in Burst Fractures of the Thoracolumbar Spine: a Computerized Tomographic Comparison Between Operative and Nonoperative Treatment. *J Spinal Disord.*, 1996; 9:409-13.
14. Gertzbein SD; Scoliosis Research Society. Multicentre Spine Fracture Study. *Spine*, 1992; 17:528-40.
15. Hashimoto T, Kaneda K, Abumi K; Relationship between Traumatic Spinal Canal Stenosis and Neurologic Deficits in Thoracolumbar Burst Fractures. *Spine*, 1988; 13:1268-72.
16. Boerger TO, Limb D, Dickson RA; Does 'Canal Clearance' Affect Neurological Outcome after Thoracolumbar Burst Fractures? *J Bone Joint Surg Br.*, 2000; 82:629-35.
17. Kim NH, Lee HM, Chun IM; Neurologic Injury and Recovery in Patients with Burst Fracture of the Thoracolumbar Spine. *Spine*, 1999; 24:290-3.
18. Dickson JH, Harrington PR, Erwin WD; Results of Reduction and Stabilization of the Severely Fractured Thoracic and Lumbar Spine. *J Bone Joint Surg Am.*, 1978; 60:799-805.
19. Dai LY; Remodelling of the Spinal Canal after Thoracolumbar Burst Fractures. *Clin Orthop.*, 2001; 382:119-23.
20. Mohanty SP, Venkatram N; Does Neurological Recovery in Thoracolumbar and Lumbar Burst Fractures Depend on the Extent of Canal Compromise? *Spinal Cord*, 2002; 40:295-9.
21. McNamara MJ, Stephens GC, Spengler DM; Transpedicular Short-Segment Fusions for Treatment of Lumbar Burst Fractures. *J Spinal Disord.*, 1992; 5:183-7.
22. Kaneda K, Abumi K, Fujiya M; Burst Fractures with Neurologic Deficits of the Thoracolumbar-Lumbar Spine. Results of Anterior Decompression and Stabilization with Anterior Instrumentation. *Spine*, 1984; 9:788-95.
23. Oda I, Cunningham BW, Lee GA, Abumi K, Kaneda K, McAfee PC; Biomechanical Properties of Anterior Thoracolumbar Multisegmental Fixation: an Analysis of Construct Stiffness and Screw-Rod Strain. *Spine*, 2000; 25:2303-11.
24. McLain RF, Sparling E, Benson DR; Early Failure of Short-Segment Pedicle Instrumentation for Thoracolumbar Fractures. A Preliminary Report. *J Bone Joint Surg Am.*, 1993; 75:162-7.
25. Holt BT, McCormack T, Gaines RW; Short Segment Fusion-Anterior or Posterior Approach? The Load-Sharing Classification of Spine Fractures. *Spine*, 1993; 7:227-85.
26. Tropicano P, Huang RC, Louis CA, Poitout DG, Louis RP; Functional and Radiographic Outcome of Thoracolumbar and Lumbar Burst Fractures Managed by Closed Orthopaedic Reduction and Casting. *Spine*, 2003; 28:2459-65.
27. Shen WJ, Shen YS; Nonsurgical Treatment of Three-Column Thoracolumbar Junction Burst Fractures Without Neurologic Deficit. *Spine*, 1999; 24:412-5.
28. Chow GH, Nelson BJ, Gebhard JS, Brugman JL, Brown CW, Donaldson DH; Functional Outcome of Thoracolumbar Burst Fractures Managed With Hyperextension Casting or Bracing and Early Mobilization. *Spine*, 1996; 21:2170-5.
29. Knight RQ, Stornelli DP, Chan DP, Devanny JR, Jackson KV; Comparison of Operative versus Non-operative Treatment of Lumbar Burst Fractures. *Clin Orthop.*, 1993; 293:112-21.
30. Chipman JG, Deuser WE, Beilman GJ; Early Surgery for Thoracolumbar Spine Injuries Decreases Complications. *J Trauma*, 2004; 56:52-7.
31. Sarmiento A, McKellop HA, Llinas A, Park SH, Lu B, Stetson W; Effect of Loading and Fracture Motions on Diaphyseal Tibial Fractures. *J Orthop Res.*, 1996; 14:80-4.
32. McNamara MJ, Stephens GC, Spengler DM; Transpedicular Short-Segment Fusions for Treatment of Lumbar Burst Fractures. *J Spinal Disord.*, 1992; 5:183-7.