

Case Report

Gastrointestinal stromal tumor of jejunum presenting as perforation peritonitis:**A case report****Amit Jain^{1*}, Mayank Jain², Irfan Hussain Khan³, Manish Kheriwal⁴, Richa Jain⁵**¹Assistant Professor, ³Senior Resident, ^{2,4}Resident, ⁵Professor and Unit Head

Dept of General Surgery Sawai Man Singh Medical College Jaipur, Rajasthan, India Pin-302004

***Corresponding author**

Dr. Amit Jain

Email: dramitjain007@gmail.com

Abstract: GIST is one of the most studied and conversely one of the least found tumor of the GIT . Further if we talk about GIST presenting as a cause of acute emergency, the exclusivity of the case becomes high. We present a case of 65 year old male patient, who presented to us initially with symptoms of intestinal obstruction which lead to acute abdomen within a span of 6 hours after admission. Exploratory laparotomy of the patient revealed a 6 x 5 x 3 cm perforated cystic lesion arising from the mesenteric border of the jejunum nearly 60 cm from the ligament of trietz. The lesion was communicating with the lumen of the jejunum. This was followed by resection anastomosis and the HPE of the specimen revealed it to be a GIST.

Keywords: GIST – Gastro intestinal tumor, GIT – Gastro Intestinal Tract, CT – Computed tomography, HPE – Histo pathology Examination

INTRODUCTION

GIST are rare sarcomatous tumors and account for only 1% to 3% of gastrointestinal tract malignancies but still considering the tumor of mesenchymal origin , it is one of the most common one which can arise from any part of the GIT. GIST arises from the interstitial cells of cajal and are associated with expression of CD-117.

Due to better investigations available and registration of the cases, incidence of GIST has increased in past two decades with an incidence rates ranging from 6.5 – 20 cases / million[1,2,3]. Nearly one third of the patients are incidentally diagnosed during surgical / endoscopic / radiological studies[1, 4] . GIST usually cause sudden onset and intermittent abdominal pain but also can present as intestinal obstruction, GI hemorrhage , perforation peritonitis.

Complete surgical removal is the treatment of choice with or without chemotherapy.

CASE REPORT

A 65 year old male patient presented to us with features of obstruction since 2 days .Patient had abdominal distention with fever and vomiting since last two days. X ray FPA showed multiple air fluid levels with step ladder pattern suggesting of small intestinal obstruction. Within two hours of admission patient's condition worsened and increased signs of peritonitis were seen. The patient was taken up for an exploratory laparotomy, which revealed a peritoneal cavity filled

with nearly 1.5 liters of bile mixed contaminated fluid. A perforated cystic lesion measuring nearly 6 x 5 x 2 cm was seen arising from the mesenteric border of the jejunum nearly 60 cm from ligament of trietz. The cyst was freely communicating with the gut lumen. Resection of the affected gut segment was done followed by hand sewn end to end anastomosis. Post operative period was uneventful and patient was discharged after ten days. HPE of the mass confirmed the diagnosis of GIST .Patient was started on imanatinib and is doing well since six months.

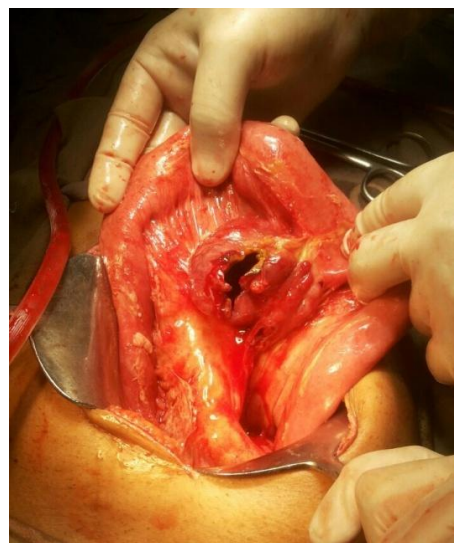
**Fig-1: Perforated GIST**

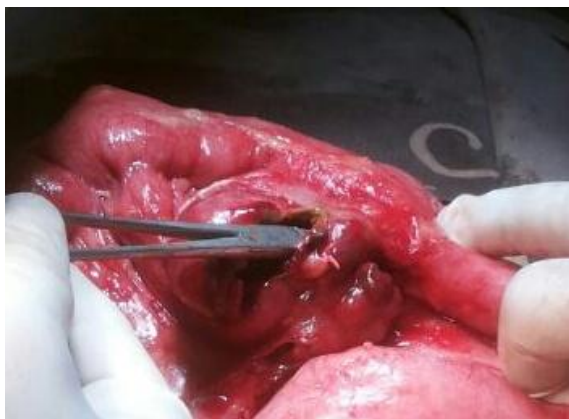

Fig- 2: GIST communicating with gut lumen

DISCUSSION

GIST are solid tumors of GIT and can arise anywhere from esophagus to anus. Macroscopic description of GIST is usually given as soft, solid, well lobulated and circumscribed tumors but may rarely be cystic and sometimes a communication with gut lumen too may follow.

Though the size of tumor is considered as criteria for malignancy in GIST, many authors have suggested that this is not true in case of cystic tumors. However if the solid component of the tumor is big enough to be measured it can be considered to decide the malignant status. Cystic tumors can be found in variety of conditions such as primary cystic GIST, cystic degeneration in large malignant tumors due to inadequate blood supply. Also chemotherapy may induce cystic degeneration in GIST. And finally metastatic lesions of GIST are always cystic which are often confused with liver cysts[13].

GIST generally presents with non specific symptoms like abdominal pain, vomiting associated with early satiety and abdominal fullness. GIST may present as acute emergencies also with presentations ranging from perforation to obstruction to GI bleed, the latter two being more common with GIST of size > 4cm. As far as perforation is concerned, GIST perforation can be seen anywhere in the GI tract[5,6] but is more frequently seen in small bowel compared to other sites [7]. A total of 22 cases have been reported in literature where GIST has presented as acute emergency[8], 19 patients developed diffuse peritonitis while three had localized abscess adjacent to site of GIST perforation. The rate of morbidity and mortality in all the above mentioned cases was very low probably because of the low contamination due to the proximity of the perforation with most common site being jejunum [8]. Talking about the treatment aspect, complete surgical resection is considered to be the best but recurrence after resection is not uncommon. Complete resection can be achieved in approximately 85% of patients and the estimated incidence of recurrence or metastasis after radical surgery is 50% [9]. Joensuu and Coll [10] proposed a classification

based on tumor rupture and tumor site, this stratification of risk is important for the surgeon to decide whether to start imatinib or not post operatively and depending upon this classification, all the patients with tumor rupture should be considered at high risk and should be started on imatinib. More recently, adjuvant therapy with imatinib has been used with wider indications, such as intermediate-risk tumours with size > 3 cm and primary tumours with rupture or perforation[11, 12].

CONCLUSION

GIST, presenting as an acute emergency and exclusivity are synonymous with each other but it is not rare. Exophytic GIST with cystic degeneration which have communicated with gut lumen and presented as perforation are very rare. A radical approach just like any acute abdomen should be followed but the treatment part doesn't end there at the operating table because once a diagnosis of GIST is confirmed by HPE, a multidisciplinary approach is required for starting adjuvant imatinib therapy considering the notorious nature of this tumor to reappear and encroach upon the epithelium which contains it.

REFERENCES

1. Rubió-Casadevall J, Borràs JL, Carmona C; Temporal trends of incidence and survival of sarcoma of digestive tract including Gastrointestinal Stromal Tumors (GIST) in two areas of the north-east of Spain in the period 1981–2005: a population-based study. *Clin. Transl. Oncol.* 2014;16:660–667.
2. Sandvik OM, Søreide K, Kvaløy JT, Gudlaugsson E, Søreide JA; Epidemiology of gastrointestinal stromal tumors: single-institution experience and clinical presentation over three decades. *Cancer Epidemiol.* 2011;35:515–520.
3. Tryggvason G, Gislason HG, Magnusson MK, Jonasson JG; Gastrointestinal stromal tumors in Iceland, 1990–2003: the Icelandic GIST study, a population-based incidence and pathologic risk stratification study. *Int. J. Cancer.* 2005;117:289–293.
4. Rammohan A, Sathyanesan J, Rajendran K; A gist of gastrointestinal stromal tumors: a review. *World J. Gastrointest. Oncol.* 2013;5:102–112.
5. Sjogren PP, Banerji N, Batts KP, Graczyk MJ, Dunn DH; Rare presentation of a gastrointestinal stromal tumor with spontaneous esophageal perforation: a case report. *Int. J. Surg. Case Rep.* 2013;4:636–639.
6. Yamashita D, Usami Y, Toyosawa S, Hirota S, Imai Y; A case of diffuse infiltrating gastrointestinal stromal tumor of sigmoid colon with perforation. *Pathol. Int.* 2014; 64:34–38.
7. Chen HW, Lin TY; Tumor abscess formation caused by *Morganella morganii* complicated bacteremia in a patient with gastrointestinal stromal tumor. *Clin. Res. Hepatol. Gastroenterol.* 2012;36:e29–e31

8. Alessiani M, Gianola M, Rossi S, Perfetti V, Serra P, Zelaschi D, Magnani E, Cobianchi L; Peritonitis secondary to spontaneous perforation of a primary gastrointestinal stromal tumour of the small intestine: A case report and a literature review. *International journal of surgery case reports*. 2015; 31;6:58-62.
9. Rammohan A, Sathyanesan J, Rajendran K; A gist of gastrointestinal stromal tumors: a review. *World J. Gastrointest. Oncol*. 2013;5:102–112
10. Joensuu H; Risk stratification of patients diagnosed with gastrointestinal stromal tumor. *Hum. Pathol*.2008;39:1411–1419
11. Dematteo RP, Ballman KV, Antonescu CR; Adjuvant mesylate after resection of localized, primary gastrointestinal stromal tumor: a randomized, double blind, placebo-controlled trial. *Lancet*. 2009;373:1097–1104.
12. Joens H, Eriksson M, Sundby Hall K; One vs. three years of adjuvant imatinib for operable gastrointestinal stromal tumor: a randomized trial. *J. Am. Med. Assoc*. 2012;307:1265–1272.
13. Chun-Chao Zhu, Ye Liu, and Gang Zhao; Exophytic gastrointestinal stromal tumor with cystic changes: A case report, *Oncol Lett*. 2014; 7(5): 1427–1429.