

Hydroxyapatite Nanoparticles in the Treatment of Essential Bone Cyst: About A Case

Youness Dahmani*, Ayoub Mjidila, Reda Allah Bassir, Moncef Boufettal, Mohamed Kharmaz, Mustapha Mahfoud, Ahmed El Bardouni, Moulay Omar Lamrani, Mohammed Saleh Berrada

Faculty of Medecine of Rabat, Avenue Mohamed Belarbi El Alaoui B.P.6203 10000, Rabat, Morocco

DOI: [10.36347/sasjs.2021.v07i01.007](https://doi.org/10.36347/sasjs.2021.v07i01.007)

| Received: 10.01.2021 | Accepted: 22.01.2021 | Published: 23.01.2021

*Corresponding author: Youness Dahmani

Abstract

Case Report

Essential bone cyst is a benign, lytic bone lesion with fluid content with central metaphyseal location. It is asymptomatic, can be revealed by a pathological fracture, and its radiological aspect is characteristic. Child of 11 years old, with repeated immobilization for fracture episodes on KOE. Pain and impotence even in the limbs. No avowed trauma. Treatment in case of risk of fracture or in case of pathological fracture. Curettage of the cyst +/- filling with autologous cancellous bone or bone marrow. Treatment with hydroxyapatite nanoparticles is a technique that is very minimally invasive, reliable and free of complications, making it possible to avoid the occurrence of a recurrence and avoid the need for autografts.

Keywords: Essential bone cyst, Pathologic fracture, Benign tumor, hydroxyapatite nanoparticle.

Copyright © 2021 The Author(s): This is an open-access article distributed under the terms of the Creative Commons Attribution 4.0 International License (CC BY-NC 4.0) which permits unrestricted use, distribution, and reproduction in any medium for non-commercial use provided the original author and source are credited.

INTRODUCTION

Essential bone cyst is a benign [1], lytic bone lesion with fluid content with central metaphyseal location.

The physiopathology is uncertain; during the growth period [2], it tends to disappear but is possible for adults to get diaphysis location.

It is asymptomatic, can be revealed by a pathological fracture, its radiological aspect is characteristic.

CASE REPORT

He is an 11 year old child, without any particular antecedent, his history is known by several repeated immobilizations for episodes of fracture on essential bone cyst (Figure-1).

The symptomatology was characterized by pain and functional impotence of the same limb. No notion of avowed trauma.

The surgical procedure consisted of a mini approach at the level of the (deltoid V), with aspiration and curettage of the essential bone cyst and its contents, followed by filling with hydroxyapatite nanoparticles.

We completed the treatment with an additional immobilization for 15 days. The evolution at 7 years was more than satisfactory (Figure-2).

The patient has given their informed consent for the case to be published.

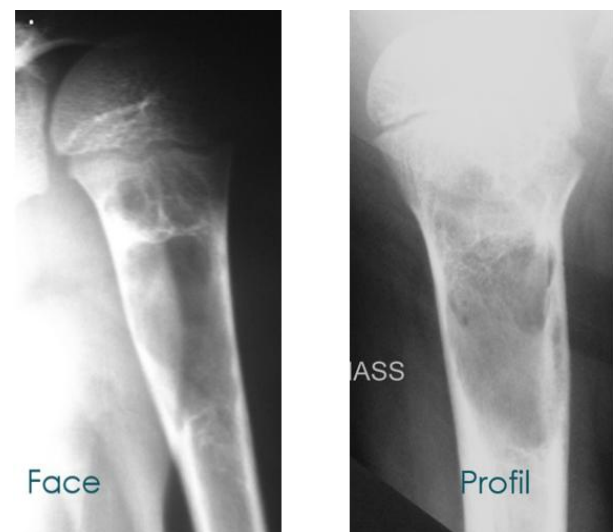


Fig-1: Recurrence of microfracture on KOE left proximal humerus

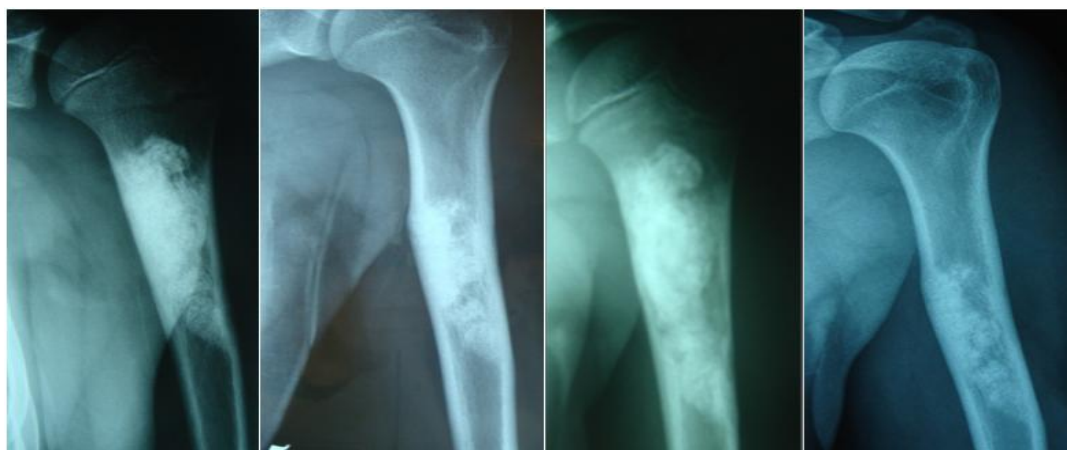

Fig-2: Evolution at 3 months, 1 year, 5 years and 7 years

DISCUSSION

Humeral involvement by essential bone cysts is frequent, with male predominance. It is asymptomatic, can be revealed by a pathological fracture [3].

Treatment is discussed in cases of risk of fracture or pathological fracture. Curettage of the cyst +/- filling with autologous cancellous bone or bone marrow is the treatment of choice [4]. Recurrence reaches 35-65%.

Aspiration followed by corticosteroid injection, however several injections are necessary causing local and general complications.

Several surgical techniques are possible, centromedullary nailing of the upper end of the humerus is rarely used. Decompression by continuous drainage can lead to infection. Resection and reconstruction with the fibula.

Injection of calcium sulfate cement may cause laryngospasm or tachyarrhythmia and Ethibloc injection is dangerous with a risk of pulmonary embolism [5].

Hydroxyapatite nanoparticle gel has the advantage of giving: rapid consolidation, early resumption of activities, no morbidity of iliac and allograft grafts, no risk of infection (decompression) and avoids the risk of pulmonary embolism [6].

CONCLUSION

Treatment with hydroxyapatite nanoparticles is a technique that is very minimally invasive, reliable and free of complications, making it possible to avoid the

occurrence of a recurrence and avoid the need for autologous grafts.

Consent: The patient has given their informed consent for the case to be published.

Competing Interests: The authors declare no competing interest.

Authors' contributions: All authors have read and agreed to the final version of this manuscript and have equally contributed to its content and to the management of the manuscript.

REFERENCES

1. Filipe G, Iefevre P. Essential bone cysts: Bone tumors of the musculoskeletal system: Tumors and benign dystrophies, 2.6.1-1-6 and A1- A3.
2. Cohen J. Simple bone cysts: studies of cyst fluid in six cases with a theory of pathogenesis. *JBJS*. 1960 Jun 1;42(4):609-16.
3. Kaelin A.J, Macewen G.D. Unicameral bone cyst. Naturel history and the risk of fracture. *Int Orthop*. 1989; 13:275-82.
4. Docquier PL, Delloye C. Essential bone cyst. *EMC (Elsevier Masson SAS, Paris), Musculoskeletal system*, 2011; 14-767.
5. Alt V, Bechert T, Steinrücke P, Wagener M, Seidel P, Dingeldein E, Domann E, Schnettler R. An in vitro assessment of the antibacterial properties and cytotoxicity of nanoparticulate silver bone cement. *Biomaterials*. 2004 Aug 1;25(18):4383-91.
6. Alves HL, dos Santos LA, Bergmann CP. Injectability evaluation of tricalcium phosphate bone cement. *Journal of Materials Science: Materials in Medicine*. 2008 May 1;19(5):2241-6.