

Circumcision: A Terrifying Five Years' Experience in Savar, Dhaka

Habibullah T^{1*}, Sarker AK²

¹Dr. Tarafder Habibullah, Assistant Professor, Department of Surgery, Enam Medical & Hospital, Enam Medical College Jame Mosque, Savar Union, Bangladesh

²Dr. Ashok Kumar Sarker, Assistant Professor, Department of Surgery, Enam Medical & Hospital, Enam Medical College Jame Mosque, Savar Union, Bangladesh

DOI: [10.36347/sajs.2021.v07i02.005](https://doi.org/10.36347/sajs.2021.v07i02.005)

| Received: 17.01.2021 | Accepted: 29.01.2021 | Published: 09.02.2021

*Corresponding author: Dr. Tarafder Habibullah

Abstract

Original Research Article

Background: Circumcision is one of the most ancient surgical procedure which is still performed by traditional ritual circumciser with different cultural celebration. But today, science is advanced and this minor surgical procedure can be performed by health care personal without any fatal complications. Despite all the facilities available next to the door, still now in urban area circumcision is performed outside the hospital setting as a result we managed a good number of patient during last couples of years who were admitted in our institution with grave complications.

Objectives: The main objectives of this study is aware the people about grave complications of circumcision specially done by traditional ill-trained circumciser. **Materials and method:** This Cross-sectional study was conducted in Enam Medical College and Hospital from 01.01.2015 to 01.01.2021. Circumcision done outside the hospital settings were included. Demographic data, place of procedure were documented from the legal guardian of the patient. Both early and late complications were assessed. **Results:** A total of 150 cases, out of which 130 cases (86%) post-operative bleeding was most frequent out of which 2(1.3%) cases were found haemophilia. 10 cases (6.6%) needed some sort of revision/reconstructive surgery. **Conclusion:** Like any other surgery, minor post-operative complications may occur even in trained person. But, fatal complications can be avoided by careful peri-operative care.

Keywords: Ritual circumciser, Post-operative bleeding, Revision surgery, Fatal complications, Haemophilia.

Copyright © 2021 The Author(s): This is an open-access article distributed under the terms of the Creative Commons Attribution 4.0 International License (CC BY-NC 4.0) which permits unrestricted use, distribution, and reproduction in any medium for non-commercial use provided the original author and source are credited.

INTRODUCTION

Circumcision is the procedure where the preputial skin is circumferentially excised around the corona of glans penis. And it dates back to ancient times [1]. The procedure can be performed by various technique and has religious, ritual or medical roots [2]. Throughout the world it is practiced mainly in the context of Jewish and Muslim religions [3]. A wide range of complications following circumcision have been recorded so far like bleeding, infection, amputation of glans penis, more or less prepusum excision, meatal stenosis, mucosal adhesion, penile burn etc [4]. In our country, circumcision is performed usually in 1st decade of life and it is our social experience that the procedure is still performed by traditional circumciser, so called 'Hazam' at home. Here in, we studied 150 cases with different complication as a result of circumcision done by 'Hazam' at home.

MATERIALS AND METHOD

It was a cross-sectional study conducted in Enam Medical College and Hospital from 01.01.2015 to 01.01.2021. Circumcision done at home/at local pharmacy done by non-health care person were included. We also did circumcision in our hospital and found some minor complications but it was excluded. Mother or close relatives were interviewed to determine their religion, age, socio-economic status, place of circumcision type of anaesthesia and who performed the procedure but the method could not be assessed. All the cases were examined to confirm their circumcision status, type of complications and necessary relevant investigation were done for proper evaluation. Data was collected from history, investigation findings, OPD record book, emergency admission record book and discharge record volume. Minor complications was defined who needed minor surgical procedure or treated conservatively. And serious adverse events were

defined who needed > 3 days hospital admission, long term complications or life threatening sequelae.

RESULTS

We managed 150 cases of post circumcision complications which was done at home/local pharmacy by traditional circumciser/pharmacy cells man. They are ranged in age from 1 to 12 year out of which 40(26%) cases were performed without any anaesthesia and 110(74%) cases performed under local anaesthesia. Out of 150 cases, 130 cases (86%) were admitted for post-operative bleeding and among those reactionary bleeding was found in 125 (96%) patients, secondary haemorrhage was found in 5(3.8%) cases. In two

patients (1.5%) haemophilia was found for reactionary bleeding. In five patients (3.33%) there was strangulation of glans penis. We did revision circumcision in 8 (5.33%) patients as there was incomplete prepuce excision. And in two (1.33%) cases meatoplasty was performed.

Table-1: Distribution type of Performed Anaesthesia (n -150)

Type of Anaesthesia	n=150	%
Performed without any anaesthesia	40	26.0
Performed under local anaesthesia	110	74.0
Total	150	100.0

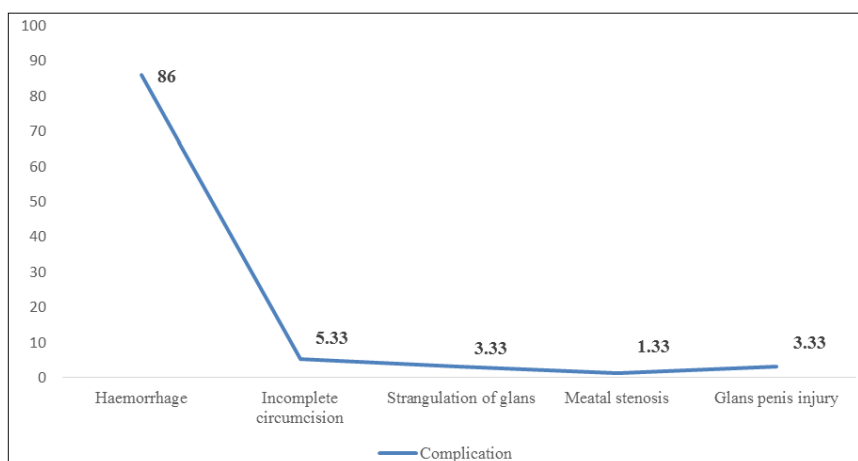


Fig-1: Nature of Complications following circumcision (n=150)

DISCUSSION

There is debate on the benefits and necessity of circumcision. However, from the religious point of view, it is obligatory for a Muslim male to undergo the procedure if at all possible [5]. In Bangladesh, about 90% people are muslim, hence circumcision is frequently performed throughout the year and it is still tradition to do the procedure by traditional circumciser so called 'Hazam'. There are publications that the procedure is not free from complications [6]. A wide range of complications even death, two in a million has been reported [7, 8]. Complications depends on multiple factors, including age, congenital anomalies, surgical technique and the performer also [8]. In previous study, it was seen that there is more chance of complication when the procedure is performed by a nurse junior surgical trainee than by skilled surgeon [9, 10]. This paper will deal with the complications and management following circumcision done in community setting by non-medical person. In our study, we found that a vast majority of post circumcision complications, reactionary haemorrhage was the frequent one. In a study it was seen that in case of neonatal circumcision, bleeding becomes more common during the 'mini-puberty' of infancy that begins at four weeks of age and extends to three months of age. This is thought to be a hormonally mediated increase in penile and prepuce size and vascularity [11]. We didn't

found any case under the age of one year. Most of the cases the operator failed to secure either frenular artery or dorsal subcutaneous penile vessels. Two cases were diagnosed as haemophilia which treated accordingly with consultation of a haematologist. We managed other cases of reactionary haemorrhage with bipolar cauterization under general anaesthesia. We found 5 cases of strangulation of glans-penis following circumcision. We did not find any such case in previous literature following circumcision. But strangulation of penis is not a rare occurrence. The most common motive associated with foreign bodies on the penis is sexual or erotic in nature [12, 13]. The ultimate danger is penile gangrene due to loss of blood supply. In our study, we noticed that there was tight bandage around the corona glandis which acts like a tourniquet. As a result the most distal 3rd of penis became bluish in color. However, after removing the bandage the condition was improved.

We did revision circumcision in 8 patients. It is not uncommon to do revision circumcision after initial procedure. The most common indication of revision circumcision is redundant foreskin [14]. And is occurred when the foreskin around the coronaglandis is less dissected out than the desired plane [15, 16]. In various previous it was shown that this happens more in inexperienced hand most commonly when the

procedure is performed by trainee resident surgeon, family physician, nurse midwife and layman [15-17]. We reported 5 cases of glandular injury. Glandular injury is more common when using the Mogen clamp technique or penile shaft injuries are reported more frequently when the Gomco clamp is used [18]. The glans amputation seen using the Mogen clamp suggests that there may be a common injury mechanism. This mechanism may be an inadequate liberalization of balanopreputial adhesions around the rim. Therefore, it is essential to completely remove the adhesions before excision to reduce the risk of glans amputation. In our study, we could not address the exact technique as the procedure was performed outside the hospital setting and done by 'Layman'.

CONCLUSION

Considering our social belief and tradition it is quite impossible to do circumcision for every child in hospital setting. But if we make the trainee surgeons as well as traditional circumciser adequately trained the post circumcision complications can be minimized.

Funding: No funding sources.

Conflict of interest: None declared.

REFERENCES

- Krill AJ, Palmer LS, Palmer JS. Complications of circumcision. *Scientific World Journal*. 2011; 11:2458-2468.
- Korkes F, Silva JL 2nd, Pompeo AC. Circumcisions for medical reasons in the Brazilian public health system: epidemiology and trends. *Einstein (Sao Paulo)*. 2012; 10(3):342-346.
- Thorup J, Thorup SC, Ifaoui IB. Complication rate after circumcision in a paediatric surgical setting should not be neglected. *Dan Med J*. 2013; 60(8):A4681.
- Roth JD, Keenan AC, Carroll AE, Rink RC, Cain MP, Whittam BM, Bennett Jr WE. Readmission characteristics of elective pediatric circumcisions using large-scale administrative data. *Journal of Pediatric Urology*. 2016 Feb 1;12(1):27-e1.
- Brisson PA, Patel HI, Feins NR. Revision of circumcision in children: Report of 56 cases. *J Pediatr Surg*. 2002; 37(9):1343-1346.
- Prabhakaran S, Ljuhar D, Coleman R, Nataraja RM. Circumcision in the paediatric patient: A review of indications, technique and complications. *J Paediatr Child Health*. 2018; 54(12):1299-1307.
- Gurbak M, Sivasli E, Coskun Y, Bozkurt AI, Ergin A. Prevalence and hematological characteristics of beta-thalassemia trait in Gaziantep urban area, Turkey. *Pediatr Hematol Oncol*. 2006; 23(5):419-425.
- Krill AJ, Palmer LS, Palmer JS. Complications of circumcision. *Scientific World Journal*. 2011; 11:2458-2468.
- Jimoh BM, Odunayo IS, Chinwe I, Akinfolarin OO, Oluwafemi A, Olusanmi EJ. Plastibell circumcision of 2,276 male infants: a multi-centre study. *Pan Afr Med J*. 2016; 23:35.
- Hoschke B, Fenske S, Brookman-May S, Spivak I, Gilfrich C, Fritsche HM, Wolff I, May M. Male circumcision is not associated with an increased prevalence of erectile dysfunction: Results of the Cottbus 10,000-men survey. *Der Urologe. Ausg. A*. 2013 Apr;52(4):562-569.
- Weiss HA, Larke N, Halperin D, Schenker I. Complications of circumcision in male neonates, infants and children: a systematic review. *BMC Urol*. 2010, 10:2.
- Dias J, Freitas R, Amorim R, Espiridião P, Xambre L, Ferraz L. Adult circumcision and male sexual health: a retrospective analysis. *Andrologia*. 2014, 46:459-464.
- VanBuskirk K, Winer RL, Hughes JP, Feng Q, Arima Y, Lee SK, Stern ME, O'Reilly SF, Koutsky LA. Circumcision and acquisition of HPV infection in young men. *Sexually transmitted diseases*. 2011 Nov;38(11):1074-1081.
- Wamai RG, Morris BJ, Bailis SA, Sokal D, Klausner JD, Appleton R, Sewankambo N, Cooper DA, Bongaarts J, de Bruyn G, Wodak AD. Male circumcision for HIV prevention: current evidence and implementation in sub-Saharan Africa. *Journal of the International AIDS Society*. 2011 Dec 1;14(1):49.
- Bailey RC, Moses S, Parker CB, Agot K, Maclean I, Krieger JN, Williams CF, Campbell RT, Ndinya-Achola JO. Male circumcision for HIV prevention in young men in Kisumu, Kenya: a randomised controlled trial. *The lancet*. 2007 Feb 24;369(9562):643-56.
- Morris BJ. Why circumcision is a biomedical imperative for the 21st century. *Bioessays*. 2007, 29:1147-1158.
- Drain PK, Halperin DT, Hughes JP, Klausner JD, Bailey RC. Male circumcision, religion, and infectious diseases: an ecologic analysis of 118 developing countries. *BMC Infect Dis*. 2006, 6:172.
- Shittu OB, Shokunbi WA. Circumcision in haemophiliacs: the Nigerian experience *.Haemophilia*. 2001, 7:534-536.