

Case Report

White tumor Induced Carpal Tunnel Syndrome: case report

Youssef Elbir^{*1}, Yassine Sedrati¹, Imad Elghordaf¹, Karim Bennani¹, Rida-Allah.Bassir¹, Monsef Bofettal¹,
Ahmed. El Bardouni¹, Mohamed S. Berrada¹.

Faiza.Arab², Hanane.lamine², Jawad.Tadili², Ali.kettani², Mamoun.Faroudy²

¹Orthopedic surgery department of Ibn Sina hospital, University Mohamed V, Rabat, Morocco

²Anesthesia reanimation surgical department of Ibn Sina hospital RUCH, University Mohamed V, Rabat, Morocco

***Corresponding author**

Dr Youssef Elbir

Email: elbir.youssef3@gmail.com

Abstract: Carpal tunnel syndrome caused by tuberculosis (TB) is a rare presentation of this disease. We report the case of a 32-year-old male presenting a swelling in the left wrist associated to paresthesia in the second and third ipsilateral fingers. EMG findings were compatible with carpal tunnel syndrome. The radiographs revealed a volar mass and geodes of the first row of the wrist. Histological examination confirmed diagnosis. Antibacillary chemotherapy produces excellent results.

Keywords: tuberculosis, Carpal Tunnel Syndrome, wrist.

INTRODUCTION

Tuberculosis remains a major international problem despite advances in radiological diagnosis and antituberculous therapy. The world health organization (WHO) reported that about 9 million people developed tuberculosis in 2013. Morocco is an endemic country with an incidence 89 by 100,000 inhabitants in 2015. Some developed countries have now recorded resurgence in the incidence of tuberculosis, attributed, particularly in the USA, to a rise in the number of people with immunosuppression. Tuberculosis of the hand and the wrist remains exceptional (2–4%) of all extrapulmonary forms of tuberculosis. Musculoskeletal tuberculosis arises from haematogenous seeding of the bacilli soon after the initial pulmonary infection. The clinical symptoms are insidious. Subsequently, there may be delays in diagnosis and therapy. We report a case of tenosynovitis tuberculous induced a carpal tunnel syndrome.

CASE REPORT

32 years old Moroccan male, labor was admitted with a six-month history of soft tissue swelling in the left wrist. He initially noticed a small swelling on the left wrist which eventually increased in size, associated to paresthesia in the second and third ipsilateral fingers. There was no past history of antitubercular treatment as well as there was no family history of tuberculosis. On review of symptoms, the patient reported a dysesthesias of the left second and third finger which had gradually worsened. He denied any trauma to the site, associated fevers, or chills. No other acute symptoms were reported by the patient. On

evaluation the patient was thin and poorly nourished, but in no acute distress. The blood pressure was 120/80 mm Hg, pulse 75 beats per minute, temperature 37,2 C, and respirations 18 breaths per minute. In general, he appeared to be cachectic. His cardiovascular, gastrointestinal and respiratory system examination was normal. A 4 cm × 2 cm non tender, firm swelling located on the anterior left wrist (Figure 1). There was no erythema of the surrounding skin. Motor and sensory examinations revealed hypoesthesia on palmar side of the index and middle fingers was present; Phalen's test and Tinel's sign were positive. There was no lymphadenopathy noted in the axillary areas. Routine laboratory data was normal, including complete blood count, renal and liver function tests. Erythrocyte sedimentation rate (ESR) was 33. The HIV serology and hepatitis (B, C) serology were negative, as well as the tuberculin skin test. Nerve-conduction studies of the median nerve were compatible with carpal tunnel syndrome. Plain x-ray images of the left wrist demonstrate geodes affecting the distal ulna scaphoid and capitatum. (Figure 2) The Magnetic resonance images demonstrated a volar mass 4 × 1 × 2-cm homogenous mass with low T1 signal, increased signal on T2-weighted, compressing median nerve. (Figure 3) The MRI scan of the wrist revealed a Signal anomaly of the scaphoid, the semi lunar, The capitatum, the trapez With pinching of the inter-carpal interline. The articular face of the radius and styloid of ulna showed chondral geodes with significant articular effusion and enhancement of the synovial. (Figure 3) Biopsy of tumor whose histological result was a surprise showing the presence of an epithelioid giant cell granuloma with

caseous necrosis. (Figure 4.5) A work-up to evaluate for pulmonary tuberculosis was negative. The patient was then started on a 4-drug anti-tubercular therapy with

isoniazid, rifampin, ethambutol, pyrazinamide At his out-patient follow-up visit at our clinic he has shown good clinical improvement.

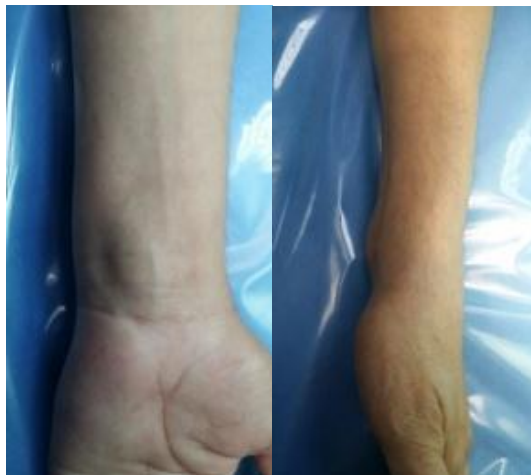

Fig-1: Clinical appearance showing the swelling

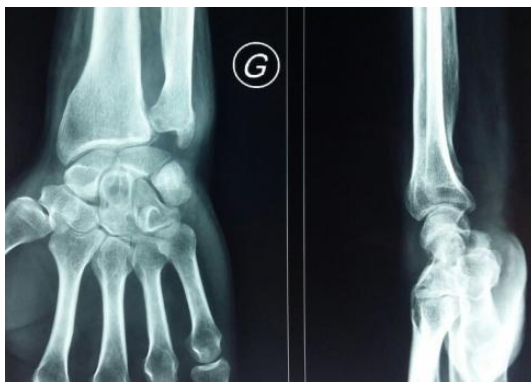

Fig-2: Anteroposterior and lateral radiographic images of the wrist : showed geodes affecting the distal ulna scaphoid and capitatum

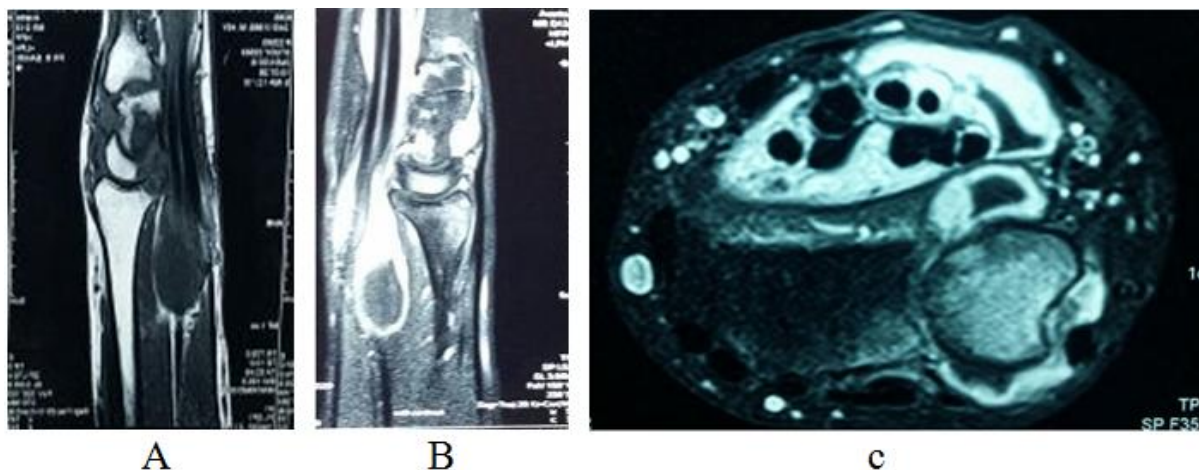


Fig-3: Magnetic resonance images. (A) T1-Weighted sagittal (B) T1-Weighted sagittal postcontrast. (c) T1-Weighted axial images demonstrating carpal mass compressing median nerve

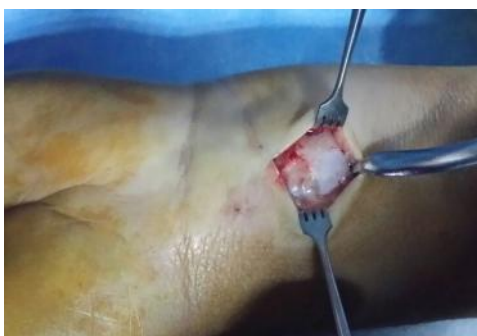

Fig-4: Intraoperative photograph shows the mass

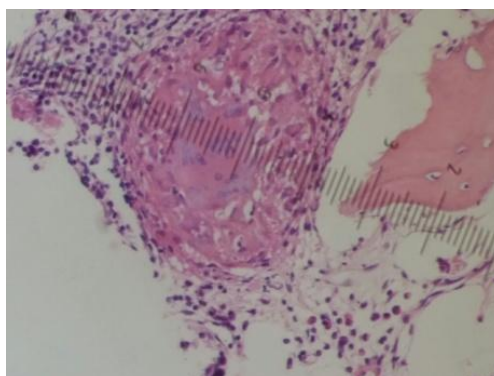


Fig-5: Granuloma caseous necrosis

DISCUSSION

Tuberculosis is rampant and endemic in developing countries. Musculoskeletal involvement occurs in only 1-15% of all cases of TB. Tuberculous tenosynovitis represents only 5% of bone and joint TB and usually involves the Wrist and palmar side of the hand [1, 10, 11]. The osseous inoculation is usually hematogenous from an active or sleeping pulmonary or gastrointestinal tract and in about 30% of bone tuberculosis, the chest is positive for tuberculosis [5]. Tuberculosis-induced carpal tunnel syndrome is rare. While carpal tunnel syndrome can be observed in cases of an infringement of the wrist flexors [7]. Clinical symptoms are very nonspecific and can include insidious onset of pain weight loss, grade fever, night sweats, generalized malaise and decreased appetite. The classic symptoms of disseminated tuberculosis (night sweats, asthenia and anorexia) are variable in 25---40% of cases [1, 2]. There is usually delay in the diagnosis, and may lead to an advanced stage of articular destruction with abscess discharges. Radiographic signs are nonspecific as well, including soft tissue swelling, osteopenia, joint space narrowing, and subchondral erosions. The CT can then be more specific. A geode and a joint space narrowing are more suggestive. The geode is usually in the scaphoid or the semi-lunar [3, 9]. The magnetic resonance imaging (MRI) is recommended for better delineation. The MRI's imaging features are granulomatous synovial tendon sheaths in the intermediate T1 signal with enhancement by gadolinium and an hyperintense T2 signal, abscess formation, and destruction of adjacent bone. Bone scintigraphy with Tc-99 is useful to rule out

polyarticular involvement. A positive tuberculin skin test is an important clue in patients with tuberculosis, but it can be negative in 10% of the patients. Although in some patients the ESR can be elevated, it is often normal. The gold standard for diagnosis is the isolation of *Mycobacterium tuberculosis* from cultures of biopsy material. The direct examination is positive in 20% of the cases and culture is negative in 35-45%. The diagnosis often has to be made based on the granulomatous appearance histologically, along with high clinical and radiographic suspicion. Differential diagnostic considerations villonodular synovitis, sarcoidosis, pyogenic, fungal infections, brucellosis, Rheumatoid arthritis, gouty arthritis [10,11], Current recommendations for the treatment of osseous tuberculosis include a 2-month initial phase of isoniazid, rifampicin, pyrazinamide, and ethambutol followed by a 6- to 12-month regimen of isoniazid and rifampicin [9, 4]. Other than the biopsy, there is very little need for surgery. The orthopedic immobilization splint may be useful until the disappearance of clinical signs (3-4 weeks), followed by rehabilitation.

CONCLUSION

In summary, the possibility of CTS secondary to TB should be kept in mind in case of insidious and slow growing swollen.

In the present of a clinical histopathological, radiological, picture compatible with TB in endemic areas. It is therefore indispensable to bear in mind the possibility of such atypical presentations of tuberculosis

when making a rapid and pertinent diagnosis and prescribing appropriate treatment.

REFERENCES

1. Marques VB, Vieira HP, Alcantara CC, Braga FN, Rocha FA, Medeiros MC. Tenosynovitis and carpal tunnel syndrome from mycobacterium tuberculosis- a rare manifestation of extrapulmonary tuberculosis. *Acta Reumatológica Portuguesa*. 2010 Jan 1; 35(1).
2. Sbai MA, Benzarti S, Bouzaidi K, Sbei F, Maalla R. A rare localization of tuberculosis of the wrist: The scapholunate joint. *International journal of mycobacteriology*. 2015 Jun 30; 4(2):161-4.
3. Wu KC, Tang HM, Yeh KT, Ding DC. Extrapulmonary tuberculosis in the wrist presenting as a ganglion cyst-like mass: A case report. *Tzu Chi Medical Journal*. 2012 Jun 30; 24(2):77-9.
4. Dlimi F, Bellarbi S, Mahfoud M, Berrada MS, El Bardouni A, El Yaacoubi M. Tuberculosis of the hand and wrist: different aspects of 30 cases. *Chirurgie de la main*. 2011 Jun; 30(3):198-204.
5. Hassanpour SE, Gousheh J. Mycobacterium tuberculosis-induced carpal tunnel syndrome: management and follow-up evaluation. *The Journal of hand surgery*. 2006 Apr 30; 31(4):575-9.
6. Lozano PT, Sanchis DG, Coello MP. Osteoarticular tuberculosis with destructive wrist arthritis secondary to extrapulmonary tuberculosis. *Revista Española de Cirugía Ortopédica y Traumatología (English Edition)*. 2012 Oct 31; 56(5):378-80.
7. Al-Qattan MM, Al-Namla A, Al-Thunayan A, Al-Omawi M. Tuberculosis of the hand. *The Journal of hand surgery*. 2011 Aug 31; 36(8):1413-21.
8. Yalcinkaya M, Akman YE, Bagatur AE. Unilateral carpal tunnel syndrome caused by an occult ganglion in the carpal tunnel: a report of two cases. *Case reports in orthopedics*. 2014 Jul 6; 2014.
9. Bassir RA, Saoudi F, Ismael F, Lamrani MO, Kharmaz M, Elbardouni A, Mahfoud M, Berrada MS, Elyaacoubi M. Bifocal musculoskeletal tuberculosis in upper limb: Unusual case. *International journal of mycobacteriology*. 2014 Sep 30; 3(3):217-9.
10. Fiany E, Oniankitan O, Agoda-Koussema LK, Koffi-Tessio VE, Mijiyawa M. White tumor of the wrist: A rare localization of tuberculosis. *The Egyptian Rheumatologist*. 2015 Jan 31; 37(1):45-7.
11. Stütz N, Gohritz A, Van Schoonhoven J, Lanz U. Revision surgery after carpal tunnel release—analysis of the pathology in 200 cases during a 2 year period. *Journal of Hand Surgery*. 2006 Feb; 31(1):68-71.
12. Miladi S, Dhahri R, Hamdi W, Kaffel D, Abid L, Farah F, Kchir MM. Wrist synovectomy confirmed tuberculous tenosynovitis in 8 cases: A follow-up study. *The Egyptian Rheumatologist*. 2016 Jul 31; 38(3):257-61.