

## Personalized 3D Printed Molds, A Novel Economical Solution for Cranioplasty

Elhajjami A\*, Boutakioute B, Ouali Idrissi M, Idrissi Ganouni N, Benyaich Z, Ghannane H, Ait Benali S

Radiology Department, Arrazi Hospital, Mohammed VIth University Hospital Center, Caddi Ayyad University, Marrakech, Morocco

DOI: [10.36347/sjmc.2021.v09i04.029](https://doi.org/10.36347/sjmc.2021.v09i04.029)

| Received: 09.01.2021 | Accepted: 21.01.2021 | Published: 27.04.2021

\*Corresponding author: Ayoub Elhajjami

### Abstract

### Original Research Article

**Objectives:** Customized cranioplasty implants are anatomically more accurate than manually shaped implants but remain costly. We describe a cost-effective technique of producing customized cranioplasty implants with the use of 3-dimensional (3D) printed molds. **Methods:** The patient had a left parietal cranial defect after a craniectomy for cranial trauma. A 3D image of his skull was obtained from computed tomography (CT) scan images. The image of the implant was generated by a digital subtraction mirror-imaging process using the normal side of his cranium as a model. Intraoperatively, the mold was put in a sterile bag and then used to cast a customized implant subsequently trimmed before fixation. **Results:** The patients had excellent cosmetic results and underwent postoperative CT scans that showed excellent restoration of the symmetrical contours of the cranium. No neurologic or infectious complications occurred over a 6-month follow-up for the patient. **Conclusions:** Making customized cranioplasty implants via 3D printed polylactic acid molds is a cost-effective technique for delayed reconstruction of various cranial defects.

**Keywords:** 3D Printed Molds, Novel Economical Solution, Cranioplasty.

Copyright © 2021 The Author(s): This is an open-access article distributed under the terms of the Creative Commons Attribution 4.0 International License (CC BY-NC 4.0) which permits unrestricted use, distribution, and reproduction in any medium for non-commercial use provided the original author and source are credited.

## INTRODUCTION

Cranioplasty is a surgical procedure used to correct a defect in a bone of the skull. The defect might be congenital, the result of trauma to the head or a complication from an earlier surgery. A cranioplasty will not only improve the appearance of the head, but also may provide several medical benefits.

In modern neurosurgery, cranioplasty is the procedure of repairing a skull vault defect by insertion of an object (bone or nonbiological materials such as metal or plastic plates). Brain protection and cosmetic aspects are the major indications of cranioplasty [i].

Repairing of the cranial imperfections has a principle objective to ensure the related tissues of the brain, to diminish torment at the site of the deformity, improve the appearance and decline the patient's stress [ii]. The human body can't recover a lost body part, yet remaking can be acquired through a multi-disciplinary methodology and the arrangement of prosthesis. Cranioplasty is one of the most established neurosurgical strategies, rehearsed since 3000 BC [iii].

For a considerable length of time, a few materials have been tried to cover bony imperfections

including coconut shells, allogenic and xenogenic bone unions, metals and modern of all, the biosynthetic materials, for example, ceramics and resins [iv].

Cranioplasties finished with alloplastic materials are well known as acknowledged treatment strategies. The ideal attributes of prosthetic materials are their incapacibilities to create inflammatory responses, non-allergenicity, or powerlessness to create hypersensitivity, non-cancer-causing nature, and chemical inertness, capacity to withstand pressure, sterilization ability and to be formed into the ideal shape when created [v].

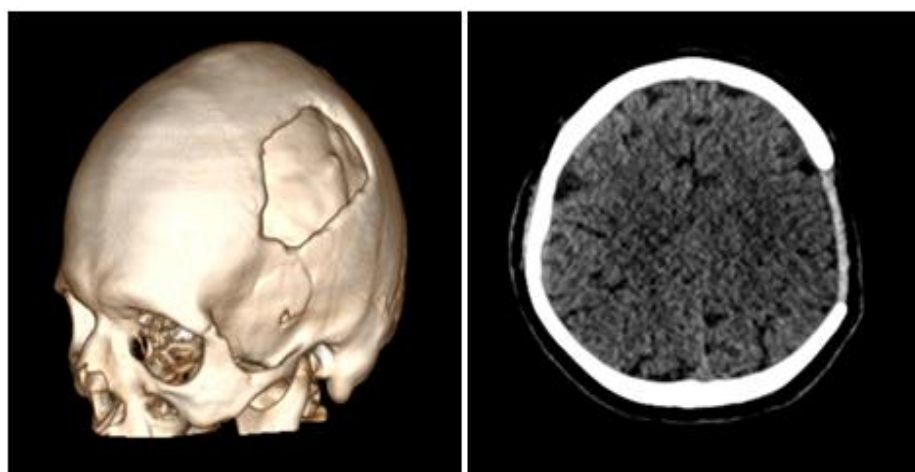
3D modeling and printing of prosthetic material bring about an astounding restorative result and decrease working time fundamental for placement of implants [vi].

## MATERIAL AND METHODS

The data used to generate 3D printed medical models are acquired from a recent non injected brain CT scan. An ideal acquisition should be free of image artifacts and present an isotropic resolution of the voxel. It should have high image contrast between the anatomy of interest and neighboring tissues and low noise.

A slice thickness of 0.5 to 1.5 mm is sufficient.

The acquired data is saved in DICOM format.



**Fig-1: CT in axial sections with VRT reconstruction**

### Prosthesis mold digital design

The CT exam is saved in the standard system DICOM (Digital Images and Communications in Medicine). A bone filter is applied so as to just watch the bone structure, accomplished by taking into account its constriction degree.

The Dicom file is loaded into 3Dslicer where a thresholding tool is used to segment the skull, the model is then corrected for meshing issues and the area of interest is isolated using various clipping tools in Meshmixer.

The resulting 3D model is then loaded in Materialize 3Matic, where the skull model is prepared and the outline of the gap delimited, a mirror of the healthy geometry is created to create a guiding curve.

The cranial plate is created with variable thickness using different measurements of the skull, and the undercuts are removed to permit the insertion of the cranial plate, it is then finished using smoothing and edge chamfering.

The mold is made using Boolean operation subtraction with a precreated shape (rectangular cuboid), which is then cut in two to make a two-part mold or the top removed to create a one-part mold.

At the end, the information is sent out in a stereolithography expansion document (STL) and provided to the printer.

### 3D printing

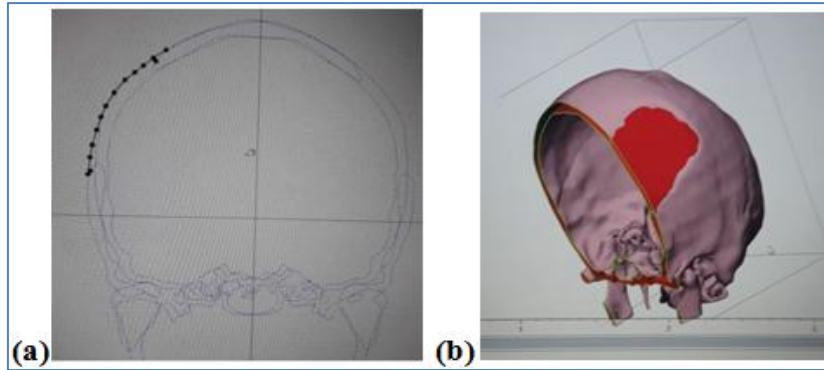
A Creality Ender 3 printer is utilized to print out a PLA prosthesis from the STL record utilizing a model of fused deposition by methods for a 1.75 mm filament at a 210 °C temperature. When the printing procedure is done in around 12 h.

### Surgery


The mold is put into sterilizing fluid (Cydex) and put inside sterile nylon bags. Bone cement is used to create a cranial plate on the same mold which is then fixed to the skull using cranial plates.

## RESULTS

The individual with the cranial imperfection experienced a cranioplasty with independently customized prefabricated molds produced from a 3D printed layout. This kind of cranial vault reproduction requires little trans-operative alteration time, since most modifications are done pre-operatively, and the prosthesis adjusts definitely to the imperfection (this was estimated by following the prosthesis and its changes on to a millimeter paper), reestablishing cranial symmetry flawlessly (a correlation of the intact side against the side with the deformity) without the weight of an exothermic response on cerebrum tissue, and insignificant creation cost. There were no unfavorable occasions, for example, prosthesis introduction, seroma, contaminations, nor any harmfulness or encephalic inflammation since the cerebral tissue was not presented to an exothermic response in the OR. Following a multi-month post-operative development, the cranioplasty patient had a proper neurological advancement characterized by estimating their motor skills as well as cognitive.

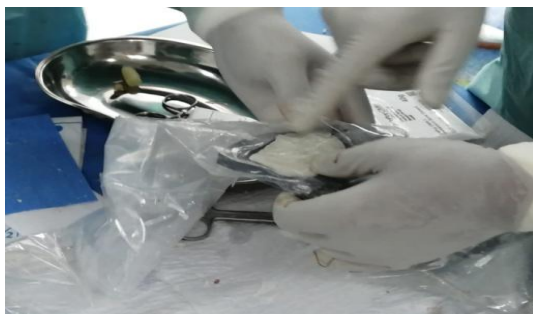

**Fig-1: (a) Modeling of the cranioplasty prosthesis (b) the mold in 1 and 2 pieces**

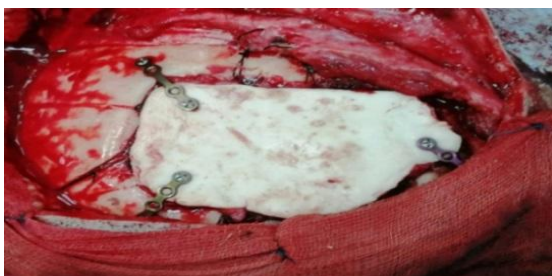

**Fig-2: Impression and Modeling**

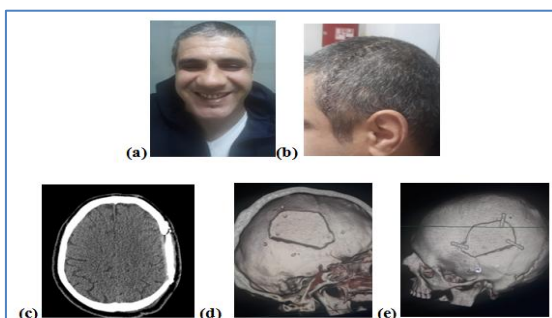**(a) Impression 3D du crane. (b &c) 3D printing of the mold in 1 and 2 pieces. (d) Cranioplasty mold test with pre-op plate**



**Fig-3: Placement of bone cement in the mold surrounded by a sterile nylon film**



**Fig-4: Fixation of the prosthesis by screwed plates**



**Fig-5: Post-operative controls (a & b) Control post-op (c, d & e) CT + VRT control**

## DISCUSSION

In this article, we described a new cost-effective technique of producing customized implants using low-cost 3D-printed single-piece PLA molds that provided excellent cosmetic outcome in two patients. The hefty costs of prefabricated patient-specific implants prompted the research for more accessible techniques with equal cosmetic results. In our institution and according to the published literature, the price of prefabricated titanium, PEEK or hydroxyapatite implants is above 7500 usd.

Several techniques were developed to facilitate manual shaping of PMMA, using the cranial borders of the defect as a guide for molding, either preoperatively or intraoperatively. These techniques are best suited for delayed cranioplasties with small defects. Others have used the cranial flap as a mold to produce a two-piece handmade silicon mold preoperatively<sup>33</sup> or a PMMA negative form intraoperatively that will serve along with the cranial flap as the final two-piece mold to produce a PMMA implant away from the cortex.<sup>16</sup> The latter technique described by Marbacher *et al.* can be applied either in immediate or delayed cranioplasty procedures but requires a fairly intact bone flap, which cannot be available in case of extensive tumor invasion, resorption, complex fractures or prior craniectomy in another institution.

Since the external surface of an implant is the most responsible component for the final cosmetic outcome, we decided to adopt a technique similar to that of Tan *et al.* by 3D printing a single-piece PLA mold of the external surface of the defect instead of its internal surface with open borders.

Although wrapping the mold in a sterile bag may result in minor wrinkles on the implant surface that are small enough to be detectable on the scalp it eliminates the need for prior sterilization of any of the components needed to produce the implant. These wrinkles can be avoided by prior sterilization of the mold with ethylene oxide if available. We opted for this sterile molding method of PMMA away from the cortex since our institution lacks sterilization facilities with ethylene oxide while PLA molds, with a glass transition temperature of 55°C, 39 deform significantly when sterilized in autoclaves and can be deformed during polymerization. This process still fails in case of a cranial defect crossing the midline, which emphasizes the importance of CT scanning the cranial flap before discarding it. The acquired information can be sent to

another institution if such a customized mold and implant cannot be made in the hospital where the patient is operated for craniectomy.

## CONCLUSION

This study demonstrates the viability of 3D printed pre-assembled molds for cranioplasty. Cranial symmetry is accomplished flawlessly, minimal intraoperative time is required for modifications, and coaptation is exact.

Quick prototyping 3D-printing innovations give a down to earth and anatomically exact, patient-specific models. Development of this innovation in neurosurgery will serve experts, learners, and patients.

## REFERENCE

1. Moin H, Mohagheghzadeh P and Darbansheikh A. The use of frozen autogenous bone flap for cranioplasty. *JRMS*. 2005; 10: 395–7.
2. Beumer J, Firtell DN and Curtis TA. Current concepts in cranioplasty. *The Journal of Prosthetic Dentistry*. 1979; 42(1), 67-77. [https://doi.org/10.1016/0022-3913\(79\)90332-9](https://doi.org/10.1016/0022-3913(79)90332-9)
3. Pietrzak WS. *Musculoskeletal tissue regeneration: Biological materials and methods*. Springer Science & Business Media; 2008.
4. Abdulai A, Iddrissu M and Dakurah T. Cranioplasty using polymethyl methacrylate implant constructed from an alginate impression and wax elimination technique. *Ghana medical journal*. 2006; 40(1), 18–21.
5. Roa TT. *Materiales inertes*. In: En Coiffman F, editor. *Texto de Cirugía Plástica, Reconstructiva y Estética*. Barcelona, Salvat Editores. 1986; 805–808.
6. Eufinger H and Saylor B. Computer-assisted prefabrication of individual craniofacial implants. *AORN Journal*. 2001 ; 74(5), 648-654. [https://doi.org/10.1016/s0001-2092\(06\)61763-8](https://doi.org/10.1016/s0001-2092(06)61763-8).