

## Primary Clear Cell Carcinoma of the Vagina Not Associated with Diethylstilboestrol A Case Report and Literature Review

Oumayma Bounid<sup>1\*</sup>, Mehdi Raouah<sup>1</sup>, Rukkaya Iharti<sup>1</sup>, Youness El-khadir<sup>1</sup>, Yassine Bouchabaka<sup>1</sup>, Hind Riahi<sup>1</sup>, Mouna Darfaoui<sup>1</sup>, Issam Lalya<sup>1</sup>, Abdelhamid Elomrani<sup>1</sup>, Mouna Khouchani<sup>1</sup>

<sup>1</sup>Hematology and Oncology hospital, Radiation Oncology Department, Faculty of Medicine and Pharmacie, Cadi Ayyad University, Marrakech, Morocco

DOI: [10.36347/sjmcr.2021.v09i04.046](https://doi.org/10.36347/sjmcr.2021.v09i04.046)

| Received: 07.03.2021 | Accepted: 05.04.2021 | Published: 30.04.2021

\*Corresponding author: Oumayma Bounid

### Abstract

### Case Report

Clear cell adenocarcinoma is a histological type rarely found among cancers of the vagina. It is often described in young women previously exposed to diethylstilboestrol (DES) taken by mothers during pregnancy. Its prognosis is pejorative, requiring early and modified management according to each case. Given the insufficient data in the literature, we find it important and useful to report and discuss through the rare case of our elderly patient without any notion of exposure to DES, the diagnosis, the therapeutic management and the prognosis of this type of cancer.

**Keywords:** Vagina, clear cells adenocarcinoma, radiation therapy, surgery, prognosis.

Copyright © 2021 The Author(s): This is an open-access article distributed under the terms of the Creative Commons Attribution 4.0 International License (CC BY-NC 4.0) which permits unrestricted use, distribution, and reproduction in any medium for non-commercial use provided the original author and source are credited.

## INTRODUCTION

Primary vaginal cancers are rare and represent less than 1.4% of all gynecological malignancies [1]. Clear cell adenocarcinoma is a rare malignant tumor in the gynecologic tracts, rarer in the vagina, usually occurring in young women previously exposed in utero to synthetic diethylstilboestrol (DES), used to prevent abortion during pregnancy [2]. Particularly, primary clear cell vaginal carcinoma not associated with DES is extremely rare, with a mostly poor prognosis showing a poor response to adjuvant treatment [3], and a high frequency of distant metastases, especially pulmonary ones [4]. We report a case of vaginal clear cell adenocarcinoma in an elderly woman not previously exposed to DES.

## CASE

Mme O.R is a 60-year-old woman, followed for high blood pressure, who initially consulted a gynecologist for post-menopausal bleeding that has progressed for a year without other associated signs. The initial clinical examination objectified the presence of a tumor process at the expense of the upper 2/3 of the vagina with induration of the rectovaginal septum. A biopsy was taken with a morphological and immunohistochemical appearance of a clear cell vaginal adenocarcinoma. The pelvic MRI objectified the presence of a tumoral process of the posterior surface of

the vagina of 14 x 38 x 45 mm, hemicircumferential, which infiltrates the right paravagina and which arrives in intimate contact with the rectal wall behind but without infiltration signs, without extension to other neighboring organs or to the lymph nodes. A Thoraco-Abdomino-Pelvic CT scan assessing distance extension was normal, classifying the tumor at stage II by the International Federation of Gynecology and Obstetrics (FIGO 2018).

The decision of the multidisciplinary consensus meeting was for a posterior pelvicotomy with definitive colostomy, but the patient refused the surgery, and a concomitant first chemoradiotherapy was decided.

The patient received external radiotherapy of 45Gy in 25 sessions of 1.8 Gy in 5 weeks associated with 5 chemotherapy cures of cisplatin 40 mg/m<sup>2</sup> weekly concomitantly with good tolerance.

The clinical evaluation found the persistence of the right posterolateral process limited to the upper half of the vagina and the control MRI showed an estimated tumor regression of 23.6% and then the patient was referred for surgery.

## DISCUSSION

Primary vaginal cancer is a rare tumor that occurs in women between the ages of 60 and 70.

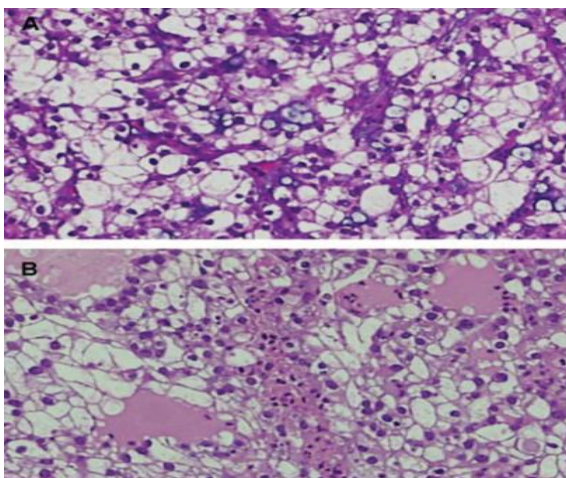
Adenocarcinoma is a rare pathological entity and occurs in 14% of primary vaginal tumors. The clear cell type is more common in young girls previously exposed to DES treatment during pregnancy [5].

From a histological point of view, the vaginal mucosa is formed by a squamous not keratinized epithelium and devoid of glands, which explains the frequency of the squamous cell carcinoma type and makes the development of adenocarcinoma, in particular with clear cells, a mystery. Prenatal DES exposure is an inducer of genomic instability and may be an important factor in the carcinogenesis of clear cell ADKs [6]. This association has been proven and confirmed by several studies since 1971 [7, 8]. As the first case of cancer induced by exposure to prenatal drugs in humans [9], although this histological type was described a few years later in elderly women without DES exposure [3]. The malignant transformation of vaginal adenosis without prenatal DES exposure, due to residual Mullerian cells in the vaginal walls may be a probable origin of this rare histological type of cancer, reported in few publications [10].

The diagnosis is most often made after the appearance of painless metrorrhagia, sometimes leucorrhoea or pelvic pain, urinary or rectal signs for the most advanced stages. Asymptomatic forms can be diagnosed during screening for cervical cancer.

The clinical examination is important for diagnosis, therapeutic or even prognosis. It must be done by an oncologist-gynecologist and an oncologist-radiotherapist.

Anatomo-pathological confirmation of the histological type is done on a biopsy or on an operative specimen, sometimes using, in addition to the morphological study, a complement by immunohistochemistry, in particular for small biopsies [11].



**Fig-1: Microscopic appearance: Large clear cells with hyperchromasia, a high nuclear-cytoplasmic ratio and irregular nuclear membranes [12]**

Imaging has a very important role in the diagnosis and management of this type of cancer. In any patient presenting with a primary vaginal clear cell adenocarcinoma not associated with DES, an in-depth assessment must be performed in order to exclude its secondary origin from other malignant tumors (gynecological, gastrointestinal, renal, etc.), in particular Fluorine-18 fluorodeoxyglucose positron emission tomography (18F-FDG-PET) [3, 13], which could not be done in our case by lack of means.

MRI is the most reliable and precise imaging technique for evaluating locoregional extension and tumor stage which will determine not only the therapeutic choice but also the prognosis, through its excellent soft tissue resolution. It must specify the seat which is most often at the level of the upper third of the vagina, the tumor volume, the extension to the parameters and locoregional towards the bladder, the rectum, the pelvic wall and the lymph nodes [4, 14].

As a rare primary cancer, its management is not well defined, often decided on a case by case basis, by referring to experiences with cervical cancer and the few studies available. Concomitant chemoradiotherapy and brachytherapy to preserve the organ is a therapeutic option, its local control rate and five years survival was significantly lower compared to squamous cell carcinoma in the study conducted by Frank and Al in 2007 [3].

Surgery is reserved for the early clinical stages, with favorable rates of specific survival and local control at five years, considered mutilating for the advanced stages [1]. It may be the option of choice for curative purposes in a salvage situation for locally advanced clear cell vaginal adenocarcinoma persisting after irradiation[15].

The prognosis of primary clear cell vaginal adenocarcinoma is markedly poorer than that of squamous cell carcinoma, particularly if not associated with DES exposure. The stage is a very important prognostic marker, and is a determinant of treatment strategy [16, 17]. Huo and al concluded that clear cell adenocarcinoma of the vagina without DES exposure has the peculiarity of progressing more rapidly, of relapsing early, with a higher mortality rate and potential for distant metastasis [18].

## CONCLUSION

Primary clear cell adenocarcinoma of the vagina without previous exposure to diethylstilboestrol is very rare, that the etiology and natural history still remain uncertain. Treatment guidelines and prognosis require careful assessment of patient and tumor factors for better management. Further studies should be conducted and new cases should be reported to provide a baseline for its diagnosis and management.

**Conflicts of interest**

The authors have declared no conflicts of interest.

**REFERENCES**

- Nomura H, Tanaka Y, Omi M, Netsu S, Aoki Y, Tanigawa T, Kurita T, Matoda M, Okamoto S, Omatsu K, Kanao H. Surgical outcomes of early-stage primary vaginal nonsquamous cell carcinoma. *International journal of clinical oncology*. 2020 Jul;25(7):1412-7.
- Watanabe Y, Ueda H, Nozaki K, Kyoda A, Nakajima H, Hoshiai H, Noda K. Advanced primary clear cell carcinoma of the vagina not associated with diethylstilbestrol. *Acta cytologica*. 2002 May 1;46(3):577-81.
- Frank SJ, Deavers MT, Jhingran A, Bodurka DC, Eifel PJ. Primary adenocarcinoma of the vagina not associated with diethylstilbestrol (DES) exposure. *Gynecologic oncology*. 2007 May 1;105(2):470-4.
- Nomura H, Matoda M, Okamoto S, Omatsu K, Kondo E, Kato K, Umayahara K, Takeshima N. Clinical Characteristics of Non-Squamous Cell Carcinoma of the Vagina. *International Journal of Gynecologic Cancer*. 2015 Feb 1;25(2).
- Hasanzadeh M, Jafarian AH, Seresht LM. Primary Clear Cell Carcinoma with no Diethylstilbestrol Exposure; Case Series. *Iranian journal of medical sciences*. 2019 Mar;44(2):163.
- Boyd J, Takahashi H, Waggoner SE, Jones LA, Hajek RA, Wharton JT, Liu FS, Fujino T, Barrett JC, McLachlan JA. Molecular genetic analysis of clear cell adenocarcinomas of the vagina and cervix associated and unassociated with diethylstilbestrol exposure in utero. *Cancer: Interdisciplinary International Journal of the American Cancer Society*. 1996 Feb 1;77(3):507-13.
- « [nejm197104222841604.pdf](#) ».
- Huo D, Anderson D, Herbst AL. Follow-up of patients with clear-cell adenocarcinoma of the vagina and cervix. *The New England journal of medicine*. 2018 May 3;378(18):1746.
- Longo LD, Herbst AL, Ulfelder H, et DC. Poskanzer, « classic pages in obstetrics and gynecology », p. 2.
- Pang L, Li L, Zhu L, Lang J, Bi Y. Malignant transformation of vaginal adenosis to clear cell carcinoma without prenatal diethylstilbestrol exposure: a case report and literature review. *BMC cancer*. 2019 Dec;19(1):1-8.
- Talia KL, Wong RW, McCluggage WG. Expression of Markers of Müllerian Clear Cell Carcinoma in Primary Cervical and Vaginal Gastric-type Adenocarcinomas. *International Journal of Gynecological Pathology*. 2019 May 1;38(3):276-82.
- Mufti ST, Ali HH. Non-diethylstilbestrol-associated primary clear cell carcinoma of the vagina: two case reports with immunohistochemical studies and literature review. *Iranian journal of medical sciences*. 2014 May;39(3):298.
- Fu Z, Chen X, Yang X, Li Q. Diagnosis of primary clear cell carcinoma of the vagina by 18F-FDG PET/CT. *Clinical nuclear medicine*. 2019 Apr 1;44(4):332-3.
- Gardner CS, Sunil J, Klopp AH, Devine CE, Sagebiel T, Viswanathan C, Bhosale PR. Primary vaginal cancer: role of MRI in diagnosis, staging and treatment. *The British journal of radiology*. 2015 Aug;88(1052):20150033.
- Bacalbasa N, Balescu I, Vilcu M, Dima S, Brezean I. Anterior Pelvic Exenteration for Chemo-irradiated Non-diethylstilbestrol Exposed Clear Cell Vaginal Cancer. *in vivo*. 2019 Nov 1;33(6):2299-302.
- Offman SL, Longacre TA. Clear cell carcinoma of the female genital tract (not everything is as clear as it seems). *Advances in anatomic pathology*. 2012 Sep 1;19(5):296-312.
- Tabata T, Takeshima N, Nishida H, Hirai Y, Hasumi K. Treatment failure in vaginal cancer. *Gynecologic oncology*. 2002 Feb 1;84(2):309-14.
- Huo D, Anderson D, Herbst AL. Follow-up of patients with clear-cell adenocarcinoma of the vagina and cervix. *The New England journal of medicine*. 2018 May 3;378(18):1746.