

## Reversible Myocardial Injury Associated with Aluminum Phosphide Poisoning: Case Report

Kenza Zniber<sup>1\*</sup>, Abdoulaye Diatta<sup>1</sup>, Dania Srifi<sup>1</sup>, Yasmina Benchekroun<sup>1</sup>, Sofia Kaddaf<sup>1</sup>, Khalid Abidi<sup>1</sup> and Amine Ali Zeggwagh<sup>1</sup>

<sup>1</sup>Service d'Urgences et de Réanimation Médicale, Hôpital Avicenne, CHU Ibn Sina, Rabat, Morocco

DOI: [10.36347/sjmcr.2021.v09i05.002](https://doi.org/10.36347/sjmcr.2021.v09i05.002)

| Received: 22.03.2021 | Accepted: 30.04.2021 | Published: 05.05.2021

\*Corresponding author: Kenza Zniber

### Abstract

### Case Report

**Background:** Aluminum phosphide is a poison, used as a fumigant to protect stored grain from pests and rodents. It is marketed in Morocco as 3 g tablets under PHOSTOXIN® brand names. Once ingested, it is acutely toxic with a high mortality. When aluminum phosphide comes in contact with water, it releases large quantities of phosphine (PH<sub>3</sub>), a very toxic gas and a mitochondrial poison and causes cardiac damage hemodynamic disorders. We report a case of aluminum phosphide associated with reversible myocardial injury. **Cases Reports:** A 16-year-old woman admitted to hospital following ingestion of aluminum phosphide with the aim of a suicide. The clinical course was characterized by the development of a shock syndrome requiring the use of vasoactive amines drugs and liver dysfunction. The electrocardiogram showed a diffuse ST-depression and repolarization anomaly. The plasma concentrations of cardiac enzymes were elevated and Tran's thoracic ultrasound showed a global hypokinesia and a severe left ventricular dysfunction. After 9 days of intensive care, the heart function was restored as well as its hemodynamic state and liver function. **Conclusion:** The severity of the poisoning is judged by the cardiac failure and the unavailability of an antidote. Myocardial injury following AIP is responsible for significant mortality. Reversible myocardial injury following aluminum phosphide poisoning can be seen in some rare cases.

**Keywords:** Aluminum phosphide poisoning; Cardiotoxicity; Cardiogenic shock.

**Copyright © 2021 The Author(s):** This is an open-access article distributed under the terms of the Creative Commons Attribution 4.0 International License (CC BY-NC 4.0) which permits unrestricted use, distribution, and reproduction in any medium for non-commercial use provided the original author and source are credited.

## INTRODUCTION

Aluminum phosphide (AIP), one of the most used pesticides worldwide, has been the leading cause of self-poisoning mortalities in Morocco. It is a lethal solid pesticide, frequently used to protect stored food products and during food transformation processes. AIP is available as 3 g tablets; each consists of 56% AIP (total 1680 mg) and 44% ammonium carbonate. Following ingestion, AIP reacts with water and hydrochloric acid in the stomach, liberating phosphine (PH<sub>3</sub>) gas. Phosphine gas is colorless, flammable, and highly toxic, with an odor of garlic or decaying fish. Phosphine is a mitochondrial poison and interferes in enzyme and protein synthesis [1, 2] via mechanisms that are poorly understood.

The mortality rate from this poisoning is as high as 70–100%, where refractory hypotension and severe metabolic acidosis are the two most common presentations in this poisoning and refractory cardiogenic shock in the most of cases death [3-5].

Unfortunately, there is no specific antidote, and treatments are limited to measures such as fluid resuscitation and vasoactive agents [6].

Few cases of reversible cardiac injury have been described in the literature. We report a case of AIP poisoning with reversible myocardial toxicity.

## CASE REPORTS

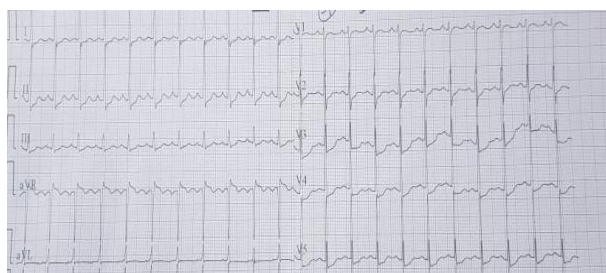
A 16-year-old young woman was referred to the emergency department 2 hours after intentionally ingested, with water, three tablets of Phostoxin®. She was healthy without any significant past medical history and did not have any cardiac problem.

At first, she complained of intense epigastric pain and dizziness. Physical examination revealed profuse sweating, a heart rate of 140 beats/minute, and blood pressure of 110/60 mmHg a saturation of peripheral oxygen (SPO<sub>2</sub>) 97%, and

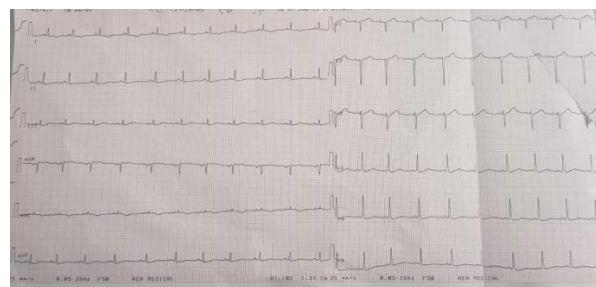
Glasgow Coma Scale (GCS) 15. Chest radiography was normal. The admission electrocardiogram (ECG) showed a sinus tachycardia 138b/min, a circumferential ST-depression and ST- elevation a AVR lead (Fig. 1). Serum concentrations of aspartate aminotransferase (AST) and alanine amino transferase (ALT) were 254 IU/L (N = 45 IU/L) and 169 IU/L (N = 50 IU/L), respectively, and prothrombin time was 59%.

The blood concentration of troponin was 47 ng/mL (N <0.016 ng/mL). Toxicological blood screening was positive for AP. Gastric lavage was performed on admission. Upon admission to the intensive care unit (ICU), few hours later, the patient became hypotensive (BP 68/39 mm/Hg) and the signs of shock appear. She was given 1 liter of crystalloid (normal saline) without improvement. A central venous pressure of 18 cmH<sub>2</sub>O was recorded Oxygen was managed. Dobutamine and noradrenaline was administrated in progressive doses (15 ug/kg/min; 2.5 ug/kg/min respectively), which stabilized the hemodynamic state; Magnesium sulfate has also been prescribed. The Echocardiogram revealed diffuse myocardial injury in both ventricles with akinesis of the inferior and septal wall and hypokinesia of the anterolateral wall and a moderate Left Ventricle enlargement with severe LV dysfunction to 28% (Fig 2) .The right ventricle was also dysfunctional and hypokinetic with TAPSE: 12mm and S'Tricuspid: 9cm/s.

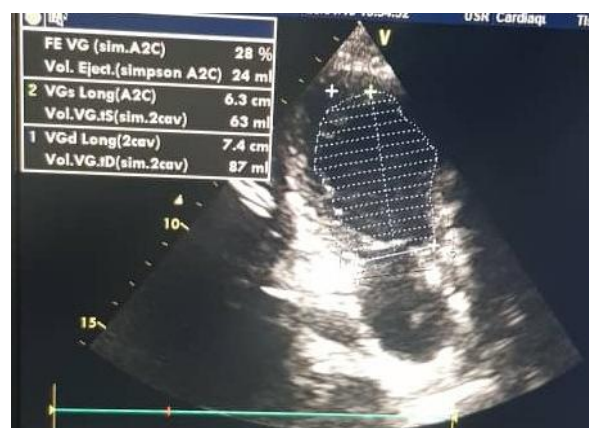Over the ensuing days there was progressive improvement in the hemodynamic state that permitted the weaning of dobutamine and noradrenaline on day 8 after admission. A simultaneous improvement was observed in electrocardiographic with a regression of ST depression (Fig 3) and normalization of biochemical values. Treatment with Ramipril, carvedilol, was started. The echocardiogram done on day 9 revealed an LV function of 59% (Fig 4) with a discrete hypokinesia of the inferior wall. Finally, on the 10th day, after psychiatric counseling, the patient was discharged from the hospital with medication orders of carvedilol and ramipril. He was suggested to be visited by a cardiologist 2 weeks after discharge.



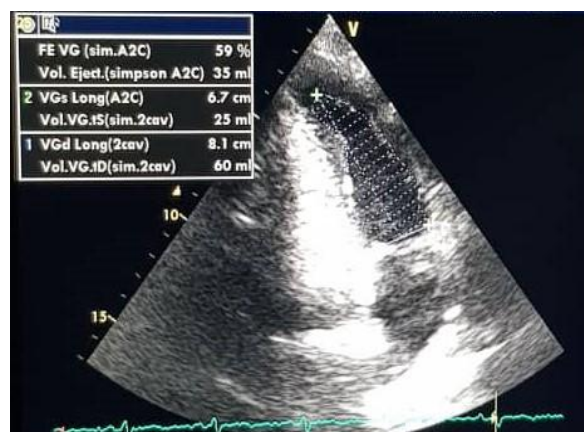
**Fig-1: Initial ECG showing sinus tachycardia and circumferential ST depression and ST elevation in AVR lead**



**Fig-2: Lastest ECG showing regression of ST depression**



**Fig-3: Initial echocardiography: 2 cavity view showing LV dysfunction 28%**



**Fig-4: Control echocardiographic after 9 days showing, in 2 cavity view, normalization of LV function**

## DISCUSSION

Aluminum phosphide poisoning is a serious and frequent scourge in developing countries [7], especially in north India where it became an epidemic state and constituting a healthcare problem and a real challenge for the medical profession [8, 9]. After having been non-existent before 1980 and then remaining accidental for a long time, ALP has now become the most common and widespread mode of self-induced poisoning in north and central India [10, 11].

The incidence in Morocco is unfortunately unknown and the first cases of ALP poisoning were reported in the end of 1980s [12]. The mean age of

the patients usually varies between 10 and 55 years, with an increasing frequency in the 20-30 years age group [10, 13].

The toxic effects of the AIP are due to deadly phosphine gas, which, when liberated, reacts with water or hydrochloric acid in the stomach. Phosphine gas (PH<sub>3</sub>) is the active pesticide component of AIP, which is rapidly absorbed by inhalation, ingestion, and skin or mucosal contact [14]. PH<sub>3</sub> works at the mitochondrial level where it can rapidly perturb mitochondrial conformation and inhibit oxidative respiration by up to 70%, severely decreasing mitochondrial membrane potential [15]. PH<sub>3</sub> mainly inhibits cytochrome C oxidase (Complex IV) and decreases Complex I and Complex II activity, resulting in decreased ATP formation [16]. This results in the slowing down of the electron flow with resultant electron leakage, initiating reactive oxygen species production (ROS).

The toxicity of AIP is systemic and can affect all organs, but particularly cardiac and vascular tissues. Cardiac toxicity is represented by a depression in myocardial cellular metabolism, as well as myocardial necrosis due to the release of reactive oxygen intermediates [12]. In fact, significant decreases in glutathione, which is a factor protecting against oxidation; concentrations were shown in different tissues during AP poisoning.

The clinical signs of poisoning are initially manifested in the gastrointestinal system including abdominal pain, nausea, and vomiting like in our case. However, after several hours, severe cardiovascular collapse, hypotension, and respiratory failure also occur and it's the most common presentation seen in 60-100% of cases [17]. Furthermore, the absence of vomiting has been found to be a severity factor in some studies [18].

Electric abnormalities are present in 38% to 91% of cases [12]. There are conduction disorders such as right and left bundle branch block (25%), atrioventricular block (8%) and rarely, sinoatrial block, arrhythmias as atrial fibrillation (4% to 61%), ventricular and atrial extrasystoles (18%) and ventricular fibrillation (2%) [2]. Finally, re-polarization disorders were also reported, such as ST segment depression (12% to 65%) like in our case, ST segment elevation (4% to 65%) and T wave inversion (36%) induced by AIP. We know that magnesium ions help in scavenging free radicals and acts as an anti-arrhythmic agent. Previous reports suggest it may be beneficial in treating AIP poisoning cases, while others found it confers no difference on survival [9, 12]. In our case the patient had received perfusion of magnesium sulfate.

Echocardiogram most of the time show a severe reduction of the systolic function with global hypokinesia [19], but in some studies like in our case,

there is a focal kinetics disorders a sign of focal myocardial necrosis. The ventricular function is correlated with hemodynamic stability and our patient showed remarkable gradual improvement in left ventricular ejection fraction by the 9th day. Gupta et al. had reported normalization of ECHO findings in AIP survivors by the 5th day [2].

At present there is no antidote for this poisoning. Some drugs are used without study support. Melatonin has been previously shown to be beneficial in reversing toxic changes in the heart. An experimental study on rats revealed that melatonin may have a protective effect on ALP-induced [20].

## CONCLUSION

Aluminum phosphide poisoning can result in severe cardiac toxicity and responsible for significant mortality. At present, no specific antidote for this poisoning is known, and treatment strategy is supportive until the injury induced by the active compound (phosphine) subsides.

Despite all intensive medical care efforts in supportive therapy, the prognosis is poor but in some lucky cases like our, the cardiac function is restored integrally. Finally, the free sale of this poison should be prohibited in the light of the damage it causes.

## REFERENCES

- Burgess JL, Morrissey B, Keifer MC, Robertson WO. Fumigant-related illnesses: Washington State's fiveyear experience. *J Toxicol Clin Toxicol*. 2000; 38: 7–14.
- Gupta S, Ahlawat, SK. Aluminum phosphide poisoning – a review. *J Toxicol Clin Toxicol*. 1995; 33: 19–24.
- Farzaneh E, Ghobadi H, Akbarifard M, Nakhaee S, Amirabadizadeh A, Akhavanakbari G, Keyler DE, Mehrpour O. Prognostic Factors in Acute Aluminium Phosphide Poisoning: A Risk-Prediction Nomogram Approach. *Basic & clinical pharmacology & toxicology*. 2018 Sep;123(3):347-55.
- Mehrpour O, Gurjar M. Cardiogenic shock: the main cause of mortality in acute aluminum phosphide poisoning. *Indian Journal of Critical Care Medicine*. 2017 Apr 1;21(4):246-7.
- Siddaiah LM, Adhyapak SM, Jaydev SM, Shetty GG, Varghese K, Patil CB, Iyengar SS. Intra-aortic balloon pump in toxic myocarditis due to aluminum phosphide poisoning. *Journal of medical toxicology*. 2009 Jun 1;5(2):80-3.
- Pajoumand A, Jalali N, Abdollah M, Shadnia S. Survival following severe aluminium phosphide poisoning. *Journal of Pharmacy Practice and Research*. 2002 Dec;32(4):297-9.
- Bouzoubaa A, Benkiran A, Chraïbi N, EL MAKHLOUF A. Traitement de l'intoxication par

- ingestion de phosphore d'aluminium: approche expérimentale. *Journal de toxicologie clinique et expérimentale*. 1988;8(3):193-9.
8. Banjaj R, Wassir HS. Epidemic aluminum phosphide poisoning in northern India. *Lancet*. 1988; 1:820-1.
  9. Siwach SB, Dua A, Sharma R, Sharma D, Mehla RK. Tissue magnesium content and histopathological changes in non-survivors of aluminum phosphide poisoning. *J Assoc Physicians India*. 1995; 43:676-8.
  10. Arora B, Punia RS, Karla R, Chugh SN, Arora DR. Histopathological changes in aluminum phosphide poisoning. *J Indian Med Assoc*. 1995; 93:380-1.
  11. Singh D, Dewan I, Pandey AN, Tiagy S. Spectrum of unnatural fatalities in the Chandigarh zone of northwest India. A 25-year autopsy study from a tertiary care hospital. *J Clin Forensic Med*. 2003; 10:145-52.
  12. Chugh SN, Kolley T, Kakkar R, Chugh K, Sharma A. A critical evaluation of anti-peroxidant effect of intravenous magnesium in acute aluminum phosphide poisoning. *Magnes Res*. 1997; 10:225-30.
  13. Moghadamnia AA, Abdollahi M. An epidemiological study of poisoning in northern Islamic of Iran. *East Mediter Health J*. 2002; 8:88-94.
  14. Sudakin DL. Occupational exposure to aluminium phosphide and phosphine gas? A suspected case report and review of the literature. *Hum Exp Toxicol*. 2005;24(1):27-33.
  15. Valmas N, Zuryin S, Ebert PR. Mitochondrial uncouplers act synergistically with the fumigant phosphine to disrupt mitochondrial membrane potential and cause cell death. *Toxicology*. 2008;252(1-3):33-9.
  16. Dua R, Gill KD. Effect of aluminum phosphide exposure on kinetic properties of cytochrome oxidase and mitochondrial energy metabolism in rat brain. *Biochim Biophys Acta*. 2004;1674(1):4-11.
  17. Tripathi SK, Gautam CS, Sharma PL. Clinical pharmacology of aluminum phosphide poisoning. *Ind J Pharmacol*. 1992; 24:134-7.
  18. Hajouji Idrissi M, Oualili L, Abidi K, Abouqal R, Kerkeb O, Zeggwagh AA. Severity factors of aluminum phosphide poisoning (phostoxin). *Ann Fr Anesth Reanim*. 2006; 25:382-385
  19. Bhasin P, Mital HS, Mitra A. An echocardiographic study in aluminium phosphide poisoning (Abstract). *J Assoc Physicians India*. 1991; 39:851.
  20. Asghari, Mohammad Hossein; Moloudizargari, Milad; Baeeri, Maryam; Baghaei, Amir; Rahimifard, Mahban. *Archives of Toxicology. Archiv für Toxikologie; Heidelberg*. 2017; 91(9); 3109-3120