

## Angioneurotic Edema: About A Case

Ihssane Allouch<sup>1\*</sup>, Ikrame Boumendil<sup>1</sup>, Hanaa Rahim<sup>1</sup>, Sophia Nitassi<sup>1</sup>, Razika Bencheikh<sup>1</sup>, Mohamed Anas Benbouzid<sup>1</sup>, Abdelilah Oujilal<sup>1</sup>, Leila Essakalli<sup>1</sup>

<sup>1</sup>ENT Department, Specialties Hospital, Mohammed V University, Rabat, Morocco

DOI: [10.36347/sjmcr.2021.v09i05.005](https://doi.org/10.36347/sjmcr.2021.v09i05.005)

| Received: 17.03.2021 | Accepted: 26.04.2021 | Published: 07.05.2021

\*Corresponding author: Ihssane Allouch

### Abstract

### Case Report

Angioneurotic edema is most often hereditary and due to a deficiency of C1 inhibitor (C1 INH). It manifests by recurrent episodes of subcutaneous and / or submucosal edema, non inflammatory and non pruritic, of the face and extremities or by pseudo-occlusive, spontaneously reversible abdominal seizures. We report the case of a 19-year-old patient who presented a tongue edema which resolved spontaneously, he has in his history, several episodes of reversible face edema, the Exploration of the classical complement pathway during this episode shows a normal C3 and a lower C4.

**Keywords:** Angioneurotic edema, C1 inhibitor, Danazol.

Copyright © 2021 The Author(s): This is an open-access article distributed under the terms of the Creative Commons Attribution 4.0 International License (CC BY-NC 4.0) which permits unrestricted use, distribution, and reproduction in any medium for non-commercial use provided the original author and source are credited.

## INTRODUCTION

Angioneurotic edema is most often hereditary and is due to a deficiency of C1 inhibitor (C1 INH). It manifests by recurrent episodes of subcutaneous and / or submucosal edema, non inflammatory and non pruritic, of the face and extremities or by pseudo-occlusive, spontaneously reversible abdominal seizures. Angioneurotic-edema can occur as a result of tissue microtrauma or emotional stress; but puberty, infections, menstruation, pregnancy, postpartum and oral contraception can also be triggering factors [1]. We report a case of angioneurotic edema of the tongue and face.

## CASE REPORT

This is a 19-year-old patient who presented to the emergency for a tongue edema (Figure-1) which resolved spontaneously, he has in his history, several episodes of reversible face edema (Figure-2), it started 2 years, without associated signs and no similar case in the family. No drug intake or signs of atopy have been reported.

The diagnostic of angioneurotic edema was suggested. The Exploration of the classical complement pathway during this episode results in a normal C3 and a lowered C4.

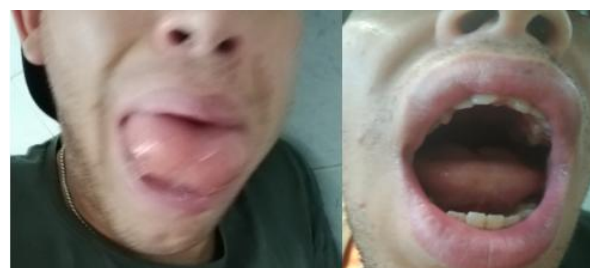


Fig-1: Edema of the tongue spontaneously reversible after two hours

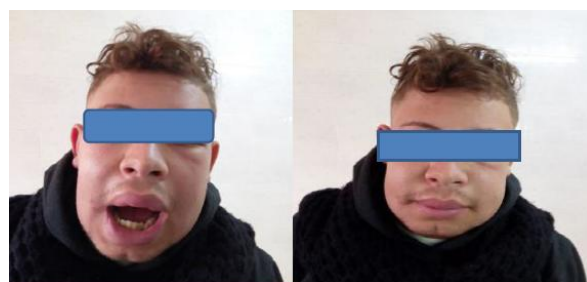

Fig-2: Facial edema in the same patient

## DISCUSSION

Angioneurotic-edema constitutes a clinical-biological entity with a relatively homogeneous clinical and biological expression, characterized by a quantitative or functional deficit of the activity of the C1 esterase inhibitor (C1-INH) due to various causes [2].

There are hereditary forms marked, either by a quantitative deficit in C1-INH, or by a functional abnormality of the protein. The acquired forms are rare, they are often associated with lympho-proliferative syndromes or autoimmune pathologies (in particular rheumatoid arthritis [3], Crohn's disease [4] or systemic lupus erythematosus [5]).

Regardless of the type, the clinical expression is the same; the disease progresses in flare-ups lasting 2 to 8 days, accompanied by segmental edema mainly subcutaneous, especially localized to the extremities and face [2]. The association with abdominal pain is very suggestive, and laryngeal edema makes the disease serious and life-threatening. The diagnosis is provided by the study of complement proteins during the outbreaks which shows in all cases a lowering of the C2 and C4 fractions while C3 is normal. The functional dosage of C1-INH is always lowered, but its antigenic activity is sometimes retained. Treatment of acute manifestations is generally based on infusions of purified C1-INH [1].

In the long term, anabolic steroids (danazol) increase hepatic synthesis of C1-INH ; antifibrinolytics are less effective. In acquired forms, treatment of the causative disease most often eliminates the clinical manifestations of angioneurotic-edema [1].

## CONCLUSION

Angioneurotic-edema for C1-INH deficiency requires early diagnosis, as it is a serious condition for

which effective preventive and curative treatment is currently available. The diversity of clinical shapes, genetic or acquired, explains the difficulties of diagnosis and the delay sometimes taken in establishing it.

## REFERENCE

1. Dumestre-Perard C, Bouillet L. Acquisitions récentes concernant une maladie peu fréquente : l'OAH associé à un déficit en C1 inhibiteur. *Lyon Pharm.* 2000;51:14-30.
2. Claveyrolas-Bouillet L, Ponard D, Jacquot C, Colomb M. L'œdème angioneurotique héréditaire et acquis: à propos d'une série de 26 patients. *La Revue de médecine interne.* 1998(19):378.
3. Garcia-Hejl C, Harnois F, El Jahiri Y, Bigaillon C, Mennecier D, Ceppa F, Thiolet C, Fabre R. Un cas d'œdème angioneurotique acquis. In *Annales de Biologie Clinique* 2006 Mar 1 (Vol. 64, No. 2, pp. 166-169).
4. Duncan IJ, Tymms KE, Carney G. Rheumatoid arthritis and hereditary angioedema. *J Rheumatol.* 1988;15:700-2.
5. Farkas H, Gyeny L, Nemesanszky E, Kaldi G, Kukan F, Masszi I, Soos J, Bely M, Farkas E, Füst G, Varga L. Coincidence of hereditary angioedema (HAE) with Crohn's disease. *Immunological investigations.* 1999 Jan 1;28(1):43-53.
6. Haddad M, Ghrairi N, Kallel M, Tritar F, Yalaoui S. (Edème angioneurotique héréditaire: à propos de deux cas. *Immuno-analyse & Biologie Spécialisée.* 2012 Apr 1;27(2):66-8.