

## Submandibular Desmoid Tumor in Children: A Case Report

H.Kabbaj<sup>\*1</sup>, Z.Aziz<sup>2</sup>, F.Fettal<sup>3</sup>, M. Elbouihi<sup>4</sup>, N. Mansouri- Hattab<sup>5</sup>

<sup>1-5</sup>Maxillofacial, Aesthetic and Stomatology Surgery Department, Ibn Tofail hospital, UHC Moammed VI, Marrakech, Morocco

DOI: [10.36347/sjmcr.2021.v09i05.007](https://doi.org/10.36347/sjmcr.2021.v09i05.007)

| Received: 25.03.2021 | Accepted: 01.05.2021 | Published: 08.05.2021

\*Corresponding author: H.Kabbaj

### Abstract

### Case Report

Desmoid tumors also called fibromatosis of the face are very rare especially in children. These tumors although benign are known to be recurrent and very aggressive locally so they can be confused with malignant tumors. Several treatments can be offered, but only surgery with a complete excision remains the guarantee of a complete remission. **Case report:** We present a case of mandibular desmoid tumor in a 2-year-old girl who presented with left mandibular mass rapidly increasing in volume. After the biopsy has confirmed the nature of the tumor, surgical treatment has been proposed thus proceeding with the complete excision of the tumor. The postoperative follow-up was simple. No recurrence was recorded 2 years after the operation. **Conclusion:** The treatment of a desmoid facial tumor in children is difficult, all the more so as the tumor is large or locally aggressive. Wide excision is the only guarantee of a good evolution even if it can compromise the growth potential.

**Keywords:** Desmoid Tumor, Mandibular Tumor, Pediatrics.

Copyright © 2021 The Author(s): This is an open-access article distributed under the terms of the Creative Commons Attribution 4.0 International License (CC BY-NC 4.0) which permits unrestricted use, distribution, and reproduction in any medium for non-commercial use provided the original author and source are credited.

## INTRODUCTION

Desmoid tumors also known as fibromatosis are rare benign fibroblastic tumors representing less than 1% of mandibular tumors [1]. They are characterized by rapid development, locoregional aggressiveness and a high potential for recurrence [2]. Their main differential diagnosis is low grade fibrosarcoma.

Desmoid tumors can occur at any age. Usually there are two incidence peaks: ages 6 to 15 years and puberty to age 40 years. Most of the tumors occur sporadically, and the rest can be associated with hereditary cancer syndromes [3].

Treatment is mainly based on surgery. Chemotherapy and radiotherapy can be discussed especially in very large tumors [3]. Indications depend on symptomatic disease, imminent risk to adjacent structures, and cosmetic concerns [4]. We report a case of a mandibular desmoid tumor diagnosed and treated in our department.

## CASE REPORT

A 2-year-old girl with no significant pathological history, presented with a left sub-angulo-mandibular mass extended to the upper cervical region and to the floor of the mouth evolving for 6 months and rapidly increasing in volume. On examination, she

presented hard painful swelling, fixed to the deep structures, without signs of compression, in particular no dyspnea or dysphagia.

The facial contrast-enhanced computed tomography (CT) revealed a left sub-angulo-mandibular mass of tissue without bone invasion with the presence of cervical lymphadenopathy requiring complement by magnetic resonance imaging (MRI). Facial MRI confirmed the presence of a mass centered on the left mandibular ramus of oval shape, intensely and homogeneously enhanced by the contrast product, partially infiltrating the hypoglossal and medial pterygoid muscles. It compresses the submandibular gland and the ipsilateral external carotid artery. Without bone invasion (Fig-1).

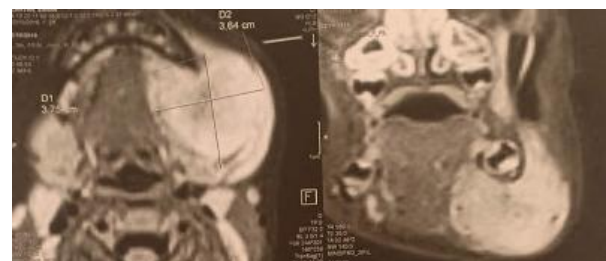
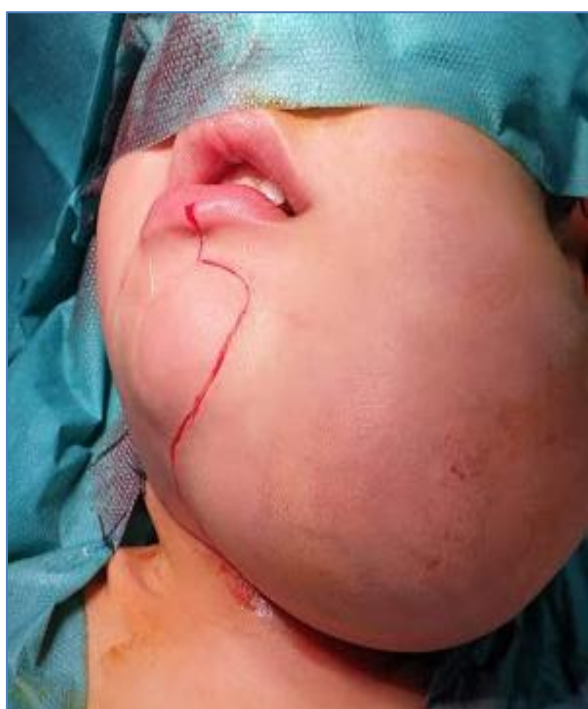

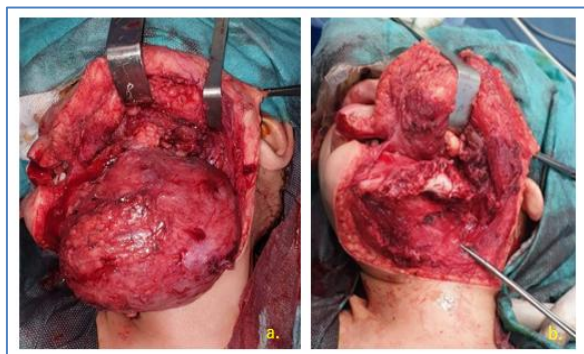Fig-1: MRI in patient before surgery (axial (a.) and coronal (b.) sections)

The lesion was biopsied. The histopathological study showed a benign conjunctivascular tumor proliferation within a more or less cellular fibrous material, fibroblastic and myofibroblastic. The immunohistochemical study showed positive anti-Beta-Catenin, anti-Ki-67 antigen and anti-Actin Muscle Specific (AML) staining in favor of desmoid fibromatosis.

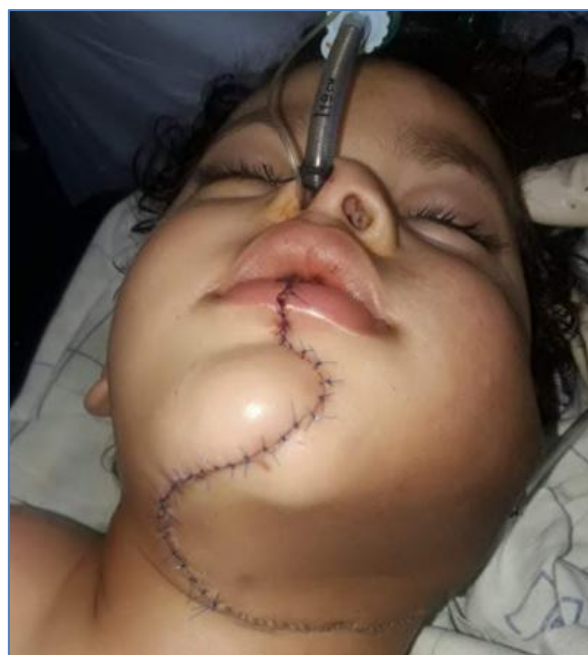On the basis of radiological et histopathological findings, wide surgical excision of the mass was performed. We opted for a transfacial approach continuing with a high cervicotomy incision for better exposure of the structures (Fig.2). Surgical exploration objectified an encapsulated and individualizable and cleavable oval tissue mass, pushing back neighboring tructures (Fig. 3, 4).



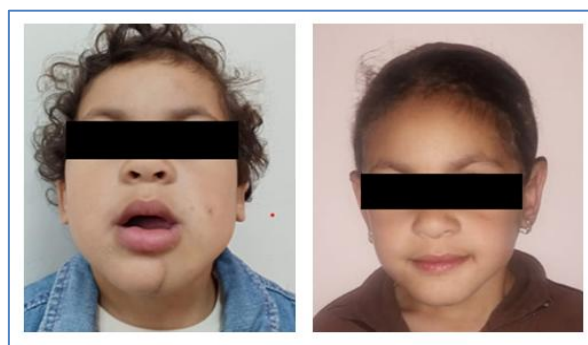**Fig-2:** Operative basale view of the tracing of the transfacial ET high cervicotomy incision.



**Fig-3:** Operative basale view highlighting the tumor before resection (a). View after resection (B)



**Fig-4:** Immediate post-operative result (basale view).



**Fig-6:** Post-operative result at 4 months (left image) and at 2 years (right image).

The postoperative follow-up was simple without any notable incident. The aesthetic result was considered acceptable by our team as well as the patient's family. After 2 years of follow-up, we did not collect any signs of clinical or radiological recurrence. The scar is invisible (Fig-5).

## DISCUSSION

Desmoid tumors or fibromatosis, are very rare benign tumors which develop at the expense of musculoaponeurotic structures [5]. The World Health Organization defines desmoid tumors as "clonal fibroblastic proliferation occurring in deep soft tissues and which is characterized by invasive development and a tendency to local recurrence, but does not result in metastasis" although it can be multifocal in the same bodily territory [6].

Fibromatosis is a rare entity representing only 0.03% of all neoplasms and 3.5% of fibrous tumors with an incidence of two to four new cases per 100,000 inhabitants. There is a female predominance with a sex

ratio of 2/1 [7]. This tumor affects children in only 5% of cases and represents 2.28% of benign tumors at this time of life [8].

In infants fibromatosis presents between birth and 8 years of age, most commonly in the first 2 years of life. It often involves the muscles of the head and neck, shoulder, and upper arm. The most frequent sites in the head and neck are the tongue, mandible, maxilla, and mastoid [9].

The natural history of fibromatosis is slow, progressive growth with invasion of adjacent tissues [9]. The dense anatomy of the head and neck region and close anatomical relations neurovascular and other vital structures may be associated with functional sequelae or even mortality. Fibromatosis has no malignant or metastatic potential [10].

Radiologically, fibromatosis appear in variable way according to the degree of cellularity, myxoid change, and collagenization [11]. CT scan can reveal variable attenuations on pre and postcontrast images. Lesions with more collagenous deposits may reveal higher attenuation. On MRI, lesions often show high signal intensity on T2-weighted image and iso signal intensity on T1-weighted image and avid enhancement [12]. MRI is the radiological examination of choice in the diagnosis of desmoid tumors.

Differential diagnosis of fibromatosis in head and neck region includes malignant tumors such as malignant fibrous histiocytoma, fibrosarcoma, rhabdomyosarcoma, and metastases, because of the aggressive feature, and also solitary fibrous tumor [12].

The diagnosis is confirmed by histology. The histologic appearance of fibromatosis is one in which collections of uniform-appearing, spindle-shaped cells are grouped in poorly defined fascicles and separated by collagen strands. Remnants of striated muscle are often found interlaced within bundles of fibroblasts near the periphery of the tumor, indicative of its propensity for local invasion. The tumor does not form a pseudocapsule or infiltrate the skin. Characteristically, there is no nuclear hyperchromasia or cellular atypia, but the degree of cellularity may vary from region to region. Mitotic figures are rare. Of paramount importance is the pathologic distinction between fibromatosis and fibrosarcoma [9]. The histopathological study is often supplemented by immunohistochemistry.

Infantile fibromatosis is classified into 3 distinct histologic types—diffuse, fibroblastic, and desmoid, which reflect the stages of fibroblast proliferation [9].

Several radiological and clinical studies have suggested that desmoid tumors are more aggressive in

children, with a more invasive appearance, more rapid growth, a higher recurrence rate, and less favourable response to radiotherapy [5].

The management of desmoid tumors is complex, particularly in pediatric surgery where the impact on growth is a very important factor to be taken into consideration before any therapeutic choice.

Furthermore, the dense anatomy of the head and neck and the close anatomical relations with neurovascular and other vital structures, associated with the invasiveness of the tumor may cause difficulties for complete surgical resection which can be associated with an excessive risk of mortality or functional sequelae [5]. Wide surgical excision remains the best treatment to fibromatosis. But in cases when surgery can't remove all the tumor tissue, it can be followed by postoperative radiotherapy, despite the benign nature of this tumor [5].

Radiotherapy can be used alone or in addition to surgical treatment. In adults it can be beneficial but in children it is not discussed in the same way [7]. The role of radiotherapy in managing young patients with desmoid tumors remains unclear. Younger patient age is associated with inferior local-regional control following radiotherapy. In children and young adults, doses  $\geq 55\text{Gy}$  were associated with improved tumor control, but also lead to increased risk complications (post-radiation facial growth retardation, hypoplasia of the mandible and the bones of the facial massif, panhypopituitarism, scoliosis, hypothyroidism, neuropathic ulcers, osteomyelitis, dermatitis with chronic ulcers which can lead to death) [8], [13]. Under these conditions, the use of radiotherapy in children should be avoided especially as the benefit risk ratio is unfavorable. Chemotherapy can be considered for unresectable tumors, or for patients who are unable to support the morbidity of surgery and radiotherapy [14].

Different drug treatments, cytotoxic and not cytotoxic agents, have been proposed in the treatment of desmoid tumors. Non-cytotoxic agents include treatments hormones, nonsteroidal anti-inflammatory drugs, interferon alpha, imatinib. Hormonal treatments are mainly represented by anti-estrogens such as tamoxifen, and more recently toremifene which seems to be promising since it provides a partial response in 25% of cases, tumor stability in 65% of cases and relief of symptoms in 75% of cases, even after failure of other hormonal treatments [15]. Imatinib is a receptor inhibitor tyrosine kinase which has shown efficacy in desmoid tumors [16]. Non-steroidal anti-inflammatory drugs (NSAID) have also been used in the treatment of fibromatosis. Meloxicam, a COX-2 inhibitor, has been shown to be effective in controlling neck and other extra-abdominal desmoid tumors [5,17].

In adults, a simple wait-and-see approach has been proposed for tumors not associated with any functional sequelae or with no significant risk of mortality. Number of studies showed a spontaneous regression [5]. However, this attitude can't be adopted in the pediatric population. In children, head and neck desmoid tumors are known to be more aggressive with a faster evolution and a greater impact, especially as the tumor is invasive.

## CONCLUSION

Head and neck desmoid tumors appear to be more aggressive in children. They must be diagnosed and treated quickly to avoid the morpho-functional sequelae linked to the local invasion of the tumor and the repercussions on growth. Surgery with large tumor resection guarantees good progress with a lower risk of recurrence.

## Disclosure of Interest

The authors declare that they have no competing interest.

## REFERENCES

- Jebblaoui, Y., Bouguila, J., Haddad, S., Helali, M., Zairi, I., Zitouni, K., ... & Adouani, A. (2007). Fibromatose agressive mandibulaire. *Revue de Stomatologie et de Chirurgie Maxillo-faciale*, 108(2), 153-155.
- Avinçsal, Ö. M., Shinomiya, H., Otsuki, N., Sasaki, R., & Nibu, K. I. (2018). Successful management of aggressive fibromatosis of the neck: a case report. *Balkan medical journal*, 35(3), 278.
- Zemer, V. S., Toledano, H., Kornreich, L., Freud, E., Atar, E., Avigad, S., ... & Ash, S. (2017). Sporadic desmoid tumors in the pediatric population: A single center experience and review of the literature. *Journal of pediatric surgery*, 52(10), 1637-1641.
- Gronchi, A., Colombo, C., Le Pécoux, C., Dei Tos, A. P., Le Cesne, A., Marrari, A., ... & Bonvalot, S. (2014). Sporadic desmoid-type fibromatosis: a stepwise approach to a non-metastasising neoplasm—a position paper from the Italian and the French Sarcoma Group. *Annals of oncology*, 25(3), 578-583.
- Risoud, M., Mortuaire, G., Leroy, X., Leblond, P., & Fayoux, P. (2017). Desmoid tumours of the head and neck in children: review of management. *European annals of otorhinolaryngology, head and neck diseases*, 134(3), 155-160.
- Jo, V. Y., & Fletcher, C. D. (2014). WHO classification of soft tissue tumours: an update based on the 2013 (4th) edition. *Pathology*, 46(2), 95-104.
- E. Masson, « La fibromatose agressive faciale chez l'enfant : une localisation fréquente d'une tumeur exceptionnelle ! », *EM-Consulte*. <https://www.em-consulte.com/article/730654/figures/la-fibromatose-agressive-faciale-chez-lenfant-une-consulte-le-avr-29-2021>.
- Risoud, M., Mortuaire, G., Leroy, X., Leblond, P., & Fayoux, P. (2017). Tumeurs desmoïdes cervico-faciales de l'enfant: mise au point sur la prise en charge. *Annales françaises d'Oto-rhinolaryngologie et de Pathologie Cervico-faciale*, 134(3), 150-155.
- Siegel, N. S., & Bradford, C. R. (2000). Fibromatosis of the head and neck: a challenging lesion. *Otolaryngology—Head and Neck Surgery*, 123(3), 269-275.
- Bouatay, R., Jabnoun, R., Kolsi, N., & Koubaa, J. (2019). Desmoid tumours of the head and neck: A case report. *European annals of otorhinolaryngology, head and neck diseases*, 136(3), 207-209.
- Liu, Q. Y., Chen, J. Y., Liang, B. L., Li, H. G., Gao, M., & Lin, X. F. (2008). Imaging manifestations and pathologic features of soft tissue desmoid-type fibromatosis. *Ai zheng=Aizheng= Chinese journal of cancer*, 27(12), 1287-1292.
- hyo Rhim, J., Kim, J. H., Moon, K. C., Park, S. W., Sohn, C. H., Choi, S. H., ... & Chang, K. H. (2013). Desmoid-type fibromatosis in the head and neck: CT and MR imaging characteristics. *Neuroradiology*, 55(3), 351-359.
- Rutenberg, M. S., Indelicato, D. J., Knapik, J. A., Lagmay, J. P., Morris, C., Zlotecki, R. A., ... & Marcus, R. B. (2011). External- beam radiotherapy for pediatric and young adult desmoid tumors. *Pediatric blood & cancer*, 57(3), 435-442.
- Constantinidou, A., Jones, R. L., Scurr, M., Al-Muderis, O., & Judson, I. (2011). Advanced aggressive fibromatosis: effective palliation with chemotherapy. *Acta Oncologica*, 50(3), 455-461.
- Fiore, M., Colombo, C., Radaelli, S., Callegaro, D., Palassini, E., Barisella, M., ... & Gronchi, A. (2015). Hormonal manipulation with toremifene in sporadic desmoid-type fibromatosis. *European Journal of Cancer*, 51(18), 2800-2807.
- Penel, N., Le Cesne, A., Bui, B. N., Perol, D., Brain, E. G., Ray-Coquard, I., ... & Blay, J. Y. (2011). Imatinib for progressive and recurrent aggressive fibromatosis (desmoid tumors): an FNCLCC/French Sarcoma Group phase II trial with a long-term follow-up. *Annals of Oncology*, 22(2), 452-457.
- De Bree, E., Zoras, O., Hunt, J. L., Takes, R. P., Suárez, C., Mendenhall, W. M., ... & De Bree, R. (2014). Desmoid tumors of the head and neck: a therapeutic challenge. *Head & neck*, 36(10), 1517-1526.