

## Three for One – Successful Emergency Management in Rare Case of ACC Dissection during Catheterization for Clot Retrieval of Left Sided M1-Segment via Vessel Exploration, Endovascular Thrombectomy and Retrograde Stenting

Sheila Fatehpur<sup>1</sup>, Masoud Mirzaie<sup>2\*</sup>, Christoph Redecker<sup>3</sup>, Josefina Kusnirova<sup>1</sup>, Johann Philipp Addicks<sup>4</sup>

<sup>1</sup>Department of Vascular Surgery, OWL, University clinics, Campus Lemgo, Germany

<sup>2</sup>Professor & Head of the Department of Vascular Surgery, OWL, University Clinics, Campus Lemgo, Germany, Rintelner Straße 85, 32657 Lemgo, Germany

<sup>3</sup>Department of Neurology, OWL, University Clinics, Campus Lemgo, Germany

<sup>4</sup>Institut of Neuroradiology, OWL, University Clinics, Campus Lemgo, Germany

DOI: [10.36347/sjmc.2021.v09i05.012](https://doi.org/10.36347/sjmc.2021.v09i05.012)

| Received: 26.03.2021 | Accepted: 04.05.2021 | Published: 11.05.2021

\*Corresponding author: Masoud Mirzaie

### Abstract

### Case Report

We present our experience with the surgical exploration of ACC bifurcation as a rescue maneuver to manage acute M1-occlusion after ipsilateral iatrogenic dissection (ID) of common carotid artery (ACC) by providing alternative endovascular access to perform mechanical thrombectomy (MT) in left middle cerebral artery (MCA) and retrograde Stenting of ACC dissection. This results in successful recanalization of both the MCA and ACC with a good clinical outcome.

**Keywords:** ACC bifurcation, common carotid artery, Mechanical thrombectomy (MT).

**Copyright © 2021 The Author(s):** This is an open-access article distributed under the terms of the Creative Commons Attribution **4.0 International License (CC BY-NC 4.0)** which permits unrestricted use, distribution, and reproduction in any medium for non-commercial use provided the original author and source are credited.

## INTRODUCTION

After publication of the 5 HERMES (Highly Effective Reperfusion Evaluated in Multiple Endovascular Stroke) studies, endovascular clot retrieval in combination with intravenous recombinant tissue plasminogen activator (rtPA), if possible, has become the therapy of choice in treatment of acute arterial ischemic stroke (AIS) in case of large vessel occlusion (LVO) of the anterior circulation, based on positive randomized controlled trials [1-5]. The time window for treatment should not be after 6 hours from symptom onset; however, newer investigations show benefits of MT up to 12-24h after onset of symptoms, after reviewing additional imaging parameters such as a CT perfusion imaging or MRI for triage of patients [6].

Like all other invasive procedures, endovascular interventions such as MT carry the risk of causing iatrogenic complications, particularly vessel wall injury as arterial dissection or perforation [7]. However, data on dissections of cervical arteries, especially of the ACC as complication of endovascular treatment of AIS is limited. Additionally, management of such rare cases is not well established; optimal treatments and strategies to get to the real target - the

occluded cerebral vessel - as well as risk factors and morphological features are scarce.

## CASE REPORT

We report on a case of a 48-year-old patient in our emergency room who presented as a wake-up stroke with global aphasia, right-sided hemiplegia, and neglect, NIHSS 10.

Following our clinic's routine for wake-up strokes, we performed a multiparametric CT with perfusion imaging and CT angiography. CT analysis showed a 13mm filling defect at the M1-segment of the left middle cerebral artery (MCA) without significant calcification, leading to the diagnosis of thrombotic cerebral large vessel occlusion (Fig. 1). Additionally, poor contrast filling of the associated M2- branches and hypoplastic vertebral artery up to the middle V2-segment was noticed. The left ACI were described a little less prominent compared to the contralateral ACI, at least in the extracranial parts.

All other large arteries of the brain and neck were identified in the angiography with no signs of occlusion or relevant stenosis.

**Citation:** Sheila Fatehpur *et al.* Three for One – Successful Emergency Management in Rare Case of ACC Dissection during Catheterization for Clot Retrieval of Left Sided M1-Segment via Vessel Exploration, Endovascular Thrombectomy and Retrograde Stenting. Sch J Med Case Rep, 2021 May 9(5): 510-514.

Non-contrast CT and perfusion CT showed not only small infarct cores in the following regions; internal capsula, M3 and M4 (ASPECT 7), but also large area of left ACM territory with reduced perfusion (tissue at risk) (Fig-1). Based on absence of contraindications the patient was treated with iv-lysis and MT. As usual, we performed a femoral puncture on the right side and installed an 8F short sheath. The selective catheterization of the left ACC was performed with a soft curved 35Terumo guide-wire and a guiding catheter Bent 2 5F. Unexpected resistance was found, while placing the 6F long sheath in the proximal ACC. That is why immediate angiogram was performed and showed total ACC occlusion that started at the proximal part of the ACC and showing a triangle-formed luminal arrest of contrast. All recanalization attempts via guide-wire were failed, so MT of M1 via the ipsilateral endovascular access route was no longer possible (Fig 2).

To evaluate the current perfusion of the territory of the left MCA and anterior cerebral artery (ACA), we performed an angiography through the contralateral ACI. Unchanged M1- occlusion as well as a stop of contrast via retrograde flow at the level of distal ACC shortly before bifurcation was presented, forming a negative “flame-shape” figure.

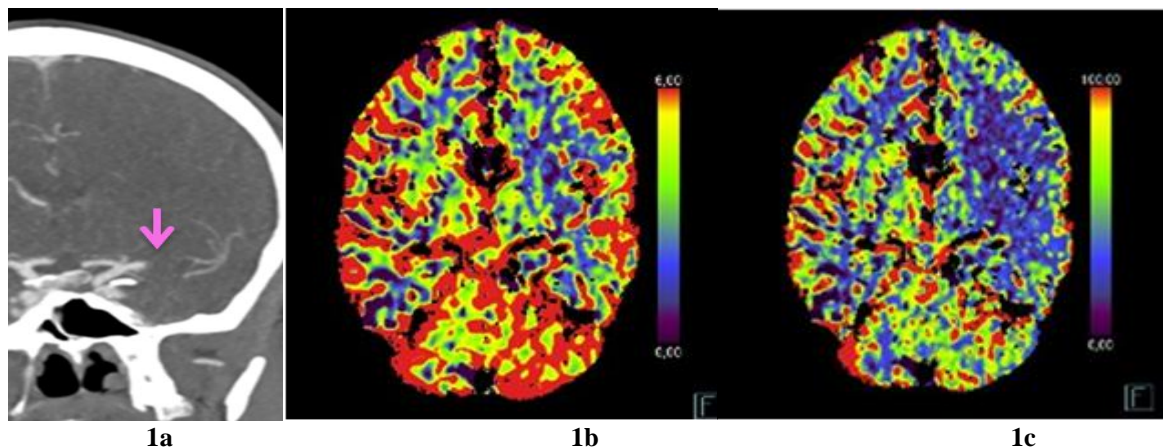
Because of ACC damaged wall extending to carotid bifurcation and the thin caliber of ACOM, were direct puncture of ACC as well as cross-excess to left MCA via right ICA and ACOM not an option.

With our vascular surgeons we decided for a surgical exploration of the left common carotid artery to get endovascular excess to left sight ACI and ACM. The patient was immediately transported to the operating theatre and we transitioned to perform an open-interventional thrombectomy. After a successful atherectomy, we inserted a short 5F sheath in the C1

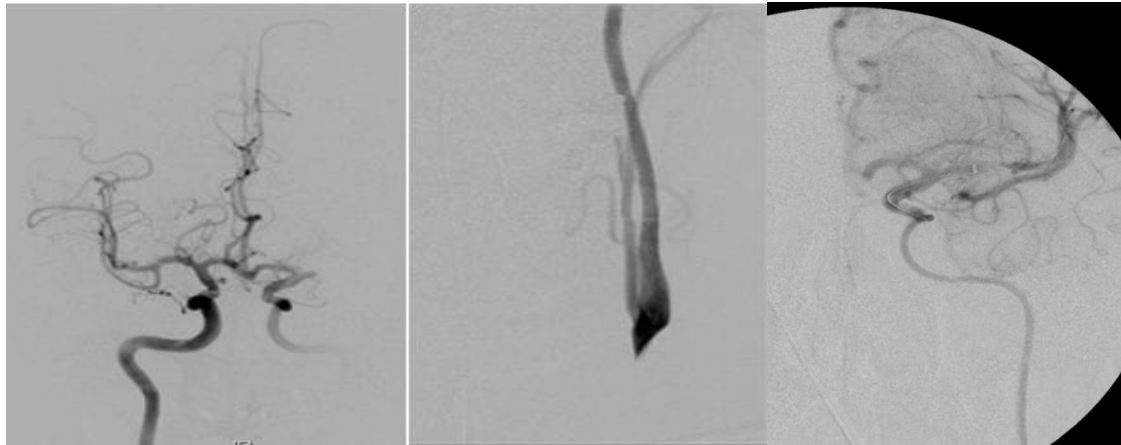
Segment of the ACI and were able to perform MT with a retriever and aspiration in save-Technic by using Solitaire 4 mm x 20mm and Sophia 5F (Fig-2). The subsequent angiographic control showed a short residual thrombus in the prebifurcational M1 segment, which has been removed completely by a second MT, thereby TIC1 3 was reached with the 2. passage. Next, we retrogradely inserted the short sheath and stented the dissection of the ACC with a Wall Stent (7mm x 40 mm), notably without post stenting dilatation to prevent any further damages of the vessel.

The following angiographic control showed discrete luminal narrowing and acceptable stenosis at the distal end of the stent, near the bifurcation (Fig-3). The vessel was then closed with a bovine pericardial patch (8 x 40 mm Lamed) by the vascular surgeons.

For acute stenting, was 500 mg Aspirin given. In the postinterventional CT-control 6 hours later, there was no intracranial bleeding. So, we started double antiaggregation of platelets with ASS 100mg/d and Clopidogrel 300 mg/d, which was then continued for 6 weeks with ASS 100mg/d and Clopidogrel 75mg/d. The post-operative MRI of the neck with angiography of the supraaortic branches 24h after onset showed a partial effacement phenomenon in the proximal section of the stented common carotid artery and hemorrhage in vessel wall. But it also showed a quite similar luminal diameter compared to the healthy, right ACC and a good patchplasty of the carotid bifurcation and a regular perfusion of all intracranial large vessels. The postoperative MRI of the neurocranium showed infarctions of the left hemisphere best seen in FLAIR- and DWI sequences, but quite comparable in size to the periinterventional CT previously (Fig. 4). In the follow up control by ultrasound, the ACC showed normal diameter, and 12 months after onset, the patient was rated with NIHSS of 0.



**Fig. 1 a-c: CT angiography (1a) and Barin CT-perfusion-angiography (1b and c): filling defect at the M1-segment of the left middle cerebral artery and Large subtotal perfusion defect in the left medial supply area with relatively small infarct nuclei in left truncal ganglia, capsula externa and M4/4 left, corresponding to a clear mismatch.**

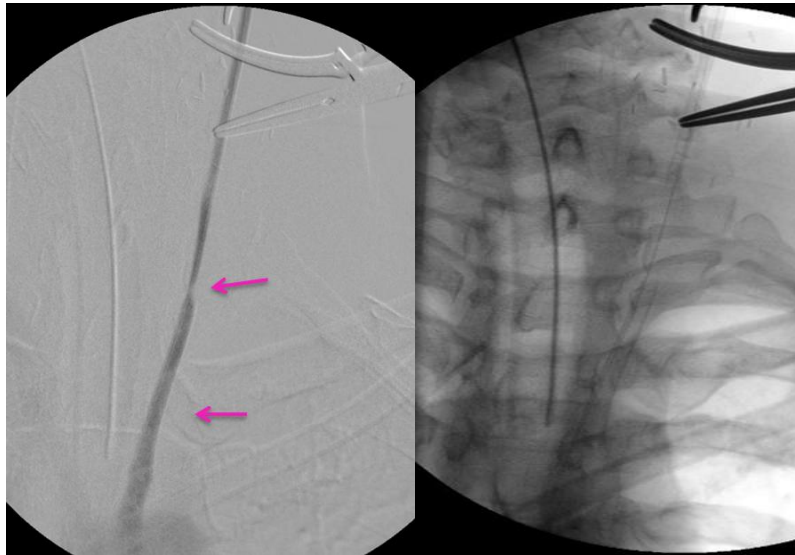


2a

2b

2c

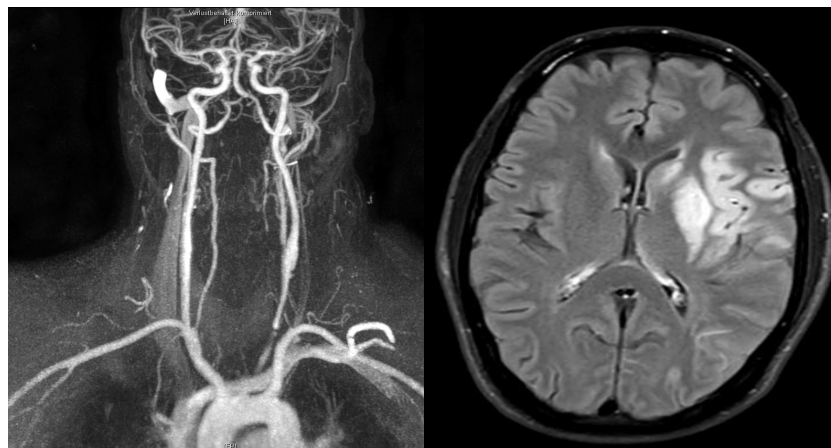
**Fig. 2 a-c: Angiography via the contralateral ACI, showing unchanged M1- occlusion (2a) and stop of contrast at the level of distal ACC (2b), angiography after placing the stent retriever and before first maneuver of clot retrieval (2c).**



3a

3b

**Fig. 3 a and b: Placed stent in ACC and poststenting angiography showing luminal narrowing distal of the stent but good proximal luminal diameter by retrograde contrast agent injection (upper arrow shows an intraoperative spasm in the distal section of the common carotid artery).**



4a

4b

**Fig 4a and b: MRI-angiography of the cervical and cerebral arteries shows perfusion of ACC and ACI Infarction seen in MRI 24h after inset**

## DISCUSSION

Relatively little has been reported in the literature regarding arterial dissections as complication of cervical or cerebral angiography or interventions. Summarized ID occurs more frequently during interventional neuroradiological procedures than during diagnostic cerebral angiography. It is also more common in extracranial arteries and shows increasing rates in emergency cases, such as MT.

Incidence in the literature of ID varies from 0-0.25% during diagnostic angiography of supraaortic arteries and climbs up to 0,7% performing elective endovascular intervention [8-11]. Dissections as periprocedural complication of endovascular treatment of AIS are given with rates from 0,6% up to 3,9 % for some of the HERMES-studies in the literature, a range, that was confirmed by a review of the SWIFFT database [1, 2, 5, 12]. Single center or not randomized control studies reported higher rates, up to 6,7% [7]. Overall, dissections of ACC as procedural complication of endovascular interventions seem to not be reported in literature. Cloft *et al.*, reported one case of ID of ACC by a total number of 3112 of angiographic procedures [11].

Causes for artery dissection (AD), aside from ID, could be subdivided in spontaneous and traumatic. Interestingly, dissection of ACI accounts for 2,5% of all first strokes but with prevalence of at least 20% ACI dissection is found in patients younger than 50 years having a stroke and might occur more often in wintertime [13, 14]. Spontaneous AD is often seen by patients suffering from fibromuscular dysplasia, Marfan syndrome or other connective tissue disorders [15]. Brand *et al.*, found ultrastructural abnormalities in more than 50% of otherwise healthy patients with dissection as well [16]. Moreover Simonetti *et al.*, described smoking and MT as risk factors for dissections in patients seeking endovascular stroke therapy [17].

Every type of dissection results from damages of the vessel which lead to intramural hematoma in distinct layers of the vessel wall. In the case of intimal tearing, blood flow forms a subintimal false lumen which leads to narrowing or occlusion of the real lumen. Damage near or at the deeper layers of the vessel wall may lead to aneurysmatic formations.

Dissection of ACC - spontaneous as iatrogenic - is a rarity. Our case report shows a rare but impactful complication performing MT and calls to mind some risk factors of having dissection of at least a certain group of patients with stroke. Young age, smoking, and MT are characteristic risk factors of having dissections, which were fulfilled by our patient. His initial CCT showed small infarction cores but large perfusion impact caused by M1-occlusion. It was assumed that the dissection of ACC aggravated the cerebral perfusion situation because of the leaking collateral blood flow

via ACE. Direct puncture and cross excess were not a way to go. Considering the patient's young age and the fact that the left side MCA was affected, we performed the combination of surgical vessel exploration and MT of M1 followed by retrograde stenting of ACC and patchplasty. Application of rtPA, followed by Aspirin and Clopidogrel together in a short time did neither lead to cerebral nor postoperative hematoma of the neck.

## CONCLUSION

The mentioned approach proved to be successful and should – from our experience – be considered as a rescue maneuver in such special cases.

## REFERENCES

1. Berkhemer OA, Fransen PSS, Beumer D, van den Berg LA, Lingsma HF, Yoo AJ *et al.* A randomized trial of intraarterial treatment for acute ischemic stroke. *N Engl J Med.* 2015; 372(1):11-20. doi: 10.1056/NEJMoa1411587.
2. Goyal M, Demchuk AM, Menon BK, Eesa M, Rempel JL, Thornton J *et al.* Randomized assessment of rapid endovascular treatment of ischemic stroke. *N Engl J Med.* 2015; 372(11):1019-1030. doi: 10.1056/NEJMoa1414905.
3. Campbell BCV, Mitchell PJ, Kleinig TJ, Dewey HM, Churilov L, Yassi N *et al.* Endovascular therapy for ischemic stroke with perfusion-imaging selection. *N Engl J Med.* 2015; 372(11):1009-1018. doi: 10.1056/NEJMoa1414792.
4. Saver JL, Goyal M, Bonafe A, Diener HC, Levy EI, Pereira VM *et al.* Stent-retriever thrombectomy after intravenous t-PA vs. t-PA alone in stroke. *N Engl J Med.* 2015; 372(24):2285-2295. doi: 10.1056/NEJMoa1415061.
5. Jovin TG, Chamorro A, Cobo E, de Miquel MA, Molina CA, Rovira A *et al.* Thrombectomy within 8 hours after symptom onset in ischemic stroke. *N Engl J Med.* 2015; 372(24):2296-2306. doi: 10.1056/NEJMoa1503780.
6. Nogueira RG, *et al.* Thrombectomy 6 to 24 Hours after Stroke with a Mismatch between Deficit and Infarct. *N Engl J Med.* 2018 Jan 4;378(1):11-21. doi: 10.1056/NEJMoa1706442. Epub 2017 Nov 11. PMID: 29129157.
7. Balami JS, White PM, McMeekin PJ, Ford GA, Buchan AM. Complications of endovascular treatment for acute ischemic stroke: Prevention and management. *Int J Stroke.* 2018; 13(4):348-361. doi: 10.1177/1747493017743051.
8. Thiex R, Norbash AM, Frerichs KU. The safety of dedicated-team catheter-based diagnostic cerebral angiography in the era of advanced noninvasive imaging. *AJNR Am J Neuroradiol.* 2010; 31(2):230-234. doi: 10.3174/ajnr.A1803.
9. Paramasivam S, Leesch W, Fifi J, Ortiz R, Niimi Y, Berenstein A. Iatrogenic dissection during neurointerventional procedures: a retrospective

- analysis. *J Neurointerv Surg.* 2012; 4(5):331-335. doi: 10.1136/neurintsurg-2011-010103.
10. Groves AP, Kansagra AP, Cross DWT, Moran CJ, Derdeyn CP. Acute management and outcomes of iatrogenic dissections during cerebral angiography. *Journal of NeuroInterventional Surgery.* 2017;9:499-501. doi: 10.1136/neurintsurg-2016-012285.
  11. Cloft HJ, Jensen ME, Kallmes DF, Dion JE. Arterial dissections complicating cerebral angiography and cerebrovascular interventions. *AJNR Am J Neuroradiol.* 2000 Mar;21(3):541-545.
  12. Akins PT, Amar AP, Pakbaz RS, Fields JD; SWIFT Investigators. Complications of endovascular treatment for acute stroke in the SWIFT trial with solitaire and Merci devices. *AJNR Am J Neuroradiol.* 2014 35(3):524-528. doi: 10.3174/ajnr.A3707.
  13. Thanvi B, Munshi SK, Dawson SL, Robinson TG. Carotid and vertebral artery dissection syndromes. *Postgrad Med J.* 2005 Jun;81(956):383-388. doi: 10.1136/pgmj.2003.016774.
  14. Schievink WI, et al. *J Neurosurg.* 1998 Jul;89(1):101-3. doi: 10.3171/jns.1998.89.1.0101. PMID: 9647179.
  15. Schievink WI, Michels VY, Piepgras DG. Neurovascular manifestations of heritable connective tissue disorders. A review. *Stroke.* 1994; 25(4):889-903. doi: 10.1161/01.str.25.4.889.
  16. Brandt T, Morcher M, Hausser I. Association of cervical artery dissection with connective tissue abnormalities in skin and arteries. *Front Neurol Neurosci.* 2005;20:16-29. doi: 10.1159/000088131.
  17. Simonetti BG, Hulliger J, Mathier E, Jung S, Fischer U, Sarikaya H et al. Iatrogenic Vessel Dissection in Endovascular Treatment of Acute Ischemic Stroke. *Clin Neuroradiol.* 2019; 29(1):143-151. doi: 10.1007/s00062-017-0639-z.