

Sudden Death in a Young Woman from Cerebral Venous Sinus Thrombosis: An Autopsy Case Report and Review

Pawan Mittal^{1*}, Shalley Dahiya², Anil Garg³, Yogesh Kumar Vashist⁴, Gaurav Sharma⁵¹Demonstrator, ³Professor, ⁴Assistant Professor, ⁵Professor and Head, Dept. of Forensic Medicine, B.P.S. Govt. Medical College for Women, Khanpur Kalan, Sonapat, Haryana, India²Addl. Senior Medical Officer (ASMO), Civil Hospital, Bahadurgarh, Jhajjar, IndiaDOI: [10.36347/sjams.2021.v09i05.007](https://doi.org/10.36347/sjams.2021.v09i05.007)

| Received: 29.03.2021 | Accepted: 07.05.2021 | Published: 11.05.2021

*Corresponding author: Pawan Mittal

Abstract

Case Report

Cerebral venous sinus thrombosis (CVST) is a rare form of stroke and carries a high rate of mortality in the acute phase. A higher incidence is found in women in comparison to men. Several risk factors have been recognized in females including pregnancy, puerperium, oral contraceptive (OC) pill usage, infections, inflammatory diseases, and thrombophilia. Headache due to raised intracranial tension has been described as the most common presenting symptom. The symptoms may be highly non-specific and misleading, carrying every possibility of a missed/delayed diagnosis which, if prove fatal, may possibly raise the question of medical malpractice. Although many case studies are available in the clinical literature, autopsy reports over CVST-related deaths may be found on a fringe only. A medicolegal case highlighting the sudden death of 24 years old young female is hereby reported in which an autopsy revealed multiple fresh antemortem thrombi in majority of the intracranial venous sinuses. Bilateral cerebral infarctions were found upon sectioning of the brain. The recent usage of the OC pills seemed to be the most likely culprit.

Keywords: sinus thrombosis, headache, cerebral infarction, oral contraceptive, autopsy.

Copyright © 2021 The Author(s): This is an open-access article distributed under the terms of the Creative Commons Attribution 4.0 International License (CC BY-NC 4.0) which permits unrestricted use, distribution, and reproduction in any medium for non-commercial use provided the original author and source are credited.

INTRODUCTION

Cerebral venous thrombosis is characterized by thrombosis of intracranial venous sinuses [Cerebral Venous Sinus Thrombosis (CVST)] or cortical veins [1]. It occurs less frequently than the thrombotic and embolic arterial infarctions. The clinical manifestations of CVST depend upon the location of thrombus and may include headache, seizure, focal neurological symptoms, and disturbances in the consciousness levels [2]. CVST accounts for 10%–20% of strokes in young persons and 0.5%–1% of all strokes [3].

CVST is often associated with infarction in the thalamus and basal ganglia, so the mortality rates in the acute phase are very high [4]. The infarcts may be pale or hemorrhagic while some patients may have associated subdural or subarachnoid bleeds [5]. Factors contributing to the occurrence of CVST differ between men and women. CVST shows much higher incidence in women in comparison to men [6].

Several risk factors for CVST have been recognized in females including pregnancy,

puerperium, oral contraceptive (OC) use, infections, inflammatory diseases, and thrombophilia [7]. Although many clinical case studies may be found in the literature, only a few autopsy reports over death from CVST have been published [4, 8, 9]. Most of these reports represent cases that were hospitalized and underwent a complete radiological survey prior to autopsy.

Herein, a case of sudden death of a 24 years old young, non-pregnant female from CVST is reported who had recently started taking oral contraceptive pills that complicated her general well-being and finally proved lethal to her. A medicolegal autopsy was performed that revealed thrombotic occlusion of multiple cranial venous sinuses along with pathological areas of cerebral infarctions.

CASE REPORT

Brief History

The present case belongs to a 24 years old female, village resident, married since 7 years with two healthy children (4 yrs ♂, 1.6 years ♀), born by

uneventful full term vaginal deliveries. There was no history of any prolonged illness or surgery. The lady was on regular oral contraceptive pills since last about 3 months for the purpose of family planning. After about one month of taking pills, she started complaining of headache with slight increase in blood pressure that was temporarily relieved by home remedies. The headache however did not show significant improvement rather was progressive in nature. She consulted a local practitioner who prescribed her certain analgesics and to stop consuming pills temporarily. However, she resumed the dosage after a couple of days due to fear of pregnancy.

On the day before her demise, her headache became unbearable and she was taken to the local hospital where her condition was slightly stabilized but by about midnight she had a relapse of severe headache along with the vomiting. The family rushed her to the referral care hospital. During transportation, she suffered a seizure with little frothing from the mouth and became unconscious.

At the emergency room she was received in the gasping state with marked hypotension and bradycardia. Intravenous fluids and oxygen were administered and endotracheal intubation was performed. However, clinical condition of the patient did not improve and finally the CPR was commenced that lasted for about 40 minutes. The patient succumbed to her illness and declared dead after about 4 hours of her last relapse of symptoms.

Police information (PI) was sent by the causality medical officer to the local police station and the dead body was brought for postmortem examination in the same day morning.

Autopsy Findings

It was a well built and nourished female body. No external or internal traumatic injury was present. Any evidence of foul play was ruled out.

On dissection of the head, a thin local film of subdural bleed was present over left parietal lobe parasagittally. As the falx cerebri was freed from its anterior attachment and pulled backwards, a large coiled and firm purplish thrombus extruded out from the posterior half of superior sagittal sinus (SSS) (Fig. 1).

The sinuses at the confluence and over base of the skull were also dusky purplish, distended and rubbery on palpation. Upon axial sectioning, multiple thrombi were found in the sinus rectus (straight sinus), bilateral transverse, sigmoid and superior petrosal sinuses (Fig. 2). The dark purplish thrombi were partly coiled and firm with paste like consistency, confirming their antemortem and recent character (Fig. 3). The cortical veins were distended. The internal jugular

veins, cavernous and anterior venous sinuses were free of any thrombi. Serial coronal sectioning of the brain revealed multiple areas of cerebral ischemic infarctions primarily involving basal ganglia, thalami and the watershed zones of cortex (Fig. 4).

Cut surface of the liver and spleen revealed areas of hemorrhagic necrosis. Renal cortex depicted changes typical of shock kidney. Isolated pin point subendocardial hemorrhages were found along the left ventricle outflow tract. Marked pulmonary congestion and edema was appreciated along with coarse whitish froth and mucus in the airways. Gastric contents and mucosa were unremarkable, lacking any abnormal odor or constituents. Coils of gut were distended and pale.

No evidence of pulmonary embolism or DVT of either lower limbs or pelvic veins was found. No chronic cardiac or pulmonary pathology was present. Toxicology analysis of viscera and body fluids was negative for any poison or abnormal drugs.

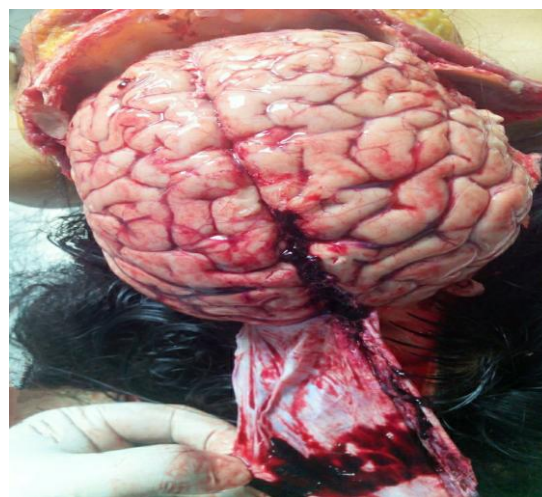

Fig-1: Dark purplish thrombi in the Superior Sagittal Sinus

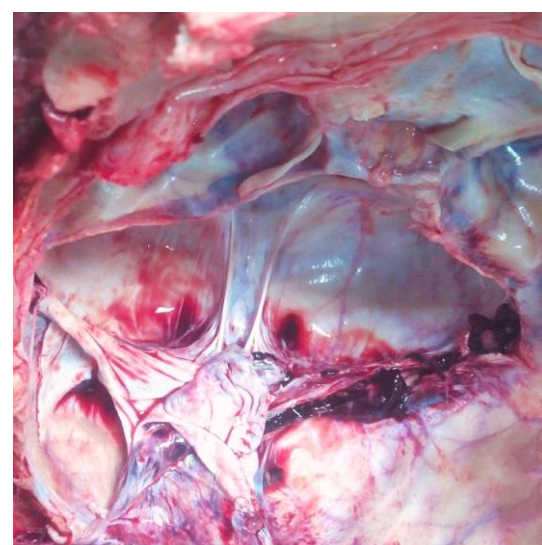


Fig-2: Highly coiled and tube-paste like thrombi in the right transverse and sigmoid sinuses

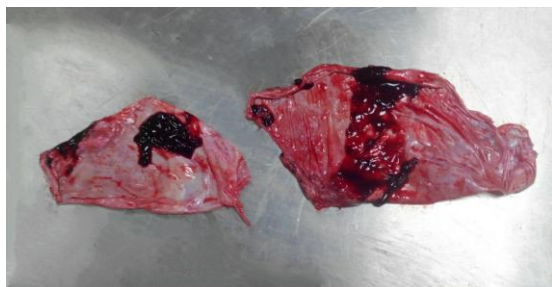

Fig-3: Sinus dura mater containing fresh and coiled to cylindrical antemortem thrombi

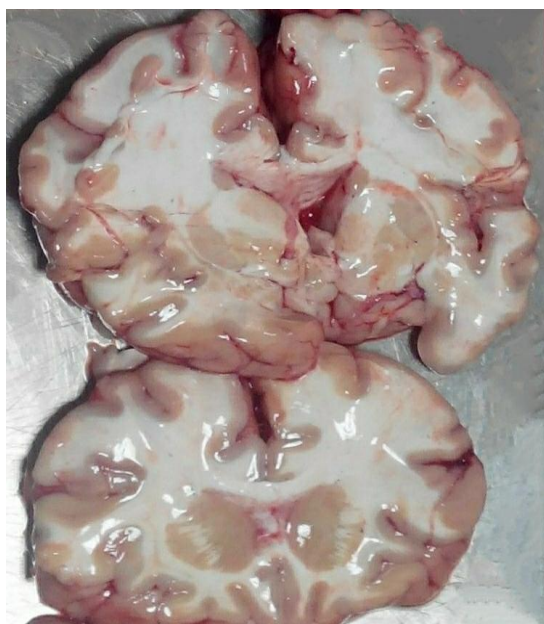

Fig-4: Cerebral ischemic infarcts involving bilateral basal ganglia, thalami and the watershed zones

DISCUSSION

Cerebral venous sinus thrombosis is one of the leading causes of stroke in young women [10]. The thromboembolic episodes are common among pregnant as well as non-pregnant females. Pregnancy and puerperium are common causes of transient prothrombotic states in women carrying an increased risk of venous thromboembolism. The risk factors among non-pregnant CVST patients are multifactorial and include anemia, use of oral contraceptives (OC), genetically determined prothrombotic states, dehydration, hyperhomocysteinemia, infection, trauma, carcinoma, systemic causes and blood disorders [2].

In the present case, consumption of OC pills seems to be the most likely cause of thrombosis leading to the demise of young woman. In general, venous thrombosis tends to develop in women who have used oral contraceptives for a prolonged period [11]. But the women with additional risk factors, especially inherited clotting defects such as deficiencies of protein C, protein S, or antithrombin, or otherwise mutations of factor V Leiden or prothrombin 20210 A, may develop venous thrombosis significantly earlier than those without such defects [12]. Such an investigation was

however not carried out in the present case. A similar autopsy case of a non-pregnant woman has been previously described where death from CVST occurred just after two months of starting OC pill [low-dose estrogenic combined hormonal contraceptives (CHCs)] [4].

The overall mortality in CVST is reported to be 5%–30% [5, 13]. Higher mortality has been reported in non-pregnant women in comparison to pregnancy related venous thrombosis [14]. Cerebral parenchymal involvement is common due to hemorrhagic and/or ischemic venous infarcts in the brain which primarily involves the basal ganglia and thalami. Bilateral infarcts commonly develop when the thrombus involves the straight sinus [4]. Cerebral oedema with its impending dangers develops in a subset of patients.

Clinical presentation of CVST may vary and can be very dramatical. It can suddenly present with headaches due to intracranial hypertension, focal neurological problems, convulsions and lethargy [13]. Headache has been described as the most common presenting symptom of CVST, although its exact pathophysiology is not clear [5, 13, 15]. Superior sagittal sinus (SSS) is the most common site of thrombosis followed by sigmoid and transverse sinuses. The disease process may affect single or multiple sinuses while the involvement may be uni- or bilateral [4, 5, 8, 15]. The incidence of SSS thrombosis is about 1 per 250 pregnant women in India meanwhile its incidence is very low in developed countries [3, 8]. An autopsy study from India has revealed ten percent incidence of CVST in all patients with stroke [16].

De-giorgio and colleagues have described a postmortem case of 31-year old woman which revealed cerebral venous sinus thrombosis (CVST) at autopsy that extended from the confluence of the sinuses to the right transverse and superior sagittal sinuses. A thrombus that filled the right sigmoid sinus was extending along the internal jugular vein (IJV) from its bulb to the C5–C6 level in the neck. The authors attributed CVST in that case to the spontaneous, progressive and retrograde thrombosis of right IJV which was responsible for the sudden death of the young woman while the etiology remained unclear [9].

Cases of CVST with unclear etiologies commonly present as an extension of jugular vein thrombosis where the abnormalities in structural development of the jugular vein(s) walls have been hypothesized to affect cerebral venous flow which causes insufficient blood return and the resulting CVST [17]. De-giorgio and colleagues further proved this association histopathologically [9].

Canverenler et al. have reported a case of 30 years old maternal death due to cerebral venous sinus thrombosis after delivery via cesarean section that was

initially admitted and evaluated in the hospital with complaints of severe headache, paraparesis and coughing. At autopsy, superior sagittal, transverse and straight sinuses were enlarged by multiple antemortem thrombi while intracerebral bleeding and foci of brainstem bleeding were found additionally. Marked venous distension and arterial dilation (without aneurysm) were found [8].

Uemura *et al.* described the clinical, postmortem 3T-MRI and autopsy features in a 20-year-old Japanese woman patient with CVST who died shortly after starting to use low-dose estrogen CHCs. An autopsy and histological examination revealed an organizing white thrombus occupying the lumen of the left sigmoid sinus while an acute, red thrombus was found in the left transverse, straight and tentorial sinuses, and the vein of Galen. The authors opined that the thrombus developed first in the left sigmoid sinus, then extended retrograde to the more proximal portion of the sinus system finally reaching the vein of Galen [4].

Thrombosis of cerebral veins or sinuses may be misdiagnosed or diagnosed too late on account of subtle and non-specific presenting symptoms, which may become the issue of medical malpractice. This is particularly true in patients with unknown risk factors. About 17–27 % of CVST cases have unknown etiologies [18]. The genetic or inherited mutations including enzymatic and metabolic defects are equally uncommon and may account for 10–15 % of all cases of CVST [19]. The MTHFR C677T mutation appears to increase the risk for developing CVST or pulmonary embolism in association with other risk factors for these conditions [20].

The prognosis of CVST varies and depends largely on a timely diagnosis along with the patients' response to the anticoagulant heparin therapy and endovascular-based approach or neurosurgical decompression, whenever performed. The phenomenon is rare and easily escapes clinical diagnosis, particularly in the acute phase. However with prompt recognition and treatment, the chances of survival, even without residual disability, are very high. The diagnosis is based on radiological imaging which is guided by the patient's clinical and neurological presentation. Non-contrast computed tomography (CT) performed in an emergency setting may suggest the diagnosis of CVST while the angio-magnetic resonance imaging (angio-MRI) or digital angiography are the most effective techniques to identify the condition [9].

In the present case, no helpful radiological or hospital records were available at autopsy. Most of the treatment and follow up record of the deceased was lacking, which is not uncommon in a rural setting. A scrupulous autopsy finally proved the sole factor in concluding the cause of death.

CONCLUSION

A forensic pathologist may become involved in a case of sudden death from cerebral venous sinus thrombosis where his diagnostic suspicion at autopsy is guided by the history, clinical profile and circumstances of the case. It should be remembered however that the hospital and necessary investigation details may not be available in every case while the history may be too non-specific and cursory. In such cases, the value of a prime and careful autopsy along with a sound and well-based opinion cannot be overemphasized.

Conflicts of interest statement

The authors have no possible conflicts of interests.

REFERENCES

1. Putaala, J., Metso, A. J., Metso, T. M., Konkola, N., Kraemer, Y., Haapaniemi, E., ... & Tatlisumak, T. (2009). Analysis of 1008 consecutive patients aged 15 to 49 with first-ever ischemic stroke: the Helsinki young stroke registry. *stroke*, 40(4), 1195-1203.
2. Narayan, D., Kaul, S., Ravishankar, K., Suryaprabha, T., Bandaru, V. S., Mridula, K. R., ... & Borgohain, R. (2012). Risk factors, clinical profile, and long-term outcome of 428 patients of cerebral sinus venous thrombosis: Insights from Nizam's Institute Venous Stroke Registry, Hyderabad (India). *Neurology india*, 60(2), 154-159.
3. Srinivasan, K. (1984). Ischemic cerebrovascular disease in the young. Two common causes in India. *Stroke*, 15(4), 733-735.
4. Uemura, M., Tsukamoto, Y., Akaiwa, Y., Watanabe, M., Tazawa, A., Kasahara, S., ... & Nishizawa, M. (2016). Cerebral venous sinus thrombosis due to oral contraceptive use: Postmortem 3 T-MRI and autopsy findings. *Human Pathology: Case Reports*, 6, 32-36.
5. Saroja, A. O., Tapsi, C., & Naik, K. R. (2017). Cerebral venous thrombosis in women from Indian subcontinent. *Journal of the Scientific Society*, 44(1), 20-25.
6. Duman, T., Uluduz, D., Midi, I., Bektas, H., Kablan, Y., Goksel, B. K., ... & Uzuner, N. (2017). A multicenter study of 1144 patients with cerebral venous thrombosis: the VENOST study. *Journal of Stroke and Cerebrovascular Diseases*, 26(8), 1848-1857.
7. Saadatnia, M., Mousavi, S. A., Haghighi, S., & Aminorroaya, A. (2004). Cerebral vein and sinus thrombosis in Isfahan-Iran: a changing profile. *Canadian journal of neurological sciences*, 31(4), 474-477.
8. Canverenler, E., Kasap, B., Erbaş, M., Karbeyaz, K., & Balci, Y. (2015). Maternal Death Due to Sagittal Sinus Thrombosis-Autopsy Diagnosis: A Case Report. *J Clin Stud Med Case Rep*, 2(1).

9. De-Giorgio, F., Peschillo, S., Vetrugno, G., d'Aloja, E., Spagnolo, A. G., & Miscusi, M. (2015). Cerebral venous sinus thrombosis due to spontaneous, progressive, and retrograde jugular vein thrombosis causing sudden death in a young woman. *Forensic science, medicine, and pathology*, 11(1), 88-91.
10. Bansal, B. C., Gupta, R. R., & Prakash, C. (1980). Stroke during pregnancy and puerperium in young females below the age of 40 years as a result of cerebral venous/venous sinus thrombosis. *Japanese heart journal*, 21(2), 171-183.
11. Lidegaard, Ø., Løkkegaard, E., Svendsen, A. L., & Agger, C. (2009). Hormonal contraception and risk of venous thromboembolism: national follow-up study. *Bmj*, 339, b2890.
12. Bloemenkamp, K. W., Rosendaal, F. R., Helmerhorst, F. M., & Vandenbroucke, J. P. (2000). Higher risk of venous thrombosis during early use of oral contraceptives in women with inherited clotting defects. *Archives of internal medicine*, 160(1), 49-52.
13. Agostoni, E. (2004). Headache in cerebral venous thrombosis. *Neurological Sciences*, 25(3), s206-s210.
14. Cantu, C., & Barinagarrementeria, F. (1993). Cerebral venous thrombosis associated with pregnancy and puerperium. Review of 67 cases. *Stroke*, 24(12), 1880-1884.
15. Uluduz, D., Sahin, S., Duman, T., Ozturk, S., Yayla, V., Afsar, N., ... & Gunes, T. (2020). Cerebral Venous Sinus Thrombosis in Women: Subgroup Analysis of the VENOST Study. *Stroke Research and Treatment*, 2020.
16. Banerjee, A. K., Varma, M., Vasista, R. K., & Chopra, J. S. (1989). Cerebrovascular disease in north-west India: a study of necropsy material. *Journal of Neurology, Neurosurgery & Psychiatry*, 52(4), 512-515.
17. Jia, L. Y., Yang, H. U. A., Ji, X. M., & Liu, J. T. (2012). Correlation analysis of internal jugular vein abnormalities and cerebral venous sinus thrombosis. *Chinese medical journal*, 125(20), 3671-3674.
18. Bousser, M. G., & Ferro, J. M. (2007). Cerebral venous thrombosis: an update. *The Lancet Neurology*, 6(2), 162-170.
19. Allroggen, H., & Abbott, R. J. (2000). Cerebral venous sinus thrombosis. *Postgraduate medical journal*, 76(891), 12-15.
20. Ali, Z., Troncoso, J. C., & Fowler, D. R. (2014). Recurrent cerebral venous thrombosis associated with heterozygote methylenetetrahydrofolate reductase C677T mutation and sickle cell trait without homocysteinemia: an autopsy case report and review of literature. *Forensic science international*, 242, e52-e55.