

Unusual Case of Inguinal Bladder Hernia: About A Case Report

M. Badraoui*, S. Faiz, B. Boutakioute, M. Ouali Idrissi, N. Chefir El Ganouni Idrissi

Department of Radiology, Hospital Arrazi, CHU Mohamed VI, Marrakech, Cadi Ayyad University, Faculty of Medicine and Pharmacy, Marrakech

DOI: [10.36347/sjmcr.2021.v09i05.015](https://doi.org/10.36347/sjmcr.2021.v09i05.015)

Received: 03.04.2021 | Accepted: 10.05.2021 | Published: 14.05.2021

*Corresponding author: M. Badraoui

Abstract

Case Report

The inguinal bladder hernia is a rare entity and constitutes 1 to 5% of inguinal hernias. Medical imaging is essential to confirm the diagnosis. Treatment consists of hernia surgery with reintegration of the bladder.

Keywords: hernia, bladder, inguinal hernia.

Copyright © 2021 The Author(s): This is an open-access article distributed under the terms of the Creative Commons Attribution 4.0 International License (CC BY-NC 4.0) which permits unrestricted use, distribution, and reproduction in any medium for non-commercial use provided the original author and source are credited.

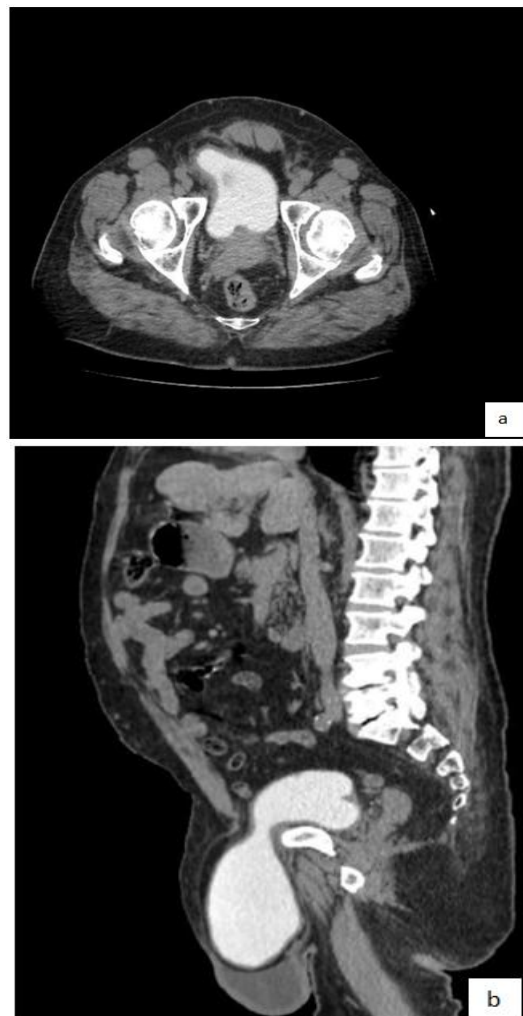INTRODUCTION

Hernia is the passage of abdominal or pelvic contents through an abdominal wall defect or inguinal canal. It results from the association of a parietal weakness with an increase in intra-abdominal pressure [1]. Prostatic obstruction being the most common cause in the elderly. Inguinal hernia rarely involve the bladder. If it does, there are usually no clinical signs to detect it. The following case reports an incidental finding of a bladder hernia.

CASE REPORT

We report the case of a 56-year-old patient, without any particular pathological history, who presents a right inguinal swelling, evolving for 24 months without any other associated signs. On examination, a soft, round, well-limited inguinal mass was found. On ultrasonography: cystic formation, well limited, round shape, thin-walled, non-vascularised on color Doppler.

A uro-CT was requested which objectified a bladder of right inguinal location.



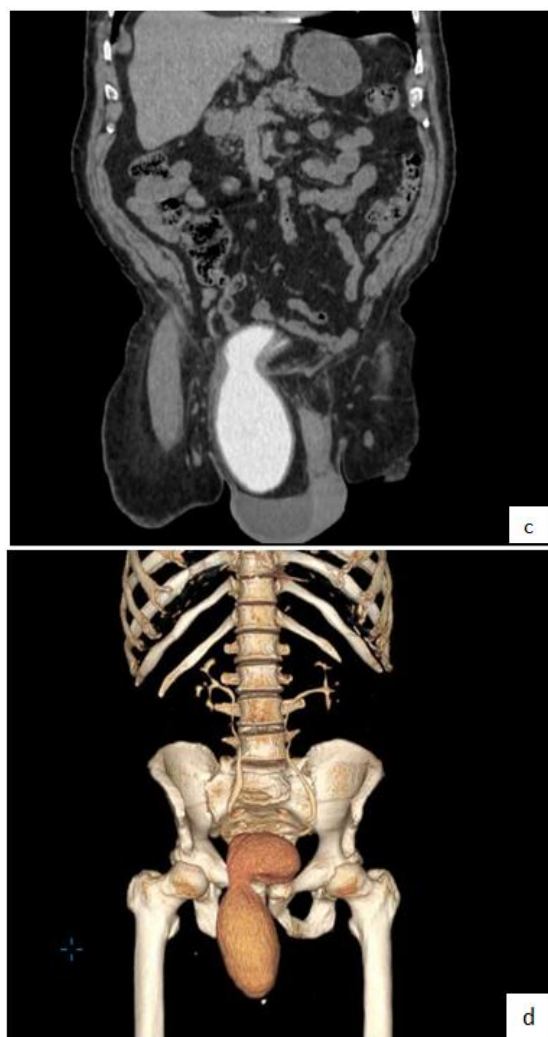


Fig-1: Uro-CT: Axial (a), sagittal (b), coronal (c) and 3D (d) sections at the delayed phase, showing a hernia of the left bladder horn at the inguinal level

DISCUSSION

The inguinal bladder hernia is a rare entity and constitutes 1 to 5% of inguinal hernias. Some data report a percentage of 1-3% [1, 2], and affects mostly men between the ages of 50 and 70 [3, 4]. The existence of lower urinary tract disorders is a risk factor [5, 6] for the disease. Hernias may involve a bladder horn, a diverticulum or even the entire bladder. They cause symptoms ranging from a simple irritative syndrome to acute obstructive renal failure [7, 8]. A very revealing clinical sign is a two-stage micturition, facilitated by pressure on the hernial arch and the disappearance of the hernia after bladder emptying [9, 10]. However, this pathology often remains asymptomatic. Therefore, the diagnosis is usually per operative. In 279 of 347 cases reported by Watson, a bladder hernia was discovered during surgery [11].

L'existence de troubles urinaires du bas appareil constitue un facteur de risque [5, 6] de la maladie. Les hernies peuvent toucher une corne vésicale, un diverticule ou même l'ensemble de la

vessie. Elles sont responsables d'une symptomatologie allant du simple syndrome irritatif jusqu'à l'insuffisance rénale aiguë obstructive [7, 8]. Une miction en deux temps, facilitée par l'appui sur la voussure herniaire et la disparition de la hernie après la vidange vésicale, constitue un signe clinique très révélateur [9, 10]. Or, cette pathologie reste souvent asymptomatique. De ce fait, le diagnostic est généralement per opératoire. Dans 279 des 347 cas signalés par Watson, une hernie vésicale a été découverte pendant l'intervention chirurgicale [11].

In this case, irritative symptomatology was associated with prostatic pathology. No bladder hernia was suspected on clinical examination. Preoperative imaging can be of great help to the surgeon, as it can consolidate the diagnosis, guide the surgical exploration and, consequently, limit the risk of neglecting or even damaging the bladder during the surgical procedure. Ultrasound, CT scan, and cystography can be very helpful in showing the portion of the herniated bladder involved in the inguinal canal [7].

In this case, the ultrasound did not make it possible to specify the hernial contents, the discovery having taken place during the intraoperative phase. The complications of bladder hernia are essentially urinary infection and urinary lithiasis [12]. The occurrence of an intra-hernial bladder tumor has also been reported [13].

Treatment consists of hernia surgery with reintegration of the bladder. In case of large hernia, bladder diverticulum, short neck or bladder necrosis, the herniated part can be respected. In our patient, after confirmation of the diagnosis, the resection of the bladder diverticulum allowed to gain space following the suture of the bladder wall. Thus, the herniated part could be reintegrated easily at the pelvic level. The procedure was completed by closing the deep inguinal opening. Thus, treating a bladder hernia first and foremost knows how to recognize it. That said, intraoperative recognition of a bladder hernia is not always obvious. In 43 of 347 cases reported by Watson [11].

The diagnosis was made in the postoperative phase following the development of a urinary fistula and wall infection due to undiagnosed bladder injury. Inguinal hernia is a frequent complication of prostate adenoma. It occurs in 15-25% of cases of prostate adenoma [14]. Treatment of prostatic obstruction should be considered before or at the same time as treatment of the hernia, because persistent dysuria carries the risk of recurrence. The presence of an inguinal hernia does not warrant surgical treatment of prostatic adenoma [15], which can be treated medically, endoscopically, or surgically during inguinal hernia surgery [14].

In the presence of a bladder hernia, surgical treatment of prostatic adenoma has not been shown to produce better results [16]. Although surgical treatment of prostatic adenoma allows for better deobstruction, there may be an alternative: medical treatment that allows for a significant improvement in debimetric parameters. In our patient, the prostatic adenoma responded well to medical treatment, resulting in an improvement of the obstructive symptomatology. Clinical, ultrasound and debimetric monitoring is still necessary.

CONCLUSION

Inguinal bladder hernia is relatively rare but remains a diagnosis to be made in a patient over fifty years of age who presents inguinal swelling associated with LUTS. Adequate imaging is essential to confirm the diagnosis and allow rapid and accurate management.

REFERENCES

1. Levine, B. (1951). Scrotal cystocele. *JAMA*, 147:1439-41.
2. Izes, B. A., Larsen, C. R., Izes, J. K., & Malone, M. J. (1993). Computerized tomographic appearance of hernias of the bladder. *The Journal of urology*, 149(5), 1002-1005.
3. JM, C. S. (2001). Giant inguino-scrotal hernia of the bladder. Clinical case and review of the literature. *Actas urologicas espanolas*, 25(4), 315-319.
4. Fisher, P. C., Hollenbeck, B. K., Montgomery, J. S., & Underwood III, W. (2004). Inguinal bladder hernia masking bowel ischemia. *Urology*, 63(1), 175-176.
5. Koontz, A. R. (1955). Sliding hernia of diverticulum of bladder. *AMA archives of surgery*, 70(3), 436-438.
6. Iason, A.H. (1944). Repair of urinary bladder herniation. *Am J Surg*; 63:69-77.
7. Storm, D. W., & Drinis, S. (2008). Radiographic diagnosis of a large inguinal hernia involving the urinary bladder and causing obstructive renal failure. *Urology*, 72(3), 523.
8. Wagner, A. A., Arcand, P., & Bamberger, M. H. (2004). Acute renal failure resulting from huge inguinal bladder hernia. *Urology*, 64(1), 156-157.
9. Gomella, L. G., Spires, S. M., Burton, J. M., Ram, M. D., & Flanigan, R. C. (1985). The surgical implications of herniation of the urinary bladder. *Archives of Surgery*, 120(8), 964-967.
10. Schaeffer, E. M., & Bhayani, S. B. (2003). Inguinal bladder hernia. *Urology*, 62(5), 940.
11. Watson, L.F. (1948). *Hernia*. Saint-Louis: Mosby;12.
12. Ptochos, A., & Iosifidis, N. (2002). Lithiasic inguinoscrotal herniation of the bladder secondary to prostate enlargement. *Acta Radiologica*, 43(5), 543-544.
13. Caterino, M., Finocchi, V., Giunta, S., De Carli, P., & Crecco, M. (2001). Bladder cancer within a direct inguinal hernia: CT demonstration. *Abdominal imaging*, 26(6), 0664-0666.
14. Dahami, Z., Barjani, F., Saghir, O., Moudouni, M. S., & Sarf, I. (2009). Combined inguinal hernia repair and transurethral resection of the prostate (TURP) for benign prostatic hypertrophy. *Journal de chirurgie*, 146(6), 549-552.
15. Initial assessment and follow-up of benign prostatic hyperplasia. (2012). Systematic review of the literature by the LUTS committee of the French Urological Association [in French]. *Prog Urol*, 22:1-6.
16. Kursh, E. D., & Persky, L. (1975). Preperitoneal herniorrhaphy: Adjunct to prostatic surgery. *Urology*, 5(3), 322-325.