

## Adenoid Cystic Carcinoma of the Submandibular Gland: A Case Report

Niema Benkhraba<sup>1,3\*</sup>, Najwa Belhaj<sup>1,3</sup>, Mohamed Ali Gliti<sup>1,3</sup>, Sophia Nitassi<sup>2,3</sup>, Bencheikh Razika<sup>2,3</sup>, Benbouzid Mohamed Anas<sup>2,3</sup>, Abdelilah Oujilal<sup>2,3</sup>, Leila Essakalli Houssyni<sup>2,3</sup>

<sup>1</sup>Resident Physician in Otorhinolaryngology, Department of Otorhinolaryngology, Head and Neck Surgery, Ibn Sina University Hospital, Rabat, Morocco

<sup>2</sup>Professor of Otorhinolaryngology, Department of Otorhinolaryngology, Head and Neck Surgery, Ibn Sina University Hospital, Rabat, Morocco

<sup>3</sup>Faculty of Medicine and Pharmacy of Rabat, Mohammed V University, Rabat, Morocco

DOI: [10.36347/sjams.2021.v09i05.017](https://doi.org/10.36347/sjams.2021.v09i05.017)

| Received: 04.03.2021 | Accepted: 03.04.2021 | Published: 22.05.2021

\*Corresponding author: Niema Benkhraba

### Abstract

### Case Report

Tumors of the salivary gland are comparatively rare, comprising less than 3% of all tumors. The distribution of tumors in the major salivary glands varies by site, with 85% to 90% occurring in the parotid gland, 10% to 15% occurring in the submandibular gland, and only 1% occurring in the sublingual gland. There is a higher incidence of malignancy in submandibular and sublingual tumors as compared with parotid tumors. Adenoid cystic carcinoma (ACC) is a malignancy of the seromucinous glands of the head and neck, accounting for 35% to 43% of malignant submandibular gland neoplasms. The majority of patients with ACC present with an asymptomatic mass that may have been present for months or even years prior to diagnosis. Adenoid cystic carcinoma is well known for its indolent pattern of recurrence and propensity for pulmonary metastases. Furthermore, it has a prolonged natural history and is slow growing even when there has been local recurrence and distant metastases. We report the case of a 46-year-old patient diagnosed with adenoid cystic carcinoma of the submaxillary gland, evolving for 5 years.

**Keywords:** Adenoid cystic carcinoma, submaxillary gland, surgery, radiotherapy, recurrence, metastases.

**Copyright © 2021 The Author(s):** This is an open-access article distributed under the terms of the Creative Commons Attribution 4.0 International License (CC BY-NC 4.0) which permits unrestricted use, distribution, and reproduction in any medium for non-commercial use provided the original author and source are credited.

## INTRODUCTION

Adenoid cystic carcinomas (ACC) or cylindromas were initially described by Robin and Laboulbène in 1852 [1]. Adenoid cystic carcinomas are rare and usually develop at the expense of the salivary glands. They represent the main histologic type of accessory salivary gland tumors and account for approximately 10-20% of all salivary gland tumors [2]. ACC represent approximately 1% of ENT cancers, but can more rarely be found in all sites including secretory glands (breast, cervix, colon, prostate, etc.) [3]. Despite the non-aggressive histological character and the good short-term therapeutic results [4], the management of ENT cylindroma remains difficult because of their insidious growth, neurological tropism, and their metastatic potential. These associated elements delay the diagnosis which is often made when the tumor is locally advanced, and make the surgery difficult and late recurrence frequent. The treatment of these tumors has been long relied on exclusive surgery. Until the publications of Stewart et al., Then of King et al. in the 1970s, these retrospective studies have shown the benefit of a treatment combining surgery and

radiotherapy, in terms of local control and disease-free survival, compared to surgery or radiotherapy alone [5-8].

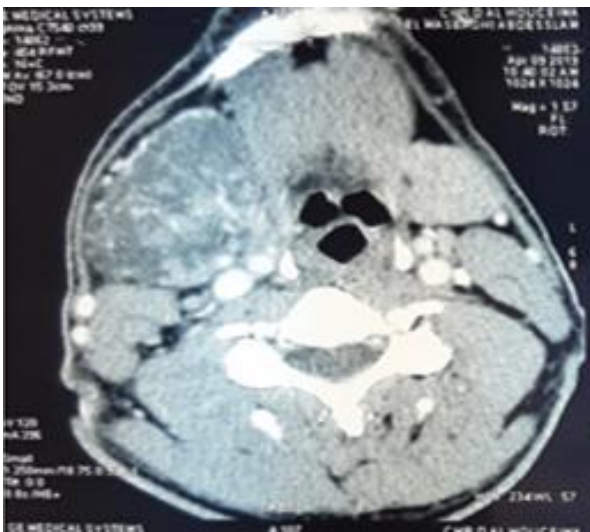
We report the case of a 46-year-old patient diagnosed with adenoid cystic carcinoma of the submaxillary gland, evolving for 5 years.

## CASE REPORT

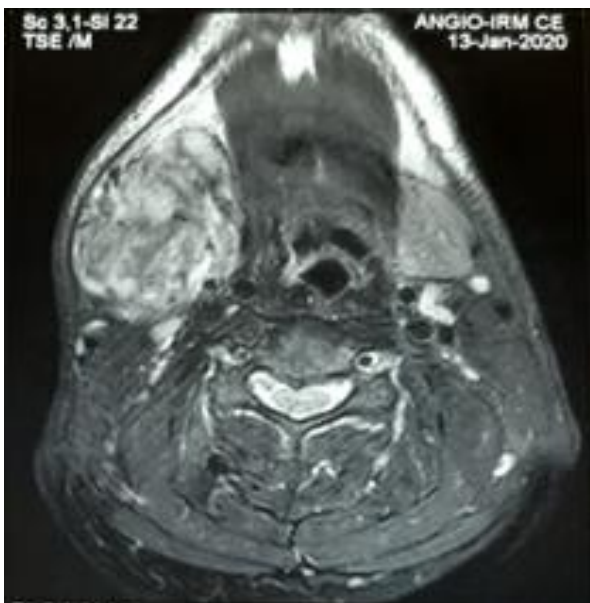This is a 46-year-old patient, chronic tobacco user, who has presented for 5 years with right submandibular tumefaction, gradually increasing in size, painful, without local heat or redness. Clinical examination found a right submandibular tumefaction, approximately 7cm long, of firm consistency, painless on palpation. With an intraoral expression of the mass, without flow through the Wharton orifice, and without palpable cervical lymphadenopathies.

The cervical CT scan shows the presence in the right submaxillary gland, a hypodense tissue mass enhanced moderately after injection of contrast dye, with multiple tortuous vascular structures exceeding the

mass and extending towards the parapharyngeal space and the right parotid region. This mass is well limited responsible for a thinning of the mandibular angle. Angio-MRI was also performed, shows a voluminous formation with regular contours, with hypointense signal in T1, and heterogeneous hyper signal in T2. Also the presence of bilateral cervical lymphadenopathies of which the most voluminous is in the left chain IIa measuring 11mm. A right submandibulectomy with homolateral angular mandibulectomy was realized. The aftermath of the surgery was simple. The final anatomic-pathologic study concluded adenoid cystic carcinoma of the submaxillary gland. A postoperative radiotherapy at a dose of 60 Gy was performed. The evolution was favorable with a follow-up of 24 months.



**Fig-1. CT scan : Aspect of a vascular-looking mass of the right submaxillary gland.**



**Fig-2. Angio-MRI: Aspect of a formation in the right submaxillary gland, well hyper diffusion, strongly enhanced, suggesting first of all a cylindroma**

## DISCUSSION

Three histological subtypes of ACC are known, as described above: the cribriform, tubular, and solid subtypes. Among the three subtypes, the solid subtype is the most aggressive [9, 14, 15]. Immunohistochemistry plays an important role in identifying the current case. CD117 was strongly expressed in this carcinoma. P63, S-100, and SMA are intensely stained in myoepithelial cells [16, 17]. In contrast, CK5 and CK7 are expressed in luminal cells [17].

The peak incidence of ACC among people is from 40 to 60 years of age, 11, 15, which suggests that ACC is predominately a tumor of adulthood. Although a 1:1.3 male to female ratio was observed, another report demonstrated ACC with a slight female predominance, 3: 2 male to female ratio [18]. The typical clinical symptom involves a slow-growing, firm, unilobular mass in the gland. An important associated symptom is painful swelling. Sometimes clinical symptoms are ignored so the tumor can grow rather large.

Surgical treatment of this lesion should therefore entail wide local excision of the submandibular space, including the submandibular gland, digastrics muscle, posterior mylohyoid muscle, lingual and marginal mandibular nerves, and the periosteum of the mandible. The hypoglossal nerve should be biopsied and resected if found to have perineural invasion on frozen section. Mandibular resection should be reserved for cases where the mandible is clinically or radiographically invaded. Neck dissections should be performed only in patients with known local lymph node involvement.

Most authors agree that ACC is radiosensitive but not radiocurable. However, several studies have indicated that combined therapy may offer improved local control [17, 20, 23, 24] and possibly prolonged survival [25]. Based on the study of Cohen and al [35], postoperative radiotherapy is recommended in the following situations: perineural invasion, positive surgical margins, T2 or larger tumors, and regional metastases. (Figure 3).

The recommendation of adjuvant radiotherapy often depends on putative prognostic indicators, which include stage, tumor site, microscopic or gross disease at the surgical margin, histological type, and perineural or perivascular invasion [20]. In previous reports, the dose of adjuvant radiotherapy ranged from 44 to 68.4 Gy, with a mean dose of 60 Gy [20, 21, 22]. Patients who received a dose greater than 60 Gy after surgery were reported to have significantly higher local control rates than those who received less than 60 Gy [23]. The total dose should be no less than 66 Gy. In cases with a positive margin, the dose should reach 66 to 70 Gy. It

seems that cisplatin, as well as high-dose melphalan, chemotherapy should cause a favorable result, but no statistically significant difference was confirmed in survival compared to placebo [24, 25].

DM is one of the most common features of ACC and usually occurs as a sign of the late course of disease [26]. Sung *et al.* [12] reported that the median DM interval was 48 months after the initial treatment in 46 ACC patients. The most common site of metastasis is lung [15]. However, ACC can also metastasize to other organs including bone, cerebrum, liver, thyroid, and spleen [27]. Lung metastases usually progress slowly.

On the contrary, bone metastases indicate a rapid progression [28, 29].

There are some factors associated with DM in ACC patients. The perineural invasion has been concerned to be an unfavorable prognostic factor, associated with DM and adverse final outcome [11, 30]. A solid subtype, primary tumor larger than 3 cm, a primary tumor located in the minor glands of oral cavity and pharynx, local recurrence, and cervical lymph node involved were also demonstrated [9, 33]. Compared with DM, local lymph node metastases are rare, but it is also a predictor of negative outcome [34].

#### Tumor (T)

**TX:** Indicates the primary tumor cannot be evaluated.

**T0 (T plus zero):** No evidence of a tumor was found.

**T1:** Describes a small, noninvasive (has not spread) tumor that is 2 cm at its greatest dimension.

**T2:** Describes a larger, noninvasive tumor between 2 cm to 4 cm.

**T3:** Describes a tumor that is larger than 4 cm but not larger than 6 cm and has spread beyond the salivary glands but does not affect the seventh nerve, the facial nerve that controls expression, such as smiles or frowns.

**T4a:** The tumor has invaded the skin, jawbone, ear canal, and/or facial nerve.

**T4b:** The tumor has invaded the skull base and/or the nearby bones and/or encases the arteries.

#### Node (N)

**NX:** The regional lymph nodes cannot be evaluated.

**N0:** There is no evidence of cancer in the regional lymph nodes.

**N1:** Cancer has spread to a single lymph node on the same side as the primary tumor, and the cancer found in the lymph node is 3 cm or smaller.

**N2:** Describes any of these conditions:

- **N2a:** The cancer has spread to a single lymph node on the same side as the primary tumor and is larger than 3 cm but smaller than 6 cm.
- **N2b:** The cancer has spread to more than 1 lymph node on the same side as the primary tumor, and none measures larger than 6 cm.
- **N2c:** The cancer has spread to more than 1 lymph node on either side of the body, and none measures larger than 6 cm.

**N3:** The cancer found in the lymph nodes is larger than 6 cm.

#### Metastasis (M)

**MX:** Indicates distant metastasis cannot be evaluated.

**M0:** Indicates the cancer has not spread to other parts of the body.

**M1:** Describes cancer that has spread to other parts of the body.

**Fig-3: TNM staging system**

## CONCLUSION

Adenoid cystic carcinoma of the submandibular gland is a slow-growing, insidious lesion with a prolonged natural history that includes a tendency toward local recurrence and distant metastasis. Early diagnosis is important, since advance tumor size is a poor prognostic factor. Wide surgical excision aimed at negative surgical margins offers the best chance for local control, and neck dissection should be reserved for those patients with clinically positive nodal metastases. Finally, postoperative radiation therapy should be strongly considered in those patients with perineural invasion, positive surgical margins, T2 or larger tumors, and/or regional metastases.

## REFERENCES

1. Billroth T. Untersuchungen über die Entwicklung der Blutgefäße, Die Cylindergeschwulst. Berlin: G. Reimer. 1856: 55-69.
2. Pulec JL. Adenoidcystic carcinoma (cylindroma) of the external auditory canal. *Trans Am Acad Ophthalmol Otolaryngol.* 1963; 67:673.
3. Henderson JW, Neault RW. En bloc removal of intrinsic neoplasms of the lacrimal gland. *Am J Ophthalmol.* 1976; 82:905-909.
4. Lerner AG. Adenoid cystic carcinoma of the breast. *Am J Surg.* 1974; 127:585- 587.
5. Abell MR. Adenocystic (pseudoadenomatous) basal cell carcinoma of the vestibular glands of

- the vulva. *Am J Obstet Gynecol.* 1963; 86:470–482.
6. Maciel Santos MES, Ibrahim D, Neto JC, Da Silva JC, Da Silva UH, Sobral APV. Carcinoma adenóide cístico: relato de caso. *Rev Cir Traumatol Buco-Maxilo-Fac.* 2005;5:49–54.
  7. Berdal P. Cylindroma of salivary glands: a report of 80 cases. *Acta Otolaryngol.* 1970;263:170–173.
  8. Spiro RH. Salivary neoplasms: overview of a 35-year experience with 2,807 patients. *Head Neck Surg.* 1986; 8:177–184.
  9. Barnes L, Eveson JW, Reichart P, Sidransky D, editors. World Health Organization classification of tumours. Pathology and genetics of head and neck tumors. Tumors of the salivary glands. Lyon: IARC; 2005. 24-5, 209-22, 332-323.
  10. Matsuba HM, Specto GJ, Thawley SE, Mauney M, Pikul FJ. Adenoid cystic salivary gland carcinoma: a histopathologic review of treatment failure patterns. *Cancer.* 1986;57:519-524.
  11. Rapidis AD, Givalos N, Gakiopoulou H, Faratzis G, Stavrianos SD, Vilos GA. Adenoid cystic carcinoma of the head and neck. Clinicopathological analysis of 23 patients and review of the literature. *Oral Oncol.* 2005; 41:328-335.
  12. Sung MW, Kim KH, Kim JW, Min YG, Seong WJ, Roh JL. Clinicopathologic predictors and impact of distant metastasis from adenoid cystic carcinoma of the head and neck. *Arch Otolaryngol Head Neck Surg.* 2003; 129:1193-1197.
  13. Khan AJ, DiGiovanna MP, Ross DA, Sasaki CT, Carter D, Son YH, Haffty BG. Adenoid cystic carcinoma: a retrospective clinical review. *Int J Cancer* 2001; 96:149-158.
  14. Al-Sukhun J, Lindqvist C, Hietanen J, Leivo I, Penttila H. Central adenoid cystic carcinoma of the mandible: case report and literature review of 16 cases. *Oral surgery, oral medicine, oral pathology, oral radiology, and endodontics.* 2006;101:304-308
  15. Zhang CY, Xia RH, Han J, Wang BS, Tian WD, Zhong LP, Tian Z, Wang LZ, Hu YH, Li J. Adenoid cystic carcinoma of the head and neck: clinicopathologic analysis of 218 cases in a Chinese population. *Oral Surg Oral Med Oral Pathol Oral Radiol.* 2013; 115:368-75.
  16. Malhotra KP, Agrawal V, Pandey R. High grade transformation in adenoid cystic carcinoma of the parotid: report of a case with cytologic, histologic and immunohistochemical study. *Head Neck Pathol.* 2009; 3:310-314.
  17. Zhao C, Liu JZ, Wang SB, Wang SC. Adenoid cystic carcinoma in the maxillary gingiva: a case report and immunohistochemical study. *Cancer Biol Med.* 2013; 10:52-54.
  18. Ellis GL, Auclair PL. Adenoid cystic carcinoma. In: Rosai Juan, editor. Atlas of tumor pathology. Tumors of the salivary glands. Washington, DC: Armed Forces Institute of Pathology. 1996: 203–16.
  19. Nobis CP, Rohleder NH, Wolff KD. Head and neck salivary gland carcinomas-- elective neck dissection, yes or no? *J Oral Maxillofac Surg.* 2014 Jan;72(1):205-10.
  20. Avery CME, Moody AB, McKinna FE, Taylor J, Henk JM, Langdon JD. Combined treatment of adenoid cystic carcinoma of the salivary glands. *Int J Oral Maxillofac Surg.* 2000; 29: 277–9.
  21. Gao M, Hao Y. Clinicopathological study of distant metastases of salivary adenoid cystic carcinoma. *Int J Oral Maxillofac Surg.* 2013 Aug;42(8):923-8.
  22. Hsu HC, Huang EY, Wang CJ. Postoperative adjuvant radiotherapy for adenoid cystic carcinoma of the head and neck: treatment results and prognostic factors. *Chang Gung Med J.* 2003 Sep; 26(9):646-53.
  23. Simpson JR, Thawley S, Matsuba H. Adenoid cystic salivary gland carcinoma: Treatment with irradiation and surgery. *Radiology* 1984; 151: 509-12.
  24. Slichenmyer WJ, LeMaistre CF, Von Hoff DD. Response of metastatic adenoid cystic carcinoma and Merkel cell tumor to high-dose melphalan with autologous bone marrow transplantation. *Invest New Drugs.* 1992; 10:45–48.
  25. Sessions RB, Lehane DE, Smith RJ, Bryan RN, Suen JY. Intraarterial cisplatin treatment of adenoid cystic carcinoma. *Arch Otolaryngol.* 1982; 108:221–224.
  26. Giannini PJ, Shetty KV, Horan SL, Reid WD, Litchmore LL. Adenoid cystic carcinoma of the buccal vestibule: A case report and review of the literature. *Oral Oncol.* 2006; 42:1029-1032.
  27. Spiro RH, Huvos AG, Strong EW. Adenoid cystic carcinoma of salivary origin. A clinicopathologic study of 242 cases. *Am J Surg.* 1974; 128:512–520.
  28. Van der Wal JE, Becking AG, Snow GB, van der Waal I. Distant metastases of adenoid cystic carcinoma of the salivary glands and the value of diagnostic examinations during follow-up. *Head Neck.* 2002; 24:779–783.
  29. Bradley PJ. Distant metastases from salivary glands cancer. *ORL J Otorhinolaryngol Relat Spec.* 2001;63:233–242
  30. Huang M, Ma D, Sun K, Yu G, Guo C, Gao F. Factors influencing survival rate in adenoid cystic carcinoma of the salivary glands. *Int J Oral Maxillofac Surg.* 1997; 26:435–439.
  31. Bianchi B, Copelli C, Cocchi R, Ferrari S, Pederneschi N, Sesenna E. Adenoid cystic carcinoma of intraoral minor salivary glands. *Oral Oncol.* 2008; 44:1026- 1031.

32. Khan AJ, DiGiovanna MP, Ross DA, Sasaki CT, Carter D, Son YH, Haffty BG. Adenoid cystic carcinoma: a retrospective clinical review. *Int J Cancer*. 2001; 96:149-158.
33. Spiro RH. Distant metastasis in adenoid cystic carcinoma of salivary origin. *Am J Surg*. 1997; 174:495-498.
34. Conley J, Dingman DL. Adenoid cystic carcinoma in the head and neck (cylindroma). *Arch Otolaryngol*. 1974; 100:81-90.
35. Alen N. Cohen, Edward J. Damrose, Robert Y. Huang, Scott D. Nelson, Keith E. Blackwell, and Thomas C. Calcaterra, Los Angeles, California. Adenoid cystic carcinoma of the submandibular gland: A 35-year review. *Otolaryngology-Head and Neck Surgery* Volume 131 Number 6.