

Arteriovenous Malformation of the External Ear: Case Report

A Diani^{1*}, B Boutakioute¹, M Aitchtoug¹, A El Hajjami¹, Z Belhaj¹, M Ouali Idrissi¹, N Cherif Idrissi Guenouni¹

¹Department of Radiology, AR-RAZI Hospital, Mohamed VI University Hospital Center, Marrakech

DOI: [10.36347/sjmc.2021.v09i05.022](https://doi.org/10.36347/sjmc.2021.v09i05.022)

| Received: 09.04.2021 | Accepted: 16.05.2021 | Published: 22.05.2021

*Corresponding author: Diani Abdelwahed

Abstract

Case Report

Arteriovenous malformation (AVM) occurs due to the failure of complete involution of the fetal capillary bed resulting in the development of abnormal connections between arteries and veins (arteriovenous shunting). The most frequent location of arteriovenous malformations in the head and neck is intracranial, they can also occur in the cheek and parotid, ear, nose, forehead, and neck regions. The ear is the second most common location in the head and neck. We report a case of giant AVM of the left pinna in an adolescent, which are very rarely seen. We discussing the definition, clinical findings, diagnostic approaches and therapeutic management of arteriovenous malformations.

Keywords: Arteriovenous malformation (AVM), arteriovenous shunting, head and neck.

Copyright © 2021 The Author(s): This is an open-access article distributed under the terms of the Creative Commons Attribution 4.0 International License (CC BY-NC 4.0) which permits unrestricted use, distribution, and reproduction in any medium for non-commercial use provided the original author and source are credited.

INTRODUCTION

Arteriovenous malformation (AVM) occurs due to the failure of complete involution of the fetal capillary bed resulting in the development of abnormal connections between arteries, veins (arteriovenous shunting) [1] and is an uncommon clinical condition. Arteriovenous malformations in the head and neck are present at birth but are rarely symptomatic in the neonatal period. Instead, they manifest during late childhood, adolescence or early adulthood, and usually expand following minimal trauma, infection or hormonal changes [2-3].

The most frequent location of arteriovenous malformations in the head and neck is intracranial, they can also occur in the cheek and parotid, ear, nose, forehead, and neck regions [3-4].

Arteriovenous malformation outside the cranium is rare; however, the ear is the second most common location in the head and neck [4-5]. Auricular arteriovenous malformation has been the subject of single case reports or small series [3-5-6]. The rarity of these latter arteriovenous malformations limits systematic study, their unpredictable behavior renders prognosis difficult, and poor treatment outcomes are common [4].

We report a case of giant AVM of the left pinna in an adolescent which are very rarely seen.

CASE REPORT

A 13-year-old teenager with a left auricular deformity that has been evolving since birth, currently admitted to the plastic surgery department for significant volume enlargement and active bleeding. The patient has already undergone surgery 4 years ago for his deformity with 13 sessions of sclerotherapy giving a slight improvement.

On inspection, the patient's left pinna was blue purple in color and hypertrophic. It was pushing forward and outwards. Engorged vein and pulsations were clearly seeing. The margins were irregular and ill defined. The transillumination test was negative. On palpation, swelling was compressible and non tender with no underlying bone defect. Fluctuation test was positive. Pulsations were feeling. On auscultation, continuous bruit were hearing. External auditory canal and tympanic membrane was difficult to examine (**Fig-1**).

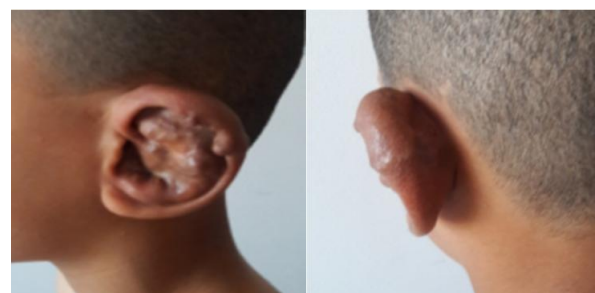


Fig-1: Pre-operative appearance of left ear.

The patient was referring to our radiology department for a CT scan angiography of head and neck. Spirally acquires CT study performed in arterial phase with coronal and sagittal reconstruction revealed large arteriovenous malformation in left pinna extends to the external part of the external auditory canal and the retro auricular region. Mainly the external carotid artery via the superficial temporal and posterior auricular arteries feeds this malformation. The draining venous channels showed aneurismal dilatations. It was draining into external and internal jugular vein (**Fig-2**).

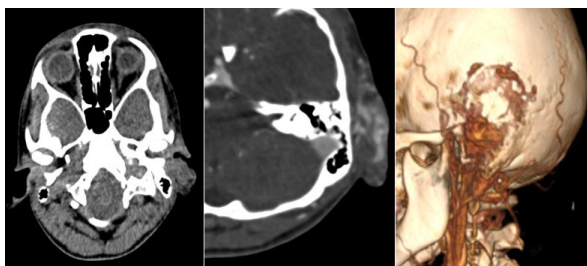


Fig-2: Computed tomographic angiography before (A) and after (B) contrast injection and in 3D reconstruction (C): Thickening of the left pinna extending into the external auditory canal with individualization of several serpiginous vascular structures within it after injection of contrast agent.

In order to have more details on the branches feeding and draining this malformation, we completed by an angiography of the supra-aortic trunks which has objective a large arteriovenous malformation, fed mainly by large ectatic branches of the external carotid artery including the parietal branch of the superficial temporal artery, collateral branches of the occipital artery and the posterior auricular artery and secondarily by fine branches from the left internal carotid and vertebral arteries.

Venous return is mainly on the left side in the external jugular vein via tortuous veins collateral to the arterial branches (**Fig-3**).

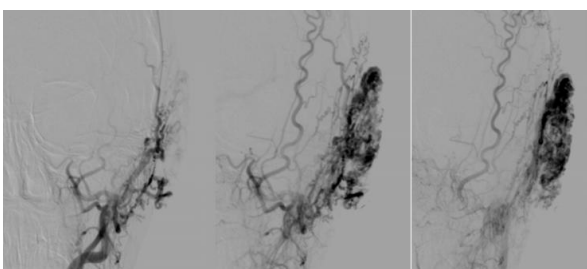


Fig-3: 3 images of selective external carotid angiography showing the advancement of contrast material into the external carotid artery and its branches and the drainage of the left auricular AVM.

Due to lack of resources and active bleeding, the patient benefited from a total amputation of the auricle with a good evolution and stop of the bleeding.

DISCUSSION

Milliken and Glowacki divided the vascular anomalies on two main categories: Hemangioma and vascular malformation. Hemangiomas are characterized by accelerated endothelial proliferation followed by regression over a five- to eight-year period. In contrast, the endothelial cells in vascular malformations have a normal rate of cellular division and do not regress [3].

Vascular malformations are subdivided into ‘slow-flow’ or ‘fast-flow’ types, based on flow dynamics – ‘slow-flow’ malformations may be of capillary, venous, lymphatic type or combination, whereas ‘fast-flow’ ones would be of AVMs or fistulas [1-6-7]. In the head and neck region, ‘fast-flow’ AVMs are less common as compared with the ‘slow-flow’ vascular malformations, and when present, they are most commonly located in the brain followed by perioral, parotid and neck regions [1-6].

Histologically, arteriovenous malformations may contain arteriovenous shunts with reactive, hypertrophic, thick-walled arteries and veins because of the increased blood flow [3-6].

In some patients with inheritable AVM, mutations have been identified in TGF- β , RASA1 and PTEN genes, which may alter the balance between factors, involved in vasculogenesis [1-8]. However, in our case, there was no occurrence of AVMs among the family members.

Arteriovenous malformations are thought to be present at birth but may not be clinically evident. Their increase in size is due to increased blood flow. Most vascular malformations present clinically during childhood and grow commensurately with the child. However, some malformations may remain quiescent until adolescence and in rare cases into adulthood. Enlargement of the arteriovenous malformation may be triggered by trauma, infection, puberty or other hormonal influences such as pregnancy. Our patient noted rapid enlargement of her preexisting pinna arteriovenous malformation during the puberty period [3-9].

The most common location of arteriovenous malformations in the head and neck is intracranial. They also occur in the cheek and parotid, ear, nose, forehead, and neck regions [4-10]. In the literature, auricular and external auditory meatus arteriovenous malformations are rare and have been the subject of single case reports and small series [3-10-11].

Schobinger classified AVM into four stages. The symptoms of stage I (quiescence) are warm and discolored skin; those of stage II (expansion) are bruit, pulsation, and swelling. Stage III (destruction) is characterized by pain, ulceration, and bleeding; whereas stage IV (decompensation) features cardiac failure [4-12-13]. The distressing symptoms of auricular

arteriovenous malformation may include throbbing pain, a buzzing sensation and pulsatile tinnitus that may prevent sleep. Our patient is a stage II of Schobinger classification.

A clinical diagnosis of arteriovenous malformation is often indicated by the history and physical examination.

The CT scan angiography has provided significant improvements in vascular applications allow non-invasive vascular evaluation. Advantages of CT angiography (CTA) include shorter acquisition times, retrospective creation of thinner sections from source data, improved 3D rendering with diminished artifacts. CTA can also provide a very high temporal resolution and the visualization of the related adjacent bony structures, which may be important in surgical planning.

However, MRI and angiography are essential for evaluating symptomatic malformations. Magnetic resonance imaging is the current 'gold standard' for assessing the extent of involvement within tissue planes and for demonstrating flow characteristics. Angiography demonstrates the feeding vessels, as well as providing information on anastomoses with other extracranial or intracranial vessels, and on the venous drainage pattern. Angiography is usually reserved until after treatment, planning is complete, and it used for 'super selective' embolization before surgical extirpation. The target of embolization must be the nidus or epicentre of the arteriovenous malformation rather than proximal feeding vessels.

Clinically, it is difficult to select the optimal treatment, which will maintain long-term success in arteriovenous malformation management. If the AVM is small and asymptomatic, no treatment is required, especially in children. For a symptomatic AVM, complete excision with prior embolization is the treatment of choice in large or recurrent AVM (3-14). Combined embolotherapy and sclerotherapy is a new therapeutic modality, which has gained acceptance as an independent treatment.

CONCLUSION

Arteriovenous malformations of the auricle are rare, requiring a thorough knowledge of the anatomy of the region and the pathophysiology of the malformation, an early diagnosis can avoid complications that may arise.

BIBLIOGRAPHY

- Aslan, S., Yavuz, H., Cagici, A. C., & Kizilkilic, O. (2008). Embolisation of an extensive arteriovenous malformation of the temporal region as an alternate treatment: case report. *The Journal of laryngology and otology*, 122(7), 737.

- Burrows, P. E., Mulliken, J. B., Fishman, S. J., Klement, G. L., & Folkman, J. (2009). Pharmacological treatment of a diffuse arteriovenous malformation of the upper extremity in a child. *Journal of Craniofacial Surgery*, 20, 597-602.
- Flye, M. W., Jordan, B. P., & Schwartz, M. Z. (1983). Management of congenital arteriovenous malformations. *Surgery*, 94(5), 740-747.
- June, K., Wu, M.D., Annouk Bisdorff, M.D., Françoise Gilbert, M.D., & Odile Enjolras, M.D., Patricia, E., Burrows, M.D., John, B., & Mulliken, M.D. (2003). Auricular Arteriovenous Malformation: Evaluation, Management, and Outcome Presented at the 82nd Annual Meeting of the American Association of Plastic Surgeons, in Baltimore, Maryland, doi: 10.1097/01.PRS.0000154207.87313.DE
- Kim, S. H., Han, S. H., Song, Y., Park, C. S., & Song, J. J. (2017). Arteriovenous malformation of the external ear: a clinical assessment with a scoping review of the literature. *Brazilian journal of otorhinolaryngology*, 83(6), 683-690.
- Kohout, M. P., Hansen, M., Pribaz, J. J., & Mulliken, J. B. (1998). Arteriovenous malformations of the head and neck: natural history and management. *Plastic and reconstructive surgery*, 102(3), 643-654.
- Madana, J., Yolmo, D., Saxena, S. K., Gopalakrishnan, S., & Nath, A. K. (2010). Giant congenital auricular arteriovenous malformation. *Auris Nasus Larynx*, 37(4), 511-514.
- McGill, T.J.I., Mulliken, J.B. (1993). Vascular anomalies of the head and neck. eds. *Otolaryngology-Head and Neck Surgery*, 2nd edn. St Louis: Mosby-Year Book, 333-46.
- Pham, T. H., Wong, B. J., & Allison, G. (2001). A large arteriovenous malformation of the external ear in an adult: report of a case and approach to management. *The Laryngoscope*, 111(8), 1390-1394.
- Seccia, A., Salgarello, M., Farallo, E., & Falappa, P. G. (1999). Combined radiological and surgical treatment of arteriovenous malformations of the head and neck. *Annals of plastic surgery*, 43(4), 359-366.
- Tark, K. C., & Chung, S. (2000). Histologic change of arteriovenous malformations of the face and scalp after free flap transfer. *Plastic and reconstructive surgery*, 106(1), 87-93.
- Thornton, B. P., Sloan, D., & Rinker, B. (2006). Squamous cell carcinoma arising from an arteriovenous malformation of the scalp. *Journal of Craniofacial Surgery*, 17(4), 805-809.
- Wu, J. K., Bisdorff, A., Gelbert, F., Enjolras, O., Burrows, P. E., & Mulliken, J. B. (2005). Auricular arteriovenous malformation: evaluation, management, and outcome. *Plastic and reconstructive surgery*, 115(4), 985-995.
- Yoshida, Y., Ishizawa, T., Mitsuhashi, Y., Kondo, S., Ohta, N., & Sakai, N. (2006). A patient with subaural arteriovenous malformation complicated by macrotia. *Clinical and Experimental Dermatology: Viewpoints in dermatology*, 31(1), 151-152.