

Retroperitoneal Schwannoma: A Case Report

Othmane El houadfi^{1*}, Amine Saouli¹, Imad Ziouziou², Tarik Karmouni¹, Khalid El Khader¹, Abdellatif Koutani¹, Ahmed Iben Attya Andaloussi¹

¹Urology Service B, CHU Ibn Sina, Faculty of Medicine and Pharmacy, Mohamed V University, Rabat, Morocco

²Urology service, CHU Agadir, Faculty of Medicine and Pharmacy, Université IBN Zohr, Agadir, Morocco

DOI: [10.36347/sasjs.2021.v07i05.010](https://doi.org/10.36347/sasjs.2021.v07i05.010)

| Received: 09.04.2021 | Accepted: 17.05.2021 | Published: 27.05.2021

*Corresponding author: Dr. Othmane El houadfi

Abstract

Case Report

Retroperitoneal schwannoma is a rare benign tumor of the retroperitoneum. We report a clinical case of a 39-year-old female patient in whom was discovered incidentally at ultrasound a left pre-renal tissue mass measuring 5 cm. Computed tomography revealed the intimacy of this mass with the left kidney, aorta and the renal pedicle. Then the patient had a total excision of the tumor. Histological examination of the surgical specimen concluded to retroperitoneal schwannoma. The evolution was good without recurrence after 3years.

Keywords: Schwannoma; retroperitoneal; surgery.

Copyright © 2021 The Author(s): This is an open-access article distributed under the terms of the Creative Commons Attribution 4.0 International License (CC BY-NC 4.0) which permits unrestricted use, distribution, and reproduction in any medium for non-commercial use provided the original author and source are credited.

INTRODUCTION

Schwannoma is a tumor arising from the Schwann nerve sheath. Retroperitoneal schwannoma (RPS) is a rare form [1]. Its diagnosis is often unexpected preoperatively, and it is asserted only after histological examination of the operative specimen of the retroperitoneal mass. In this article, we report the clinical case of a voluminous PRS, and analyze, through a literature review, the epidemiological, diagnostic, and therapeutic aspects of this pathology.

OBSERVATION

Mrs. Z.T., 39 years old, had no previous pathological history. She had been complaining intermittently of epigastric tenderness with nausea-like digestive disturbances for four months in a context of conservation of her general condition, without any associated urinary, digestive or gynecological disorders.

On clinical examination, the patient was afebrile. Her conjunctiva were normally stained, and her abdomen was flexible. There was no lumbar contact on palpation. The lymph node areas were free.

An abdominal ultrasound was requested by her attending doctor, which revealed a left prerenal, rounded, heterogeneously echogenic tissue mass measuring 5 cm in long axis (Figure 1).

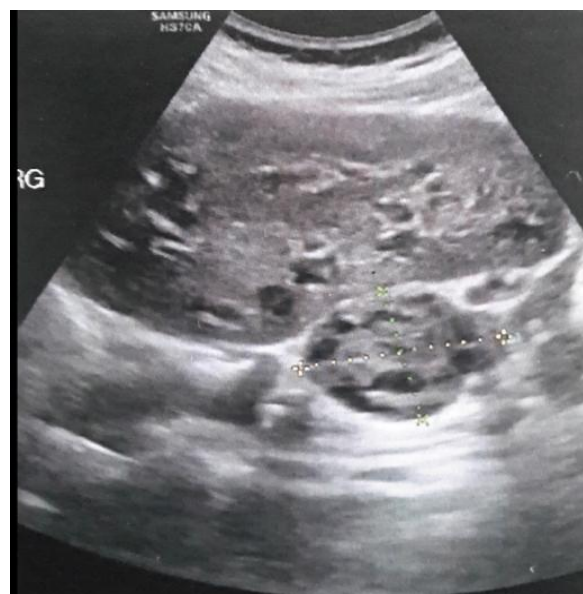

Fig-1: Ultrasound: left prerenal, rounded, heterogeneously echogenic tissue mass measuring 5 cm long axis

CT scan showed a retroperitoneal, left prerenal mass, 47 mm long axis, with tissue density, estimated at 32 Hounsfield units (HU) without injection, not enhancing after contrast injection. This mass was in intimate contact with the left kidney, aorta, and renal pedicle with no visible border of separation (Figure 2). No adenopathy was visible.

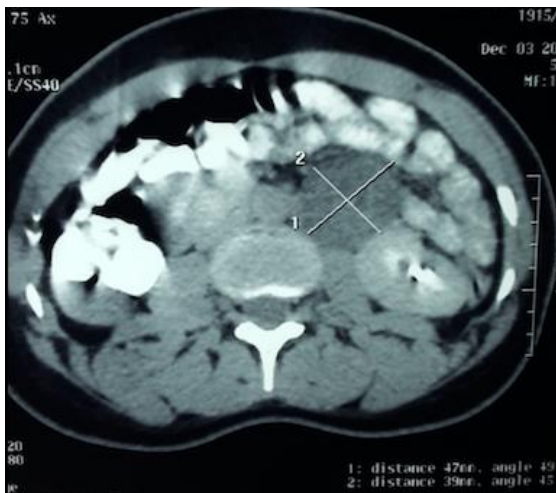

Fig-2: CT scan: retroperitoneal, left pre renal mass with tissue density (32 HU), measuring 47 mm long axis

Biologically, the patient had a hemoglobin level of 11.7g/dl, white blood cells of 2920/mm³, normal renal function with creatinemia at 6.8 mg/L.

The patient underwent a left subcostal operation. After detachment of the left colonic angle, the retroperitoneal mass was discovered, whitish in appearance, mobile, latero-aortic, in intimate contact with the left renal pedicle. This mass was progressively released after section and ligation of a feeder vessel located at its lower pole. A total removal of the mass was performed (Figure 3). The postoperative course was simple.

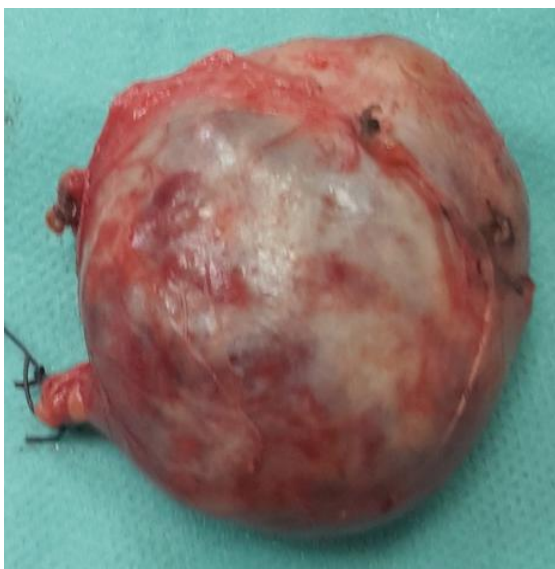

Fig-3: Surgical piece of retroperitoneal mass, weighing 29.4 g, measuring 4.5 cm × 4 cm × 1.5 cm

On gross examination, the mass was firm, well-bounded, smooth-surfaced and whitish in color. On section, it had a cystic, multilocular appearance with serous fluid issue (Figure 4).

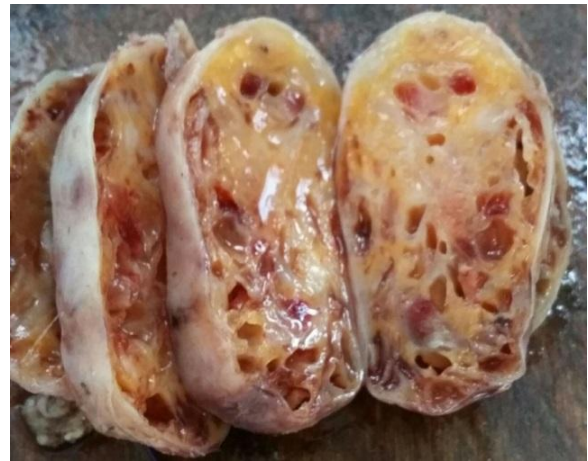

Fig-4: Macroscopic appearance on section

Microscopic examination revealed a benign tumor proliferation made essentially in the periphery of cells with neuroid differentiation. These cells were organized in short bundles with a peripheral palisading arrangement. They had undulating nuclei with fine chromatin. The rest of the tumor was made of loose edematous and fibrous areas with the presence of numerous vessels, some of which had a thickened and hyalinized wall (Figures 5, 6).

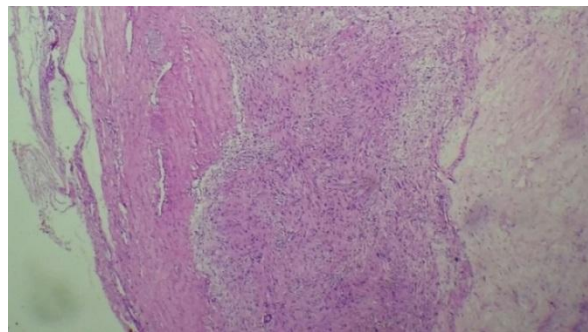


Fig-5: Peripheral neuroid component and myxoid loose areas with numerous vessels (magnification × 4, hematein-eosin)

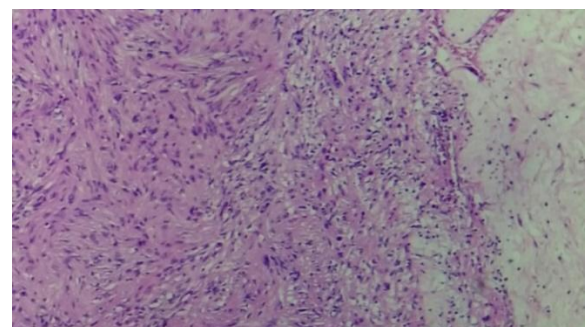


Fig-6: Neuroid differentiation zone: intersecting bundles with peripheral palisading (magnification x 10, hematein-eosin)

The immunohistochemical study showed a diffusé and intense positive labelling of the tumour cells with anti PS 100 antibody, and negative with anti AML antibody (Figure 7).

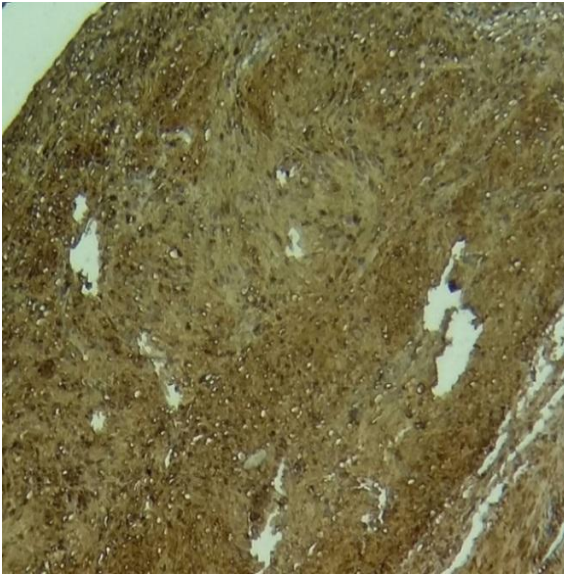


Fig-7: Immunohistochemistry: diffuse and intense expression of anti PS100 antibody by tumor cells (magnification x 20)

This morphological and immunohistochemical analysis concluded to a schwannoma. The evolution was marked by the absence of recurrence after 3 years of follow-up.

DISCUSSION

Retroperitoneal localization of schwannoma is rare. Its frequency is estimated at 4% [1, 2]. This location represents only 0.7% of benign schwannomas compared to 1.7% of malignant schwannomas [3, 4]. The latter form occurs mainly in the context of Von Recklinghausen disease (4-18% of cases) [5]. The incidence of schwannoma is difficult to establish because many series include these tumors with neurofibromas. The sex ratio is equal to 1 and the age of the patients is most often between 30 and 60 years [6].

Retroperitoneal schwannoma is often revealed during the exploration of unexplained low back pain or because of compression of neighboring organs: epigastralgia and dyspepsia, but also portal thrombosis [7] or ureteral compression with upstream ureterohydronephrosis [8] or renal-vascular hypertension. As it can remain asymptomatic. The diagnosis is sometimes made in the presence of an increase in abdominal volume by clinical examination or routine ultrasound [9]. This lack of specificity of clinical signs sometimes makes its diagnosis difficult and often late.

If ultrasound and/or CT scan make the diagnosis of retroperitoneal mass, they do not show pathognomonic images. However, schwannoma is classically described as a solid tumor, well encapsulated, when it is still small in volume. It may become hemorrhagic and necrotic when the volume becomes larger [10]. The presence of intra-tumoral cysts which are found in 63% of cases for benign

schwannomas and in 75% of cases for malignant schwannomas. This is noteworthy because retroperitoneal tumors rarely constitute cysts [11]. The presence of calcifications is an element in favor of degeneration [6].

Histology that allows us to make a diagnosis of certainty. Retroperitoneal tumors are sometimes histologically heterogeneous, which recommends surgical removal [12].

There are two histological types of schwannomas: Antoni A composed of bipolar cells intertwined in a palisade, well organized, and Antoni B where pleiomorphic cells are arranged in a fibrillar, loose weft [6]. The expression of the PS100 protein in immunohistochemical studies is a sign of neuroectodermal differentiation, and its positivity points to a schwannoma [13, 14].

The reference treatment is purely surgical. It can be difficult and sometimes incomplete because of the intimate relationships with the vascular axes and the neighboring organs.

The risk of recurrence is rare if the removal has been complete. A case of heterotopic recurrence has been described [15]: appearance of a retroperitoneal schwannoma following removal of a spinal schwannoma. On the other hand, a benign schwannoma degenerates only exceptionally: only one case has been described in which a malignant schwannoma appeared at a distance from an excision of a benign schwannoma [4]. This low risk of transformation and recurrence makes annual postoperative CT surveillance necessary.

Although most schwannomas are benign, malignant forms are frequently associated with Von Recklinghausen syndrome (4% of cases) and other neurofibromatoses [16]. These malignant forms are more frequent in men. Some authors believe that they are in fact neurofibrosarcomas [6]. A history of radiotherapy would be a factor favoring the appearance of malignant schwannomas [17]. The treatment of malignant schwannoma is surgical; these tumors are resistant to chemotherapy and radiotherapy [18]. Metastases are preferentially liver, lung, bone and subcutaneous tissue [19]. Lymphatic dissemination is very rare. Therefore, careful monitoring is suggested in case of retroperitoneal schwannoma removal.

CONCLUSION

Retroperitoneal schwannomas are rare tumors that can present with multiple but non-specific clinical pictures, excision surgery remains the only treatment for this entity, the diagnosis is made by anatomopathological study, even if postoperative recurrences are exceptional radiological surveillance is necessary.

REFERENCES

1. Aubert, J., Debiais, F., & Levillain, P. (2000). Schwannome du nerf obturateur à manifestations urologiques: à propos d'une observation. In *Annales d'urologie* (Vol. 34, No. 1, pp. 58-65).
2. Brady, K. A., McCarron, J. P., Vaughan, E. D., & Javidian, P. (1993). Benign schwannoma of the retroperitoneal space: case report. *The Journal of urology*, 150(1), 179-181.
3. Gupta, T. D., & Brasfield, R. D. (1970). Solitary malignant schwannoma. *Annals of Surgery*, 171(3), 419.
4. Gupta, T. K. D., Brasfield, R. D., Strong, E. W., & Hajdu, S. I. (1969). Benign solitary schwannomas (neurilemmomas). *Cancer*, 24(2), 355-366.
5. Parfitt Jr, H. E., Hammond, M. E., & Middleton Jr, A. W. (1982). Perirenal malignant schwannoma: a case report and review of the literature. *The Journal of urology*, 128(6), 1299-1301.
6. Donnal, J. F., Baker, M. E., Mahony, B. S., & Leight, G. S. (1988). Benign retroperitoneal schwannoma. *Urology*, 31(4), 332-334.
7. Maleux, G., Lambrechts, P., Oyen, R. (1995). Retroperitoneal Schwannoma. *J. Belg. Radiol*, 78, 218-219.
8. Micali, S., Virgili, G., Vespasiani, G., Silecchia, A., D'alessandro, P., & Micali, F. (1997). Benign schwannoma surrounding and obstructing the ureteropelvic junction. *European urology*, 32, 121-123.
9. Weber, O., Zerbib, M., Peyret, C., Desligner, S., & Debre, B. (1993). Schwannome bénin rétro-péritonéal. *Journal d'urologie*, 99(4), 189-191.
10. Kelso, T. B., Ferrari, C. J., & Frassica, F. J. (1993). Sciatica caused by a neurilemoma of the intrapelvic portion of the sciatic nerve. A case report. *JBJS*, 75(4), 603-605.
11. Takatera, H., Takiuchi, H., Namiki, M., Takaha, M., Ohnishi, S., & Sonoda, T. (1986). Retroperitoneal schwannoma. *Urology*, 28(6), 529-531.
12. Rossi, D., Delperio J.R., Jacquemiera J. (1993). Tumeurs rétro-péritonéales primitives, Editions Techniques, *Encycl. Med. Chir (Paris France)*, Néphrologie, Urologie, 18-083-A-10, *Cancérologie*, 60-18-250-A-10, 1993, 10
13. Weiss, S. W., Langloss, J. M., & Enzinger, F. M. (1983). Value of S-100 protein in the diagnosis of soft tissue tumors with particular reference to benign and malignant Schwann cell tumors. *Laboratory investigation; a journal of technical methods and pathology*, 49(3), 299-308.
14. Yamamoto, K., Miyagawa, J. I., Katsura, H., Itoh, N., Hanafusa, T., Kasugai, T., ... & Tarui, S. (1991). Retroperitoneal cellular schwannoma: report of a case diagnosed by the presence of S-100 protein. *Japanese journal of medicine*, 30(5), 487-490.
15. Yamamichi, F., Nomomura, M., Soeda, A. (1999). Retroperitoneal schwannoma: A case report. *Hinyokika Kyo*, 45, 41-43.
16. Jow, W., Satchidanand, S., Spinzazze, E. (1991). Malignant juxtadrenal schwannoma. *Urology*, 4, 383-386.
17. Sordillo, P.P. (1981). Malignant schwannoma: clinical characteristics, survival and response to therapy. *Cancer*, 47, 2503-2506.
18. Zhang, G., Chan, K., Marrivel, C. (1989). Sarcomas of the retroperitoneum and genitourinary tract. *J. Urol*, 141, 1107-1110.
19. Saito, R., Ishizuka, E., Iwasaki, A. (1997). Retroperitoneal malignant schwannoma in the pelvis: a case report. *Hinyokika Kyo*, 43, 25-28.