

Sister Mary Joseph's Nodule: A Rare Cytological Presentation Post Gallbladder Surgery

Dr. Sneha Aditi, MD^{1*}, Dr. Aysha Femy, MD², Dr. Siddhart Bishwas³

¹Senior Resident, Department of Pathology, AIIMS, Patna, Bihar, India

²Pathologist, Kanachur Medical College, Mangalore, India

³Oncopathologist, Yenepoya Medical College, Mangalore, India

DOI: [10.36347/sasjs.2021.v07i06.004](https://doi.org/10.36347/sasjs.2021.v07i06.004)

| Received: 26.04.2021 | Accepted: 05.06.2021 | Published: 08.06.2021

*Corresponding author: Dr. Sneha Aditi

Abstract

Case Report

Umbilicus is a rare focus of cutaneous metastasis. It is called as Sister Mary Joseph's nodule (SMJN), and is associated with critical prognosis. The most frequent primary malignancies are stomach, colon and pancreas in males, ovaries and endometrium in females. Neoplasm of gallbladder with SMJN is a rare presentation. We present a case report of an elderly male, who presented with umbilical metastasis (SMJN) on non-guided fine-needle aspiration cytology (FNAC). On subsequent work-up through previous slides and further radiological studies, this case was later diagnosed as primary gallbladder adenocarcinoma, which is now presenting with multiple liver metastasis and SMJN. This case report suggests the poor prognosis of gallbladder carcinoma and the unusual presentation of SMJN in gallbladder cancer.

Keywords: Sister Mary Joseph's nodule, Gallbladder carcinoma, FNAC, Metastasis, poor prognosis.

Copyright © 2021 The Author(s): This is an open-access article distributed under the terms of the Creative Commons Attribution 4.0 International License (CC BY-NC 4.0) which permits unrestricted use, distribution, and reproduction in any medium for non-commercial use provided the original author and source are credited.

INTRODUCTION

Metastasis to the umbilicus from intra-abdominal malignancies is known as Sister Mary Joseph's Nodule [1]. It is a rare site of skin metastases, which range between 5–9% of all the malignant lesions of inner organs [2]. Neoplasm of gastrointestinal tract (52%), female genital tract/ genitourinary tract (28%) and non specific origin (18-20%) could be a cause of metastasis to the umbilicus. Most of these metastases are adenocarcinoma (75–93%), followed by squamous cell carcinomas and undifferentiated tumor [3].

The umbilical metastasis (SMJN) suggests mostly advanced tumor stages with poor prognosis. The time period between appearance of skin lesions and diagnosis of cancer is 3 months, and the average survival period being 6–10 months [5]. This study presents a report on SMJN, a skin metastasis from gallbladder carcinoma.

MATERIAL AND METHODS CASE REPORT

Forty nine years old male patient underwent surgery for gallbladder removal with gall stone 3 months back, presented to the surgery department Park Hospital Panipat with complaints of pain abdomen and generalized weakness. The gallbladder sample sent for histopathological examination was reported as suspicious of adenocarcinoma due to poor fixation.

Laboratory tests of the patient showed normal Liver function tests except mild increase in alkaline phosphatase (149 IU/L). Tumor markers such as carcino-embryonic antigen (CEA) was high (100 ng/ml) and CA 19.9 was moderately elevated (42.35 u/ml). Radiological investigations revealed hypodense lesions in left lobe of liver suggestive of hypovascular metastasis.

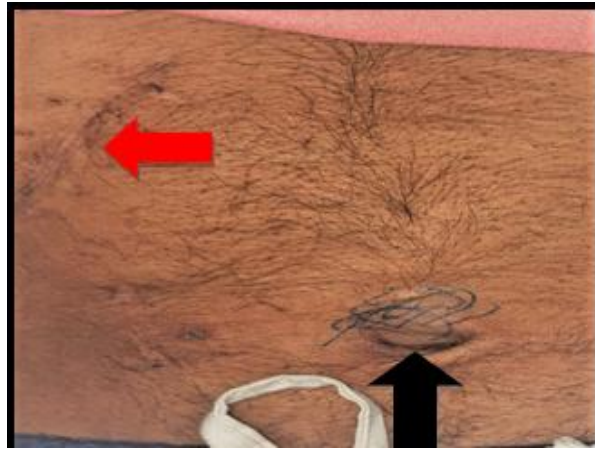

Fig 1: Sister Mary Joseph's nodule measuring 2x1 cm (black arrow) along with Incision scars of Cholecystectomy (red arrow)

Patient gave history of appearance of umbilical nodule one month after the surgery. FNAC was done from the nodule, which showed tumor cells arranged in vague acinar pattern, clusters and were scattered in singles. The cells showed marked anisonucleosis with

hyperchromatic nucleus, inconspicuous nucleoli and scant cytoplasm as shown in fig 2(a, b). Few scattered mitosis and bizarre cells were also seen. And hence was reported as Metastatic Adenocarcinoma. Opinion from other pathologists was taken.

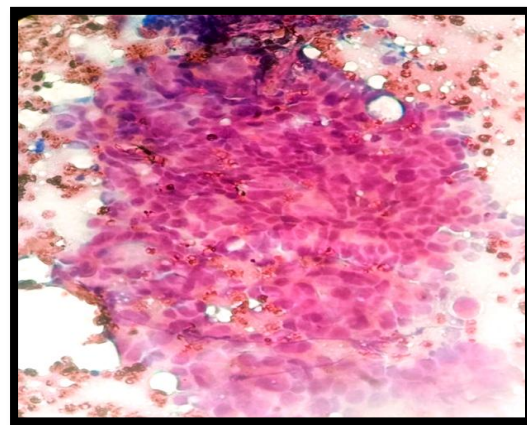
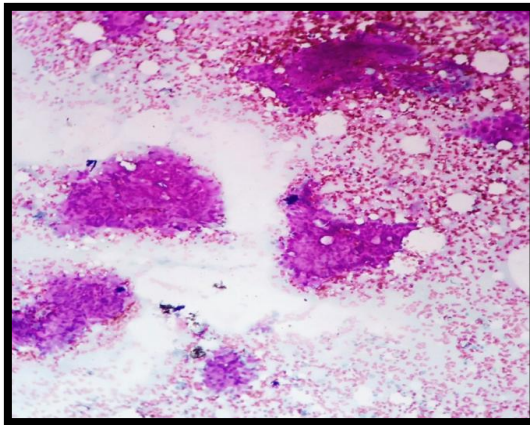


Fig-2 (a, b): Shows clusters and acinar pattern of the tumour cells with hyperchromatic nucleus, inconspicuous nucleoli and scant cytoplasm.

The patient was later started on chemotherapy. However patient died within 2month of treatment.

DISCUSSION

In 1854, first case of umbilical metastasis was documented by Baluff, but was published in 1928 by William James Mayo. It was named after Sister Mary Joseph who was the superintendent nurse as well as surgical assistant of Dr. William Mayo. She noticed the combination of umbilical metastasis and abdominal neoplasms while preparing patients for surgery and informed about this to Dr. Mayo, who published an article about this phenomena in 1928 as “pants button umbilicus” [1].

The Gangetic belt of India is endemic for gallbladder Carcinoma. Only few cases of SMJN have been described in gallbladder carcinoma. The potential mechanism of tumor spread to umbilicus could be through lymphatic channels, vascular route, contiguous extension, or embryologic remnants in the anterior

abdominal wall. It is significant to recognize umbilical metastasis because it suggests inoperability of tumor. Surgery with curative aim is not possible in gallbladder cancers presented with SMJN [1-4].

Clinically, Sister Mary Joseph's nodules have been described as solid, erythematous, firm to hard, cutaneous or subcutaneous nodules with irregular margins located at the umbilicus of size ranging from 0.5 to 2 cm even though nodules measuring up to 10 cm in diameter have been reported. They are habitually slightly tender or painful lesions, having a necrotic or ulcerated surface with concomitant secretion of blood, mucous, serous fluid and/or pus however on our cases patient didn't present with tender nodule.

Primary metastasis from a gallbladder carcinoma to the umbilicus, as in our case, is rare (only 2.4%)³. In addition, secondary metastasis, as implant metastasis, after cholecystectomy is described more

often⁴⁻⁵ suggests the residual tumour leftover due to incomplete surgery.

SUMMARY

Sister Mary Joseph's nodule may occasionally be the primary and just the merely sign of an internal neoplasm and prognosis is mostly poor; diagnosis has to be confirmed in early stages to improve average survival. An elevated index of suspicion should be maintained while dealing with a Sister Mary Joseph's nodule and appropriate evaluations should be performed in order to detect any possible underlying occult carcinoma, even after the organ removal surgery.

REFREANCES

1. Trebing, D., & Goring, H. D. (2004). Die Nabelmetastase Sister Mary Joseph und ihre Zeit. *Der Hautarzt*, 55(2), 186-189.
2. Jha, A., Jha, S., Kumar, R., & Kumar, U. (2017). Sister Mary Joseph's nodule: Two rare cases of inoperable gallbladder cancer. *Indian journal of cancer*, 54(1):29-30
3. Larentzakis, A., Theodorou, D., Fili, K., Manataki, A., Bizimi, V., Tibishrani, M., & Katsaragakis, S. (2008). Sister Mary Joseph's nodule: Three case reports. *Cases Journal*, 1(1), 1-3.
4. Palaniappan, M., Jose, W. M., Mehta, A., Kumar, K., & Pavithran, K. (2010). Umbilical metastasis: a case series of four Sister Joseph nodules from four different visceral malignancies. *Current Oncology*, 17(6), 78-81.
5. Renner, R., & Sticherling, M. (2007). Sister Mary Joseph's nodule as a metastasis of gallbladder carcinoma. *International journal of dermatology*, 46(5), 505-507.