

Prevalence and Distribution of Sesamoid Bones in the Region of the Forefoot among Jordanians

Omar Alajoulin^{1*}¹Orthopedic and Trauma Department- Ankle and Foot Section, Jordanian Royal Medical Services, JordanDOI: [10.36347/sjams.2021.v09i06.016](https://doi.org/10.36347/sjams.2021.v09i06.016)

| Received: 04.05.2021 | Accepted: 09.06.2021 | Published: 15.06.2021

*Corresponding author: Omar Alajoulin

Abstract**Original Research Article**

The sesamoid bones of the forefoot are typically found within the plantar plates of the interphalangeal (IP) and metatarsophalangeal (MTP) joints. Although rare, they are relatively implicated in some pathology including fractures, infections, arthritis, and osteonecrosis. There is an extensive variability in the reported prevalence of sesamoid bones within different populations the aim of this study was to determine the prevalence of sesamoid bones of the forefoot, their distribution and morphological variations in Jordanians according to gender and side using plain radiography. Foot radiographs were obtained from patients referred to the foot and ankle clinic at Jordanian Royal Medical Services. The sesamoids of the first MTP joint were found in all radiographs. Bipartite hallucal sesamoid was found in 3.6%, bipartite medial in 2.0 %, bipartite lateral in 1.3%, and bipartite medial and lateral in 0.3%. None of the radiographs showed a single medial or lateral hallucal sesamoid bone. Sesamoids at the second, fourth, and fifth MTP joints were observed in 1.6%, 0.4%, and 5.6%, respectively. The third MTP sesamoid was not observed in this series. A multipartite MTP sesamoid was observed at the fourth and fifth MTP joints and identified in 3.1 % of the feet. No cases were identified with multipartite sesamoid bones at the second or third MTP joints. Coincidence of sesamoid bones at two MTP joints was also observed. Hallucal IP sesamoid was observed in 1.8% and the IP sesamoids of second, third, fourth, and fifth toes were not observed in this series. A thorough knowledge of normal anatomical variants is essential to avoid unnecessary clinical workup and is implicated in anthropological and forensic studies. Further research may be needed to explore the genetic and/or environmental factors that may be attributed to the variations in the prevalence of sesamoid bones in different populations.

Keywords: Sesamoid bones, Forefoot, Jordanians, Morphology, Interphalangeal joint, Metatarsophalangeal joint.

Copyright © 2021 The Author(s): This is an open-access article distributed under the terms of the Creative Commons Attribution 4.0 International License (CC BY-NC 4.0) which permits unrestricted use, distribution, and reproduction in any medium for non-commercial use provided the original author and source are credited.

INTRODUCTION

The sesamoid bones are osseous variations that are frequently encountered in the region of the foot. They are small, well-corticated structures that could be ovoid or nodular, unilateral or bilateral, unipartite, bipartite or multipartite and may be present near a bone or a joint [1]. Sesamoid bones are completely or partially embedded in the substance of their corresponding tendon and function to alter the direction of muscle pull, diminish friction, and modify pressure [2]. Sesamoid bones develop from their own ossification centers and show a variability in their ossification pattern [3]. They may be partially or fully ossified in some, whilst in others; they may be entirely cartilaginous [4]. This explains the radiographic absence or presence of various sesamoids [2]. Sesamoid bones are thought to arise from an interaction between mechanical and biological factors [5]. Some sesamoid bones are invariably present in all individuals, such as

the patella and the hallucal sesamoids [6]. However, some sesamoid bones vary widely among different ethnic groups and are subject to significant morphological variations.

The sesamoid bones in the region of the foot and ankle are found in the tendons of the flexor hallucis brevis, tibialis anterior, the tibialis posterior, peroneus longus, and the intrinsic tendons of the lesser toes [2].

In the forefoot, they are typically found within the plantar plates of the interphalangeal (IP) and metatarsophalangeal (MTP) joints.

Sesamoid bones in the region of the foot and ankle are generally asymptomatic in most individuals and are detected incidentally by radiological examinations; however, they are increasingly being reported in the literature due to the pain directly related to them or the misinterpretation of them as fractures [1,

7]. Although rare, they are relatively implicated in some pathology including fractures, infections, arthritis, and osteonecrosis [1, 8]. There is an extensive variability in the reported prevalence of sesamoid bones in the region of foot within different ethnic groups and different populations. The aim of this study was to determine the prevalence of sesamoid bones of the forefoot, their distribution and morphological variations in Jordanian subjects according to gender and side using plain radiography.

MATERIALS AND METHODS

A retrospective review of anteroposterior, oblique and/or lateral radiographic views of the feet of 550 adult patients were performed. Foot radiographs were obtained from patients referred to the foot and ankle clinic at Jordanian Royal Medical Services between September 2015 and September 2020. The study was approved by the Institutional Review Board at Jordanian Royal Medical Services.

The inclusion criteria were patients aged 18 years and older and the availability of high-quality radiographs that demonstrated all metatarsal and phalangeal bones of the foot. Data on patient age, gender, and foot laterality (right vs. left) were recorded from hospital records.

STATISTICAL ANALYSIS

GraphPad Prism version 6.04 for Windows (GraphPad Software, La Jolla, CA) was used. The prevalence of different sesamoid bones was compared between genders (male vs. female) and sides (right vs. left) using Fisher's exact test. The significance threshold was set at 0.05.

RESULTS

Radiographic views of 294 right and 256 left feet from 550 adult patients (314 males and 236 females) were included in this study. The mean age (\pm SD) was 37.6 years \pm 15.8 years.

Prevalence and distribution of sesamoid bones were shown in Table 1. No significant differences in the proportion of sesamoid bones were observed between sexes or sides. The sesamoids of the first MTP joint were found in all radiographs (100%). Bipartite hallucal sesamoid was found in 3.6% (20/550), with a bipartite medial hallucal sesamoid bone identified in 2.0% (11/550), a bipartite lateral hallucal sesamoid bone in 1.3% (7/550) and a bipartite medial and lateral hallucal sesamoid bone in 0.3% (2/550) (Figure 1). None of the radiographs showed a single medial or lateral hallucal sesamoid bone.

Sesamoid bones at the MTP joint of the second, fourth, and fifth toes were observed in 1.6% (9/550), 0.4% (4/550), and 5.6% (31/550), respectively.

The MTP sesamoid bone of the third toe was not observed in this series.

A bipartite/tripartite MTP sesamoid bone was identified in 3.1% (17/550). Bipartite and tripartite sesamoid bones of the fifth MTP joint were observed in 2.4% (13/550) and 0.4% (2/550) of the feet, respectively. Bipartite sesamoid bone of the fourth MTP joint was observed in 0.4% (2/550) of the feet. No cases were identified with bipartite/tripartite sesamoid bones at the MTP joint of the second or third toes. Coincidence of sesamoid bones at two MTP joints was observed (Figure 2).

Hallucal IP sesamoid bone was observed in 1.8% (10/550) (Figure 3). The IP sesamoid bones of second, third, fourth, and fifth toes were not observed in this series.

DISCUSSION

The sesamoid bones in the forefoot vary widely in their prevalence and appearance. The prevalence and distribution of sesamoid bones in the current study did not differ greatly from that reported in the literature. We confirmed that the hallucal sesamoid bones at the first MTP joint always exist in the adult foot. This finding is in agreement with the previous reports [6, 9]. However, an absence of hallucal sesamoid bones was identified in 0.04% in a study of Chinese population [10]. The two hallucal sesamoid bones (medial and lateral) of MTP are plantarly located within the tendon of the flexor hallucis brevis [11]. These two sesamoids form portion of the plantar plate and are connected to the plantar aspect of proximal phalanx through plantar plate [12].

In this study, sesamoid bones at the MTP joint of the second, fourth, and fifth toes were observed in 1.6%, 0.4%, and 5.6%, respectively. These prevalence rates among our subjects are slightly higher than that reported in Turkish population [6]. In the latter study, MTP sesamoid bones were seen in the second, third, fourth and fifth toes in 0.4, 0.2, 0.1 and 4.3%, respectively. On the other hand, in a radiographic study of 8,716 Chinese subjects, the prevalence of sesamoid bones at the MTP joint of the second, third, fourth, and fifth toes were 3.08%, 0.39%, 0.69%, and 8.94%, respectively [10]. These prevalence rates are higher than the rates observed in this study. In addition to the interethnic differences, this could be attributed to the large sample size in the later study [10]. However, the MTP sesamoid bone of the third toe was not observed in this series. In a study of Arslan et al. using computed tomography, the rarest sesamoid bone was the MTP sesamoid bone of the third metatarsal bone, with an incidence of 0.7% [9]. In line with our findings, it was reported that the sesamoids of the MTP joints of the lesser toes are more common in the second and fifth toes [5, 13].

The IP sesamoid of the hallux is an anatomical variant with a reported incidence of 2-13% [1]. In our study, the hallucal IP sesamoid was observed in only 2% of the feet. This is in agreement with the prevalence rate reported in the study of Coskun et al. [6]; however, higher prevalence rates of hallucal IP sesamoid were reported by Arslan et al. and Sun et al. (34.6% and 59.22%, respectively) [9, 10]. The high prevalence rate of the hallucal IP sesamoid bone in the study of Arslan et al. could be attributed by the use of computed tomography which is more sensitive than plain radiography in detecting sesamoid bones [9].

The IP sesamoids are rarely associated with pathologies; however, it was reported that the IP sesamoid decreases the range of motion at the first MTP joint, and eventually this may cause hyperextension of the IP joint of the hallux. Due to its location beneath the IP joint and the altered biomechanical force, this may result in a painful hyperkeratotic callous plantar to the joint [1, 4, 14].

Bipartite or multipartite sesamoid bones are normal anatomical variants and result from multiple ossification centers of sesamoid bones. The reported incidence of bipartite sesamoids ranges between 7 -30% [15, 16]. In this study, a bipartite hallucal sesamoid was found in 3.6% and a bipartite/tripartite MTP sesamoid bone was identified in 3.1%. Coskun et al. reported the incidence of the bipartite sesamoid bones as 1.9% [6]. On the other hand, a high prevalence rate of 89.8% for the bipartite hallucal sesamoids was reported by Arslan et al. [9]. In addition, in the computed tomographic study of Arslan et al., bipartite and tripartite sesamoid

bones of the fifth MTP joint were observed in 3.19% and 0.12% of the feet, respectively and a bipartite sesamoid bone of the fourth MTP joint was observed in 0.12% [9]. In agreement with our findings, no case of a tripartite sesamoid bone of the fourth MTP was observed in their study. In this study, bipartite and tripartite sesamoid bones of the fifth MTP joint were observed in 2.4% and 0.4% of the feet, respectively and a bipartite sesamoid bone of the fourth MTP joint was observed in 0.4%.

The large differences in the prevalence of sesamoid bones in the forefoot as cited in different reported surveys may be attributed to several factors such as the interethnic differences, intergenetic factors and mechanical stresses [17, 18]. Further research may be needed to explore the genetic and/or environmental factors that may be attributed to the variations in the prevalence of sesamoid bones in different populations.

CONCLUSION

This anatomical study is the first to describe the prevalence, distribution and morphological variations of sesamoid bones of the forefoot in a Jordanian population. Although sesamoid bones are rarely associated with painful syndromes, this anatomical study might be helpful to assist the clinician in recognizing the normal variants and the pathologies related to them. A thorough knowledge of normal anatomical variants is essential to avoid unnecessary clinical workup and is implicated in anthropological and forensic studies.

Table-1: Prevalence and Distribution of Sesamoid Bones in Jordanians

Site of sesamoid	Incidence (%) N=550	Male N=314	Female N=236	Right N=294	Left N=256
IP; first	10 (1.8)	6 (1.9)	4 (1.7)	7 (2.4)	3 (1.2)
P value		1.0 ^{ns}		0.351 ^{ns}	
MTP; first	550 (100.0)	314 (100.0)	236 (100.0)	294 (100.0)	256 (100.0)
MTP; second	9 (1.6)	6 (1.9)	3 (1.3)	4 (1.4)	5 (1.9)
P value		0.739 ^{ns}		0.739 ^{ns}	
MTP; third	0 (0)	0 (0)	0 (0)	0 (0)	0 (0)
MTP; fourth	2 (0.4)	2 (0.6)	0 (0)	0 (0)	2 (0.8)
P value		0.509 ^{ns}		0.216 ^{ns}	
MTP; fifth	31 (5.6)	20 (6.4)	11 (4.7)	18 (6.1)	13 (5.1)
P value		0.457 ^{ns}		0.712 ^{ns}	
Fisher Exact Test ^{ns} not significant					

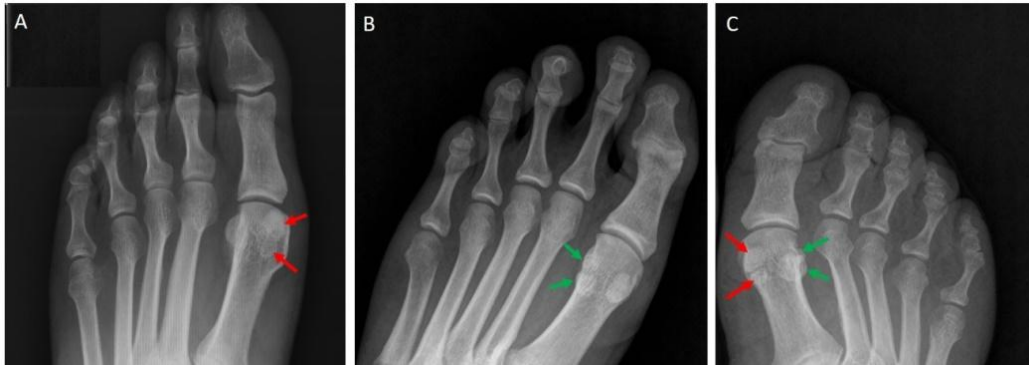

Fig-1: AP radiographs showing **A:** bipartite medial hallucal sesamoid (red arrows) in a 29-year-old female, **B:** bipartite lateral hallucal sesamoid (red arrows) in a 49-year-old male, and **C:** bipartite medial and lateral hallucal sesamoids (red and green arrows) in a 61-year-old female

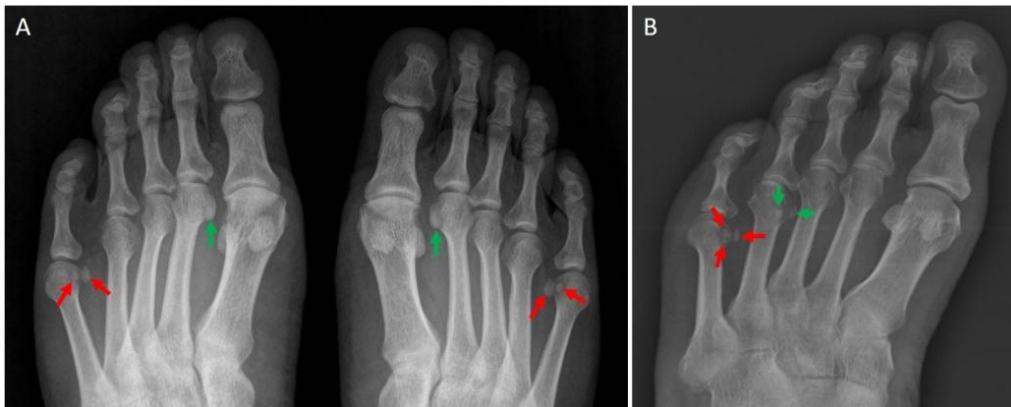


Fig-2: AP radiographs showing **a:** bilateral bipartite sesamoid bone of the fifth MTP joint (red arrows) and bilateral unipartite sesamoid bone of the second MTP joint (green arrows) in a 46-year-old male, **B:** tripartite sesamoid bone of the fifth MTP joint (red arrows) and bipartite sesamoid bone of the fourth MTP joint (green arrows) in a 50-year-old female

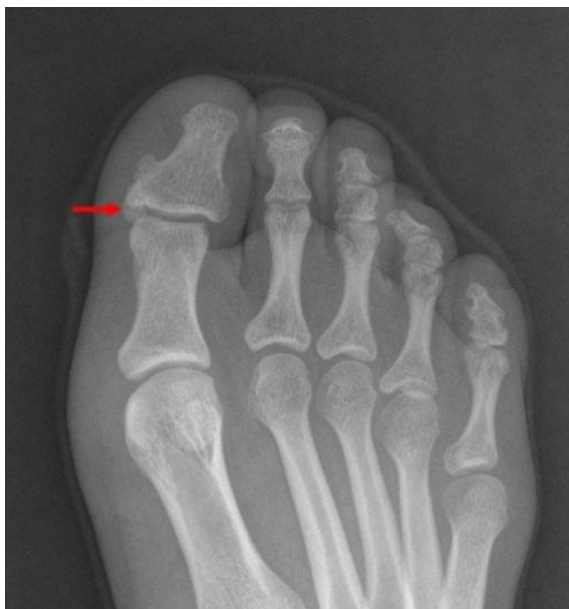

Fig-3: AP radiographs showing hallucal sesamoid bone in a 32-year-old female (red arrow)

REFERENCES

- Nwawka, O. K., Hayashi, D., Diaz, L. E., Goud, A. R., Arndt, W. F., Roemer, F. W., ... & Guermazi, A. (2013). Sesamoids and accessory ossicles of the foot: anatomical variability and related pathology. *Insights into imaging*, 4(5), 581-593.
- Sanders, R. W., & Clare, M. P. (2007). *Sesamoids and Accessory Bones of the Foot: Surgery of the Foot and Ankle*.
- Ogden, J. A. (1984). Radiology of postnatal skeletal development. X. Patella and tibial tuberosity. *Skeletal radiology*, 11(4), 246-257.
- Roukis, T. S., & Hurlless, J. S. (1996). The hallucal interphalangeal sesamoid. *The Journal of foot and ankle surgery*, 35(4), 303-308.
- Goldberg, I., & Nathan, H. (1987). Anatomy and pathology of the sesamoid bones. *International orthopaedics*, 11(2), 141-147.
- Coskun, N., Yuksel, M., Cevener, M., Arican, R. Y., Ozdemir, H., Bircan, O., ... & Sindel, M. (2009). Incidence of accessory ossicles and sesamoid bones in the feet: a radiographic study of the Turkish subjects. *Surgical and radiologic anatomy*, 31(1), 19-24.
- Mellado, J. M., Ramos, A., Salvadó, E., Camins, A., Danús, M., & Saurí, A. (2003). Accessory ossicles and sesamoid bones of the ankle and foot: imaging findings, clinical significance and differential diagnosis. *European radiology*, 13(6), L164-L177.
- Yammine, K. (2015). The sesamoids of the feet in humans: a systematic review and meta-

- analysis. *Anatomical science international*, 90(3), 144-160.
9. Arslan, S., Bakdik, S., Oncu, F., Karahan, A. Y., Durmaz, M. S., Ozen, K. E., & Cicekbasi, A. E. (2018). Incidence and anatomical variability of accessory and sesamoid bones of the foot. *Annals of Medical Research*, 25(3), 420-25.
 10. Sun, T., Wang, L., Zhao, H., Wu, W., & Hu, W. (2016). Prevalence, morphological variation and ossification of sesamoid bones of the forefoot: a retrospective radiographic study of 8,716 Chinese subjects. *Journal of clinical and translational research*, 2(3), 91.
 11. Sims, A. L., & Kurup, H. V. (2014). Painful sesamoid of the great toe. *World journal of orthopedics*, 5(2), 146.
 12. Deland, J. T., Lee, K. T., Sobel, M., & DiCarlo, E. F. (1995). Anatomy of the plantar plate and its attachments in the lesser metatarsal phalangeal joint. *Foot & ankle international*, 16(8), 480-486.
 13. Le Minor, J. M. (1988). The ventral metacarpo-and metatarso-phalangeal sesamoid bones: comparative anatomy and evolutionary aspects. *Gegenbaurs Morphologisches Jahrbuch*, 134(5), 693-731.
 14. Kumar, S., Kadavigere, R., Puppala, R., Ayachit, A., & Singh, R. (2015). Subhallucal interphalangeal sesamoiditis: a rare cause of chronic great toe pain. *Journal of clinical and diagnostic research: JCDR*, 9(5), TD01.
 15. Frankel, J. P., & Harrington, J. (1990). Symptomatic bipartite sesamoids. *The Journal of foot surgery*, 29(4), 318-323.
 16. Munuera, P. V., Domínguez, G., Reina, M., & Trujillo, P. (2007). Bipartite hallucal sesamoid bones: relationship with hallux valgus and metatarsal index. *Skeletal radiology*, 36(11), 1043-1050.
 17. Bizarro, A. H. (1921). On sesamoid and supernumerary bones of the limbs. *Journal of Anatomy*, 55(Pt 4), 256.
 18. Le Minor, J. M. (1987). Comparative anatomy and significance of the sesamoid bone of the peroneus longus muscle (os peroneum). *Journal of anatomy*, 151, 85.