

Original Research Article

Comparative Evaluation of Peribulbar Anaesthesia and Sub-Tenon Anaesthesia for Manual Small Incision Cataract Surgery - A clinical study

Dr. Poonam Singh¹, Prof. Dr. Ashok Jadon², Dr. SP Jakhanwal³

¹Associate Specialist, Department of Ophthalmology, Tata Main Hospital, Jamshedpur, India

²Chief Consultant and HOD Anaesthesia, Tata Motors Hospital, Jamshedpur, India

³Senior Consultant and HOD, Department of Ophthalmology, Tata Main Hospital, Jamshedpur, India

*Corresponding author

Prof. Dr. Ashok Jadon

Email: jadona@rediffmail.com

Abstract: Peribulbar anaesthesia (PBA) is commonly used technique for Manual small incision cataract surgery (MICS) however, feared with complications. Sub-Tenon anaesthesia (STA) is relatively new technique with better safety profile however, requires supplementary injections due to lesser akinesia. We compared both the technique to assess level of akinesia, requirement of supplementary injections, pain during surgery, complications and patient's satisfaction. Two groups of 50 patients each were given either PBA or STA at random. Supplementary injections were given after 10 minutes if adequate akinesia did not occur. Data was collected and analysed for akinesia, number of supplementary injections in each group, pain during surgery, chemosis and sub-conjunctival hemorrhage and patient's satisfaction. Complete akinesia occurred in 86% in PBA group compared to 68% that in the STA group $p=0.033$ (OR=2.8, CI95% (1.42-5.84)). Number of supplementary injections were 24% in STA group and 6% in PBA group ($p=0.001$) (OR=0.238, 95%CI (0.09-0.58)). Seventy eight percent of PBA group and 62% of STA group experienced no pain during the operation ($p=0.014$) (OR=2.17, 95% CI (1.16-4.04)). Subconjunctival hemorrhage in the PBA group (32%), which involved only one quadrant of ocular surface as compared to the STA group (50%) ($p=0.01$) (OR= 0.47, 95%CI (0.26-0.83)). Chemosis in one quadrant was less in PBA group (18%) as compared to (32%) STA group ($p=0.023$) (OR=0.46, 95%CI (0.24-0.9)) (Table 5). There was no incidence of retro bulbar hemorrhage or eye perforation in both groups. Sixty percent patients in STA group were satisfied or highly satisfied (Likert score 6-7) compared to 42% in PBA group ($P=0.01$). Sub-Tenon anaesthesia during manual small incision cataract surgery provided moderate akinesia and good analgesia. Satisfaction was high among sub-Tenon group patients. Sub-Tenon anaesthesia can be a safe and effective alternative to peribulbar anaesthesia in manual small incision cataract surgery.

Keywords: Anaesthesia; Peribulbar Anaesthesia, Sub-Tenon Anaesthesia, Manual Small Incision Cataract Surgery, Likert Scale.

INTRODUCTION

Akinesia and analgesia during intra-ocular surgery are prerequisites for good anaesthesia. It provides comfortable environment for the patient and surgeon during surgery and also helps in quick recovery of functions without added risks. Many techniques from era of retro-bulbar anaesthesia to more recent topical anaesthesia have been tried to achieve this goal (Figure-1). [1]

In current practice, peri-bulbar anaesthesia (PBA) and sub-Tenon's anaesthesia (STA) are two commonly used techniques for intraocular surgeries. Peribulbar anaesthesia was developed as a potentially safer option. However, it has a slower onset of akinesia, requires larger volume of anaesthetic agent and higher rate of supplementation [2-6]. Serious complications such as retrobulbar haemorrhage, globe perforation, and brainstem injection have also been reported following

conventional peribulbar injections [7-8]. To avoid these complications, needle-free procedures such as sub-Tenon and topical as well as topical with intracameral anaesthesia were developed.

Various studies support STA as a safe and efficient technique. Some of its merits include ease of administration, preservation of consciousness, good postoperative analgesia, reduced stress response, early mobilization, and discharge of patients as well as minimal respiratory and cardiovascular systems complications [9-12]. However, single-injection peribulbar anaesthesia technique described by Rizzo *et al.* [13] is also simple and easy-to-perform with all the advantages of good quality anaesthesia. Therefore, we conducted a study at our institute to compare both the technique in regards to quality and safety of individual technique.

Aims and Objective

This study aimed to compare the efficacy of the PBA technique described by Rizzo *et al.* [13] with that of STA for cataract extraction in terms of akinesia (as a primary end point), analgesia, lid movements and incidence of complications like sub-conjunctival haemorrhage and chemosis, as well as patient and satisfaction (as secondary end points).

METHOD

With institutional and ethical approval and after taking written informed consent, 100 patients with senile cataract undergoing Manual Small Incision Cataract Surgery (M-SICS) were selected and included in surgery in prospective double-blinded, randomized study.

In peribulbar Anaesthesia, one drop of topical anaesthetic (Proparacaine 0.5% eye drops) was put 2 times at interval of 2 minutes. Then 5ml mixture of local anaesthetic (3 ml of 2% xylocaine with 50 international units of hyaluronidase and 2 ml of 0.5% Bupivacaine) was taken and single injection was given with 24G needle inferiorly at the junction of the outer one third and inner two third of lid. Lid compression was done for 5 minutes and effect was assessed. In cases of inadequate block another 3 ml mixture of similar drug was repeated in same quadrant.

In Subtenon anaesthesia also, topical anaesthetic drops (Proparacaine 0.5%) was applied one drop twice at 2 minutes' interval. A lid speculum was placed and conjunctiva was cleaned with 4% (half strength) povidone iodine channel just past the equator of the globe to the posterior sub-Tenon's space. Then fused conjunctiva and anterior Tenon's capsule was picked up at an infero-nasal point 7–10 mm from the limbus, midway between the insertions of the medial and inferior rectus muscle. A small cut was made and the sub-Tenon's space was accessed using the closed blunt Westcott scissors. A blunt-tipped cannula was then inserted into the posterior sub-Tenon's space and 3- 4 mL of local anaesthetic drug (similar to used in peribulbar block) was introduced. Gentle constant digital pressure was applied for 2–3 minutes over the closed lids with two fingers, one of which was over the point where the conjunctival cut was made.

Patients who were one eyed, having traumatic, congenital or lens Induced cataracts were excluded from study. Patients with any contraindications for regional anaesthesia, such as clotting abnormalities, impaired mental status, or allergy to the study drugs were also excluded from the study.

The study was conducted at an industrial referral hospital from September 2016 to February 2017. Patients were randomly allocated in one of the two groups to receive either the single-injection peribulbar anaesthesia (PBA group, n = 50) or sub-

Tenon's anaesthesia (STA group, n = 50) by the block randomization method.

All measures were assessed by an observer who was blinded to the aim of the study. Globe akinesia was evaluated in the 4 quadrants using a 4-point scoring system where grading was as follows:

Grade 0 - No Movement, Grade 1 – Flutter, Grade 2 - Partial movement and Grade 3- Full movement.

In case motor blockade was inadequate even after 10 minutes of block, supplementary anaesthesia (3 mL) was injected into the involved quadrant in case of PBA group and 2 mL in STA group (anaesthetic solution was injected through the same conjunctival incision). Reassessments were done 5 minutes later. Assessment of the incidence of chemosis and sub-conjunctival haemorrhage (SCH) was done and graded as:

Grade 0- No Chemosis or sub-conjunctival haemorrhage

Grade 1- involvement in 1 quadrant. Grade 2- Involvement in 2 quadrants. Grade 3- Involvement in 3 quadrants. Grade 4-Involvement in all quadrants

The patients were asked immediately after the end of surgery to assess the degree of pain and discomfort experienced during the operation. Pain and discomfort was assessed by Numerical rating score (NRS) on scale of 0-4 where, score 0- No pain no sensation, score 1-sensation but no pain, score 2-slight pain, score 3-Moderate pain and score 4- Intense pain.

Patients were asked on first postoperative day to answer the question 'How would you rate your satisfaction with the regional block?' using a 7-point Likert-like verbal rating scale (Figure 2).

MedCalc® computer software version 17.4 was used for Statistical analysis. Parametric data were compared by chi square test and nonparametric data was analysed by Mann–Whitney U test. Odds ratio (OR) were calculated at 95% confidence interval and values <.05 were taken significant.

RESULTS

The two groups were comparable with respect to age, sex and duration of surgery (Table 1). The percentage of patients who developed complete akinesia 10 minutes after the injection of local anaesthetic were 86% in PBA group compared to 68% that in the STA group p=0.033(OR=2.8, CI95% (1.42-5.84) (Figure 3). Number of supplementary injections were 24% in STA group and 6% in PBA group (p= 0.001) (OR=0.238, 95%CI (0.09-0.58) (Table-2).

Pain was determined using 4 points scale where 78% of PBA group and 62% of STA group experienced no pain during the operation ($p=0.014$) ($OR=2.17, 95\% CI (1.16-4.04)$) (Figure 4).

There was significantly lower incidence of Subconjunctival Haemorrhage in the PBA group (32%), which involved only one quadrant of ocular surface as compared to the STA group (50%) ($p=0.01$) ($OR= 0.47, 95\% CI (0.26-0.83)$) (Figure 5).

Chemosis in one quadrant was less in PBA group (18%) as compared to (32%) STA group ($p=0.023$) ($OR=0.46, 95\% CI (0.24-0.9)$) (Figure 6). There was no incidence of retro bulbar haemorrhage or eye perforation in both groups.

Patient satisfaction was measured on Likert scale (Figure 2) where 60% patients in STA group were satisfied or highly satisfied (Likert score 6-7) compared to 42% in PBA group ($P=0.01$) (Figure 7).

Table-1: Demographic data of patients in peribulbar and Sub-Tenon group of patients

	Peribulbar Group	Sub-Tenon Group	p value*
Number of Patients (n)	50	50	-
Age Mean (SD)	60.7± 7.8	61.5± 7.6	0.60
Male: Female	28:22	30:20	0.685

Table-2: Duration of surgery and number of supplementary injections in peribulbar and Sub-Tenon group of patients

	Peribulbar Group	Sub-Tenon Group	p value*
Duration of Surgery in minutes, Mean (SD)	11±2.65	12±3.69	0.12
Supplementary injections	6%	24%	($p= 0.001$) **

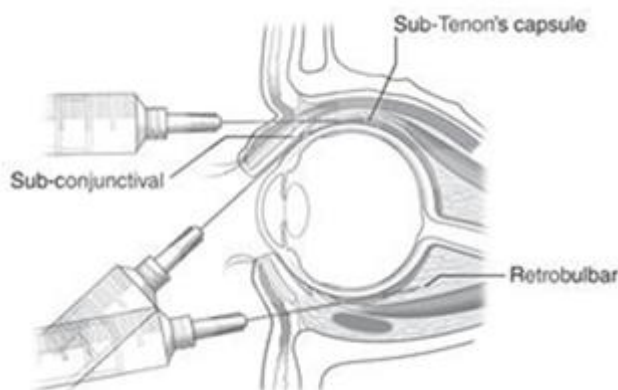


Fig-1: Various approaches for ocular anaesthesia

1	2	3	4	5	6	7
Extremely dissatisfied	Dissatisfied	Somewhat dissatisfied	Undecided	Somewhat satisfied	Satisfied	Extremely satisfied

Fig-2: Likert Scale to assess patient's satisfaction after cataract surgery

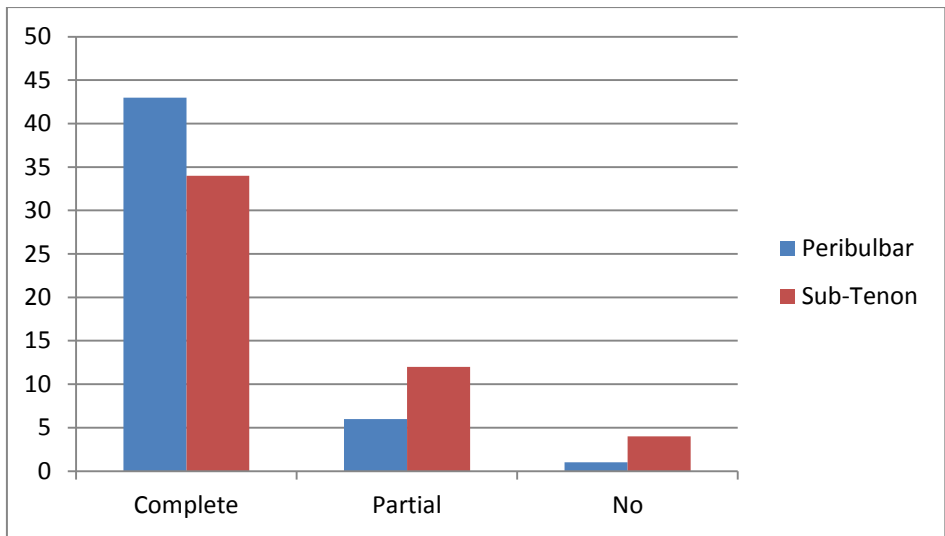


Fig-3: Comparison of Globe Akinesia in peribulbar and Sub-Tenon anaesthesia

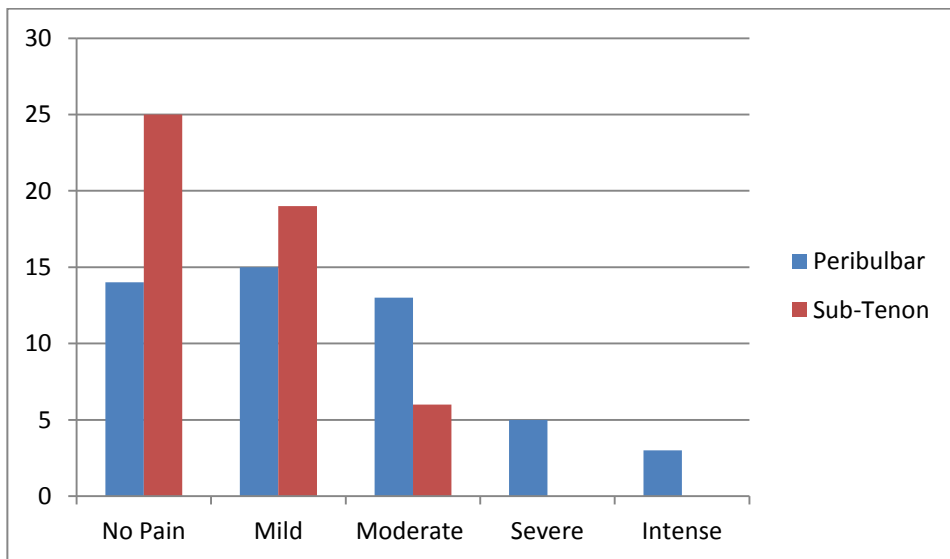


Fig-4: Comparison of Pain score between Peribulbar and Sub-Tenon groups

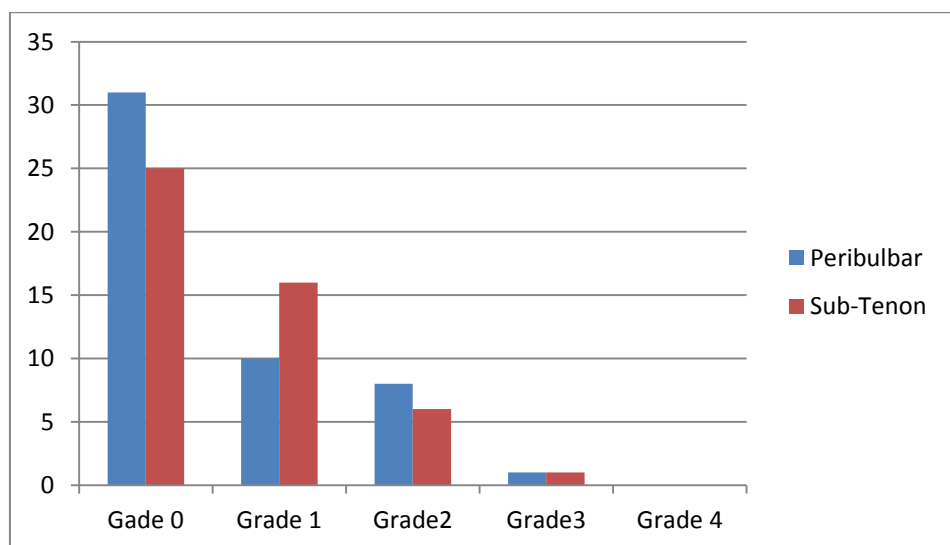


Fig-5: Grades of Sub-conjunctival haemorrhage in patients of Peribulbar and Sub-Tenon groups

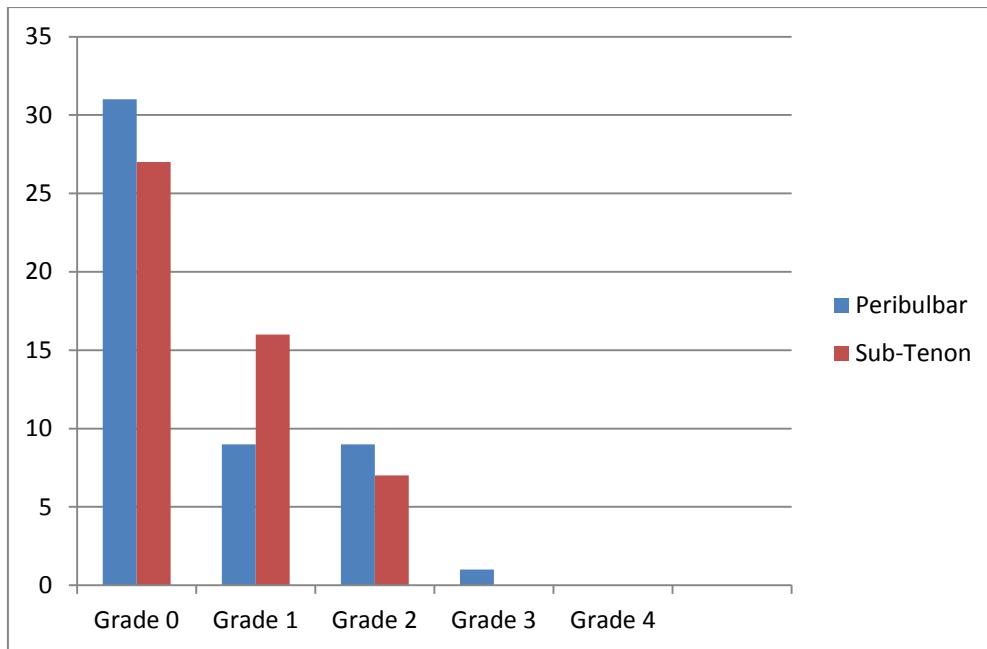


Fig-6: Various grades of Chemosis in Peribulbar and Sub-Tenon group patients

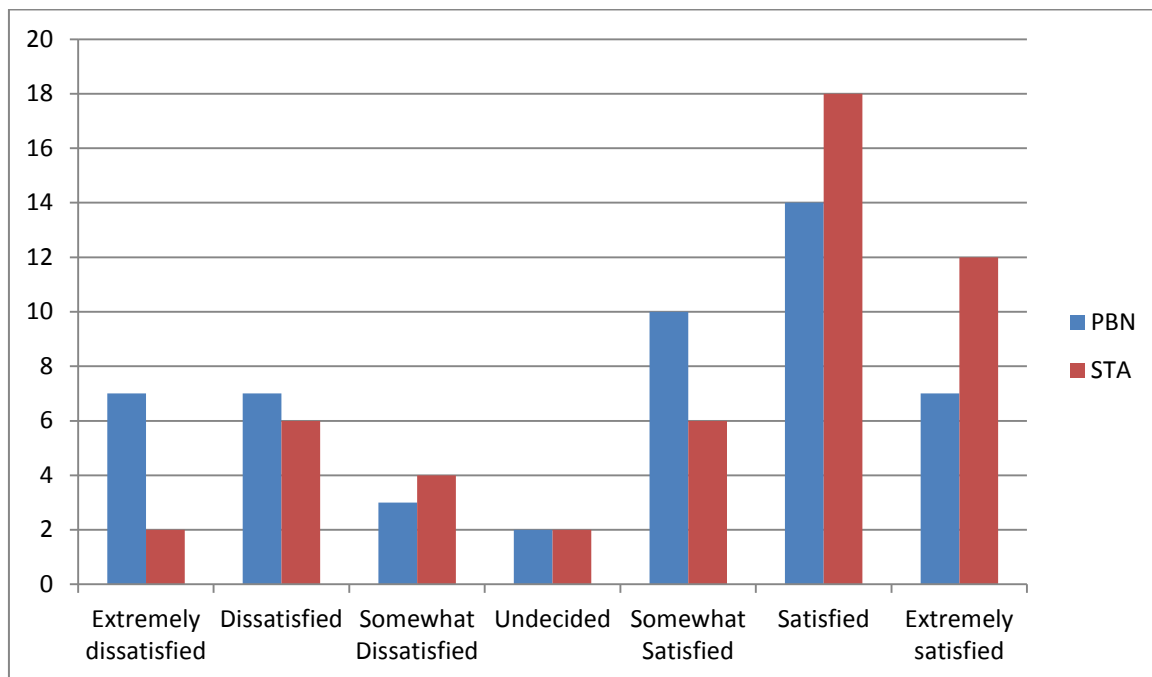


Fig-7: Level of Satisfaction among peribulbar (PBA) and Sub-Tenon (STA) group

DISCUSSION

Sub-Tenon's anaesthesia (STA) was described in 1992 by Stevens is a milestone technique which is associated with good analgesia, moderate amount of akinesia and it is patient friendly with less chances of complications (Figure 1).

Peribulbar block [14] which provides optimal conditions is another popular choice for patients undergoing cataract surgery. The main drawback of peribulbar block is potential risk of optic nerve injury, retro-bulbar haemorrhage and globe perforation due to use of long needles (1-1.25 inches), more so in, patients

with shallow orbits [15,16]. However, small needle and low volume local anaesthetic technique of Razo *et al.* [13] is quite safe and effective alternative.

An ideal eye block would provide globe analgesia, akinesia, and absence of pressure on the globe, minimal injectate volume, without serious complications [17]. Both the techniques are effective to provide akinesia however, we observed that PBA is superior to STA and required less number of supplementary injections (Table-2). We also observed complete Akinesia in (86%) of patients in Peribulbar group as compared to (68%) of Sub-Tenon group

(Figure 3). Absolute akinesia is ideal however; if pain relief is excellent then patient's cooperation can be achieved to compensate for moderate akinesia. Opposite is not true and therefore even with moderate akinesia in STA group we did not face any practical difficulty vis-a-vis patients were more satisfied.

We did not observe any serious complications with PBA as we used small needle however, potential risk of globe injury does exist. The sub-Tenon's approach to ocular local anaesthesia differs from peribulbar methods in that, it is performed using blunt instrumentation and direct visualisation and therefore relatively safer [18].

Our observations with regard to intraoperative pain are consistent with studies done by Parkar Tasneem *et al.* [19] who found that Subtenon was superior to Peribulbar anaesthesia in controlling pain. In our study (50%) patients in Subtenon group had no pain and none had intense pain. In Peribulbar group (28%) had no pain however, intense pain was reported by 6% patients.

Chemosis was significantly more in STA group ($P < .01$) however, did not cause any operative difficulty. It is one of the recognised side effects of sub-Tenon's and more practice is needed to deliver the anaesthetic solution to posterior sub-Tenon's space and not to the anterior sub-conjunctival space [20].

In our study (50%) patients in STA group had sub-conjunctival haemorrhage involving 1 or 3 quadrants as compared to 32% in peribulbar group. Our observations are in agreement with Budd *et al.* [20] and Parkar *et al.* [21]. The frequency of SCH during STA injections is often a consequence of the procedure and has been reported to occur in up to 56% of cases [22]. The most likely source of bleeding is the conjunctival vessels, which get injured, cut or sheared during the process of creating a conjunctival entry site for the cannula to pass into the sub-Tenon's space. In our study, statistical difference was found in degree of sub-conjunctival haemorrhage, and Chemosis between PBA and STA groups however, there was no postoperative morbidity in terms of pain or difficulty in vision. Moreover, patient's satisfaction was significantly more with Sub-Tenon technique as compared to Peribulbar technique ($p = 0.01$). In camp situation peribulbar anaesthesia is an acceptable technique [23, 24] however, for hospital based practice studies [9-12] support the view that, STA is more acceptable to patients as it causes less discomfort.

CONCLUSION

We conclude that, Sub-Tenon technique of administration of anaesthesia during manual small incision cataract surgery provided moderate akinesia and good analgesia. Patient's satisfaction was high among sub-Tenon group patients. Sub-Tenon

anaesthesia can be a safe and effective alternative to peribulbar anaesthesia in manual small incision cataract surgery

REFERENCES

1. Bellucci R. Anaesthesia for cataract surgery. *Curr Opin Ophthalmol.* 1999;10:36-41.
2. Troll GF. Regional ophthalmic anaesthesia: Safe techniques and avoidance of complications. *J Clin Anesth.* 1995;7:163-72.
3. Ripart J, Lefrant JY, de La Coussaye JE, Prat-Pradal D, Vivien B, Eledjam JJ. Peribulbar versus retrobulbar anaesthesia for ophthalmic surgery: An anatomical comparison of extraconal and intraconal injections. *Anesthesiology.* 2001;94:56-62.
4. Rozentsveig V, Yagev R, Weckler N, Gurman G, Lifshitz T. Respiratory arrest and convulsions after peribulbar anaesthesia. *J Cataract Refract Surg.* 2001;27:960-2.
5. Wadood AC, Dhillon B, Singh J. Inadvertent ocular perforation and intravitreal injection of an anaesthetic agent during retrobulbar injection. *J Cataract Refract Surg.* 2002;28:562-5.
6. Riad W, Akbar F. Ophthalmic regional blockade complication rate: A single center audit of 33,363 ophthalmic operations. *J Clin Anesth.* 2012;24:193-5.
7. Gillow JT, Aggarwal RK, Kirkby GR. A survey of ocular perforation during ophthalmic local anaesthesia in the United Kingdom. *Eye* 1996;10:537-8.
8. Gillow JT, Aggarwal RK, Kirkby GR. Ocular perforation during peribulbar anaesthesia. *Eye* 1996;10:533-6.
9. Lee A, Wildsmith JA. Local anaesthetic techniques. In: Aitkenhead AR, Smith G, editors. *Textbook of Anaesthesia.* 3rd ed. London: Churchill Livingstone; 1996. pp. 445-69.
10. Barker JP, Vafidis GC, Robinson PN, Burrin JM, Hall GM. The metabolic and hormonal response to cataract surgery. A comparison between retrobulbar and peribulbar blockade. *Anaesthesia.* 1993;48:488-91.
11. McLure HA, Rubin AP. Local anaesthesia for ophthalmic surgery. *Curr Anaesth Crit Care.* 1999;10:40-7.
12. Biscop J. Advantages of regional anaesthesia over general anaesthesia. In: Hoerster W, Kreusscher H, Niesel HC, Zenz M, editors; Dekornfeld TJ, translator. *Regional Anaesthesia.* 2nd ed. London: Mosby Year Book; 1990. pp. 31-45.
13. Rizzo L, Marini M, Rosati C, Calamai I, Nesi M, Salvini R, Mazzini C, Campana F, Brizzi E. Peribulbar anaesthesia: a percutaneous single injection technique with a small volume of anaesthetic. *Anesthesia & Analgesia.* 2005 Jan 1;100(1):94-6.

14. Bedi A, Carabine U. Peribulbar anaesthesia: A double-blind comparison of three local anaesthetic solutions. *Anaesthesia*. 1999;54:67–71.
15. Karampatakis V, Natsis K, Gigis P, Stangos NT. The risk of optic nerve injury in retrobulbar anaesthesia: A comparative study of 35 and 40 mm retrobulbar needles in 12 cadavers. *Eur J Ophthalmol*. 1998;8:184–7.
16. Katsev DA, Drews RC, Rose BT. An anatomic study of retrobulbar needle path length. *Ophthalmology*. 1989;8:1221–4.
17. Guise , Philip A: Sub-Tenon's Anaesthesia: A Prospective Study of 6,000 Blocks. *Anesthesiology* 2003, 98 (4): 964-8.
18. Verghese I, Sivaraj R, Lai YK: The effectiveness of sub-Tenon's infiltration of local anaesthesia for cataract surgery. *Aust N Z J Ophthalmol* 1996, 24 (2): 117-120.
19. Parkar T, Gogate P, Deshpande M, Adenwala A, Maske A, Verappa K. Comparison of subtenon anaesthesia with peribulbar anaesthesia for manual small incision cataract surgery. *Indian J Ophthalmol* 2005;53:255–9.
20. Budd JM, Brown JP, Thomas J, Hardwick M, McDonald P, Barber K. A comparison of sub-Tenon's with peribulbar anaesthesia in patients undergoing sequential bilateral cataract surgery. *Anaesthesia* 2009;64:19–22.
21. Parkar T, Gogate P, Deshpande M, Adenwala A, Maske A, Verappa K. Comparison of subtenon anaesthesia with peribulbar anaesthesia for manual small incision cataract surgery. *Indian J Ophthalmol*. 2005;53:255–9.
22. Guise PA. Sub-Tenon anaesthesia. *Anesthesiology*. 2003;98:964–8.
23. Pant M, Jadon A, Singh GB, Singh BP. Evaluation of a low volume peribulbar block in eye camp surgery. *journal of Anaesthesiology Clinical Pharmacology* 2000; 16(1): 65-8.
24. P Singh, A Jadon, B Singh. Single Injection versus Double Injection Peribulbar Anaesthesia in Eye Camp Surgery: a Comparative evaluation of Akinesia and Anaesthesia. *The Internet Journal of Anesthesiology* 2007; 18: 2.