

Ovarian Ectopic Pregnancy – A Case Report of Two Cases

Dr. Parul Garg MD^{1*}, Dr. Vaneet Kaur MD², Dr. Navjot Kaur MBBS³, Dr. Shilpa Pal MBBS⁴, Dr. Bikramjit Singh MBBS⁵

¹Assistant Professor, ²Associate Professor, ³⁻⁵Junior Resident, Department of Pathology, GGS Medical College -Faridkot, Punjab, India

DOI: [10.36347/sjmcr.2021.v09i06.013](https://doi.org/10.36347/sjmcr.2021.v09i06.013)

| Received: 05.05.2021 | Accepted: 11.06.2021 | Published: 20.06.2021

*Corresponding author: Dr. Parul Garg

Abstract

Case Report

Primary ovarian pregnancy occurs very rarely and usually in young women using intra uterine device. We present two case reports where young primigravida females presented with pain abdomen and were diagnosed as ectopic pregnancy on ultrasonography and confirmed on histopathology examination as Ovarian ectopic after partial oophorectomy.

Keyword: Ectopic Pregnancy, primigravida, oophorectomy.

Copyright © 2021 The Author(s): This is an open-access article distributed under the terms of the Creative Commons Attribution 4.0 International License (CC BY-NC 4.0) which permits unrestricted use, distribution, and reproduction in any medium for non-commercial use provided the original author and source are credited.

INTRODUCTION

Implantation of embryo outside the normal intrauterine cavity, it is known as an ectopic pregnancy (EP). When such ectopic implantation occurs in an ovary, it is known as an ovarian pregnancy (OP). The fertilized ovum is thus retained inside the ovary. Primary ovarian pregnancy is very rare entity, the diagnosis of which continues to challenge the practicing clinicians.

CASE REPORTS

Case 1: A 26-year-old primigravida presented to OPD with lower abdominal pain for 1 week with a history of 5 weeks amenorrhea. Her previous menstrual cycle was regular: average flow and no dysmenorrhea. On examination, no pallor, her vitals were stable. Her systemic examination was within normal limits. On investigation her urine pregnancy test was positive, Hb% was 9.4 gm%, Total leucocyte count was 10,800/cu mm, platelet count was 2.6 lakh and the blood group was a positive. Bhcg level was raised. No history of any medical illness, abdominal surgery, pelvic inflammatory disease, chronic disease noted. Transvaginal ultrasonography assessment showed the presence of a right adnexal complex mass with fetal pole and heart rate, free fluid in the pouch of Douglas, and increased vascular blood flow activity. Estimated gestational age was 6 weeks. The uterus showed a normal outline with slightly thickened endometrial line and no intrauterine sac. At this stage, results were in favor of ectopic pregnancy. Therefore, right salpingo-oophorectomy was performed. On laparotomy, the right

fallopian tube appeared normal, but the right ovary was enlarged with hemorrhagic area. The left adnexa appeared normal.

Right Salpingo-oophorectomy was done and sent to pathology department. On macroscopic examination, the ovary was enlarged received in multiple pieces collectively measuring 6×4×2cm. Cut section was grey white along with grey tan hemorrhagic areas seen. Fallopian tube measures 5cm in length and cut section was unremarkable. Histopathological examination show mainly large areas of hemorrhages along with occasional chorionic villi embedded in the ovarian stroma (Figure: 1). Therefore, diagnosis of primary ovarian ectopic pregnancy was confirmed.

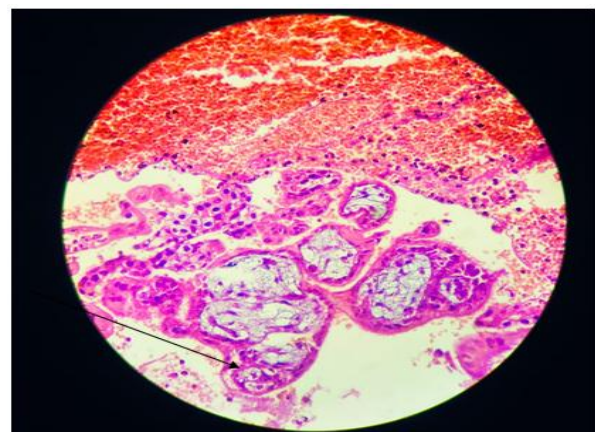


Fig-1: High power view shows: Chorionic villi (Arrow) embedded in ovarian stroma along with large areas of hemorrhage- H& E stain

Case 2: Another case report of 28yrs old primigravida presented to emergency with complaint of pain lowers abdominal and bleeding per vagina for 2days along with 7 weeks of amenorrhea. Her previous menstrual cycle was regular, average flow and no dysmenorrhea. On examination, the patient looked pale and her vitals were stable. On investigation her urine pregnancy test was positive, Hb% was 8.4 gm%, total leucocyte count was 8000/cu mm, platelet count was 2.0 lakh and the blood group was B positive. Bhcg level was raised. No history of any medical illness, abdominal surgery, pelvic inflammatory disease, chronic disease noted. On per vaginal examination, which the patient refused initially due to severe pain, a mass was found in the right adnexa. Uterus could not be felt separately due to the presence of guarding and rigidity. The abdomen had mild distention and was extremely tender in the suprapubic region and had marked rebound tenderness.

On transvaginal ultrasound the uterine cavity appeared with a regular thin endometrial stripe with no evidence of an intrauterine pregnancy. In the left adnexa was a tuba-ovarian mass 7x5x3 cm in diameter. The sonographic scan of the right adnexa revealed no abnormality. Transvaginal ultrasound examination demonstrated a retroverted uterus with an endometrial thickness of 14.9 mm. Transvaginal ultrasound scan also revealed a gestational sac with well-defined margins seen in the Left ovary with sac diameter of 39.7 mm. There was presence of free fluid in the pouch of Douglas. Provisional diagnosis was an ectopic pregnancy and the patient was taken for an emergency laprotomy and oophorectomy was done.

Oophorectomy specimen was sent for histopathological examination in department of pathology GGSMCH Faridkot. Macroscopic examination- ovary measured 5x3x2cm. Cut section show grey tan areas. Microscopic examination showed many degenerated chorionic villi in ovarian stroma.

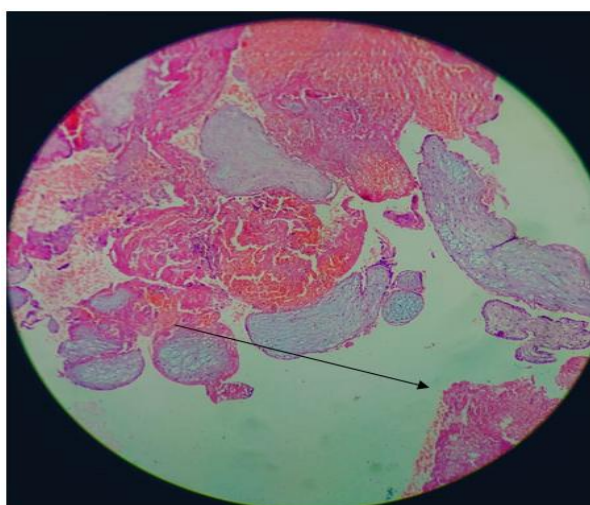


Fig-2: High power view shows Degenerated chorionic villi (arrow)- H& E stain

DISCUSSION

Primary ovarian pregnancy is very rare entity, the diagnosis of which continues to challenge the practicing clinicians.

The Spiegelberg criteria for diagnosing ovarian pregnancies are as follows. The fallopian tube on the ipsilateral side must be intact, the fetal sac must be intra ovarian, the ovary must be connected to the uterus by the ovarian ligament and the ovarian tissue must be located in the sac wall [1].

Following a natural conception, ovarian pregnancy is seen in one in 7000–16,000 deliveries, and forms almost 1–3% of all ectopic gestations [2]. With an increase in the use of assisted reproductive techniques, the cases of ovarian pregnancy are also increasing [3].

High resolution transvaginal ultrasonography (TVS) can demonstrate normal and abnormal embryonic development from the earliest stage as small as 4–5 weeks of gestation and hence is naturally the best method to detect OP at the earliest. It must however be remembered that a completely normal pelvic TVS scan may be present in 15–20% of patients with ectopic pregnancy. Hence, adequate follow-up and clinical correlation with serum human chorionic gonadotropin (HCG) values is a must.

The initial diagnosis is made on the operating table and the final diagnosis only on histopathology on the basis of the four Spiegelberg criteria, establishing that the pregnancy is limited to the ovary and does not involve the tube [1].

The cause of primary ovarian pregnancy remains obscure. Borrow concluded that chance is a reasonable explanation of ovarian pregnancies [4]. Other hypotheses have suggested interference in the release of the ovum from the ruptured follicle, malfunction of the tubes and inflammatory thickening of the tunica albugenia. Current intra uterine contraceptive device used may also be a cause [5]. The entity, empty follicle syndrome, where no oocytes are retrieved from the mature ovarian follicles with apparently normal follicular development and estradiol levels, after controlled ovarian hyperstimulation for an assisted reproductive technology cycle, despite repeated aspiration and flushing, can also be a cause for primary ovarian pregnancy[6].

The signs and symptoms of ovarian pregnancy are similar to ruptured tubal pregnancy, conditions most commonly confused with ruptured hemorrhagic corpus luteum and chocolate cyst or tubal ectopic pregnancy [5]. Rupture in the first trimester is the usual rule in an ovarian ectopic but the pregnancy may advance to full term [7].

With the improvement in the ultrasonographic skill and instrumentation, especially with the use of vaginal probe, ovarian pregnancy can be diagnosed pre-operatively [8].

No case of repeat ovarian pregnancy has been reported in contrast to approximately 15% recurrent tubal pregnancy [9]. Treatment consists of a single dose methotrexate protocol or conservative surgery. More preferred is partial oophorectomy by either laparotomy or laparoscopy [10]. Methotrexate treatment in women with tubal ectopic pregnancy shows a success rate of > 82%, with the beta HCG level between 10,000 and 14,999 mIU/ml [11], but according to the American Society of Reproductive Medicine guidelines, a beta HCG level more than 5000 mIU is a relative contraindication to medical therapy [12].

CONCLUSION

Incidence of ovarian ectopic is increasing because of availability of increased use of artificial reproductive technique, better investigations like transvaginal ultrasonography. But still preoperative diagnosis of ovarian ectopic is very difficult because of its resemblance with ruptured corpus luteal cyst, hemorrhagic ovarian cyst and tubal ectopic pregnancy. Laparoscopy followed by histopathological examination remains the gold standard for diagnosis.

REFERENCES

1. Spiegelberg, O. (1878). Zur casuistik der ovarialschwangerschaft. Arch Gynaekol, 13; 73-5.
2. Bontis, J., Grimbizis, G., Tarlastzis, B.C., Miliaras, D., Billi, H. (1997). Intrafollicular ovarian pregnancy after ovulation induction/intrauterine insemination: Pathophysiological aspects and diagnostic problems. Hum Reprod, 12; 376-8.
3. Kraemer, B., Kraemer, E., Guengoer, E., Juhasz-Boess, I., Solomayer, E. F., Wallwiener, D., & Rajab, T. K. (2009). Ovarian ectopic pregnancy: diagnosis, treatment, correlation to Carnegie stage 16 and review based on a clinical case. Fertility and sterility, 92(1), 392-e13.
4. Boronow, R. C., McElin, T. W., West, R. H., & Buckingham, J. C. (1965). Ovarian pregnancy: report of four cases and a thirteen-year survey of the English literature. American Journal of Obstetrics & Gynecology, 91(8), 1095-1106.
5. Mehmood, S. A., & Thomas, J. A. (1985). Primary ectopic ovarian pregnancy (report of three cases). Journal of postgraduate medicine, 31(4), 219.
6. Qublan, H., Tahat, Y., & Al- Masri, A. (2008). Primary ovarian pregnancy after the empty follicle syndrome: A case report. Journal of Obstetrics and Gynaecology Research, 34(3), 422-424.
7. Darbar, R. D., Reddy, C. C., Despande, N. R., & Nagalotimath, S. J. (1976). Primary Ovarian Pregnancy (a case report). J Obstet Gynecol India, 28, 310.
8. Russell, J. B., & Cutler, L. R. (1989). Transvaginal ultrasonographic detection of primary ovarian pregnancy with laparoscopic removal: a case report. Fertility and sterility, 51(6), 1055-1056.
9. Sergent, F., Mauger-Tinlot, F., Gravier, A., Verspyck, E., & Marpeau, L. (2002). Ovarian pregnancies: reevaluation of diagnostic criteria. Journal de gynecologie, obstetrique et biologie de la reproduction, 31(8), 741-746.
10. Chahtane, A., Dehayni, M., Rhrab, B., Kharbach, A., El Amrani, S., & Chaoui, A. (1993). Ovarian pregnancy. Four cases with review of the literature. Revue francaise de gynecologie et d'obstetrique, 88(1), 35-38.
11. Lipscomb, G. H., McCord, M. L., Stovall, T. G., Huff, G., Portera, S. G., & Ling, F. W. (1999). Predictors of success of methotrexate treatment in women with tubal ectopic pregnancies. New England Journal of Medicine, 341(26), 1974-1978.
12. Practice Committee of the American Society for Reproductive Medicine. (2008). Medical treatment of ectopic pregnancy. Fertility and Sterility, 90(5), S206-S212.