

## Experience of Management of Intractable Postherpetic Neuralgia on Perineum: A Case Report

Ye Ji Lee M.D., Su Yeon Kim M.D., Woo Yong Lee M.D., Ph.D., Yun-Hee Lim M.D., Ph.D.\*

Department of Anesthesia and Pain Medicine, Sanggye Paik Hospital, Inje University College of Medicine, Seoul, Korea

DOI: [10.36347/sjmcr.2021.v09i06.018](https://doi.org/10.36347/sjmcr.2021.v09i06.018)

| Received: 11.05.2021 | Accepted: 17.06.2021 | Published: 26.06.2021

\*Corresponding author: Yun-Hee Lim M.D., Ph.D

### Abstract

### Case Report

Herpes zoster is a transient disease caused by the reactivation of latent varicella zoster virus. Approximately one in every three people develops herpes zoster during their life time. Postherpetic neuralgia is the most common complication associated with herpes zoster, and it often persists for several years and even for a lifetime despite the pharmacological treatment. A 74-year-old woman experienced severe postherpetic neuralgia on the coccyx and the vulva for 18 months. Authors performed six times of fluoroscopy-guided nerve blocks including pudendal nerve block, ganglion impar block, and L1 transforaminal epidural block. With repeated nerve blocks, her numeric rating scale decreased from 8 to 4, and after 5 months, her pain was controlled only with oral medication. Postherpetic neuralgia might be treated with nerve blocks regardless of its duration.

**Keywords:** Chronic pain; Herpes zoster; Nerve block; Neuralgia, postherpetic; Nociceptive pain.

**Copyright © 2021 The Author(s):** This is an open-access article distributed under the terms of the Creative Commons Attribution 4.0 International License (CC BY-NC 4.0) which permits unrestricted use, distribution, and reproduction in any medium for non-commercial use provided the original author and source are credited.

## INTRODUCTION

Herpes zoster is an infectious disease caused by the reactivation of latent varicella zoster virus in the dorsal root ganglion [1]. Herpes zoster is typically characterized by a painful erythematous rash in the affected dermatome. Although the symptoms of acute herpes zoster resolve within 2 to 4 weeks, approximately 10-20% of patients still have persistent dermatomal pain after the skin lesion is resolved. Postherpetic neuralgia is a chronic neuropathic pain condition that persists 3 months or more after an outbreak of acute herpes zoster [2]. Most patients with postherpetic neuralgia may experience various characteristics of pain such as electric shock-like, burning or lancinating pain, severe pruritus and some patients suffer from allodynia or hyperalgesia [3].

Here, authors report a case of a patient who complained of severe, intractable pain on the coccyx and the vulva following herpes zoster infection. Authors diagnosed her pain as postherpetic neuralgia through a thorough evaluation of her history. Authors treated her successfully with fluoroscopic-guided nerve blocks. Prior to this report, we received prior written informed consent for publication from the patient.

## CASE REPORT

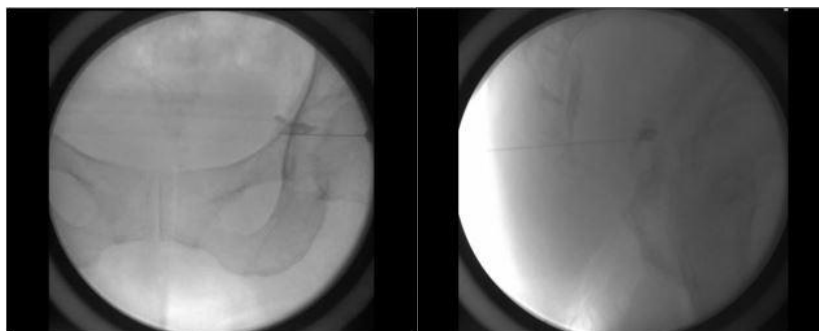
A 74-year-old woman visited the authors' pain clinic and complained for severe intractable lancinating

pain on the coccyx and vulva. She got herpes zoster 18 months prior to visiting our pain clinic. She has been treated with oral medication and repeated caudal epidural blocks in the local clinic during a 18-month period, but those were not effective. Numeric rating scale was 8 out of 10. Her pain occurred spontaneously and persisted all day. It was so severe that she could not sit on the chair, lie down, and even sleep at night. In the pain clinic, authors performed the fluoroscopic guided-pudendal nerve block with a mixture of 0.75% ropivacaine 7.5mg (1ml), normal saline 4ml and dexamethasone 1mg (Fig. 1A, Fig. 1B), and the ganglion impar block with a mixture of 0.75% ropivacaine 7.5mg (1ml) and normal saline 4ml (Fig. 2A, Fig. 2B). Authors also prescribed pregabalin (75mg), tramadol/AAP ER (37.5/325mg), and tapentadol ER (100mg) to relieve her coccyx pain.

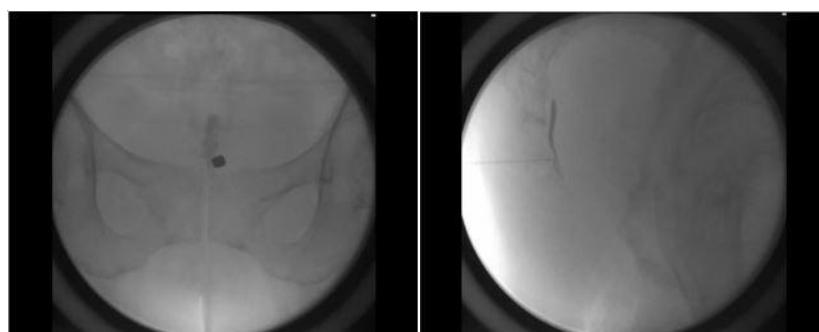
Even after the first pudendal nerve block and ganglion impar block, the pain on the coccyx was alleviated to 70%. After 1 week, the second pudendal nerve block and ganglion impar block were done, and she had relatively worse pain on the anterior vulva even though her coccyx pain had been relieved. In addition to the repetition of pudendal nerve block and ganglion impar block, L1 transforaminal epidural block on the right side was added. Then, a mixture of 0.75% ropivacaine 7.5mg (1ml), normal saline 3ml and dexamethasone 1mg was injected (Fig. 3A, Fig. 3B).

After 1 week, she told that her pain was alleviated to 50% and she could sleep at night. Authors repeated pudendal nerve block, ganglion impar block and L1 transforaminal epidural block three times more until her pain didn't seem to be relieved anymore with

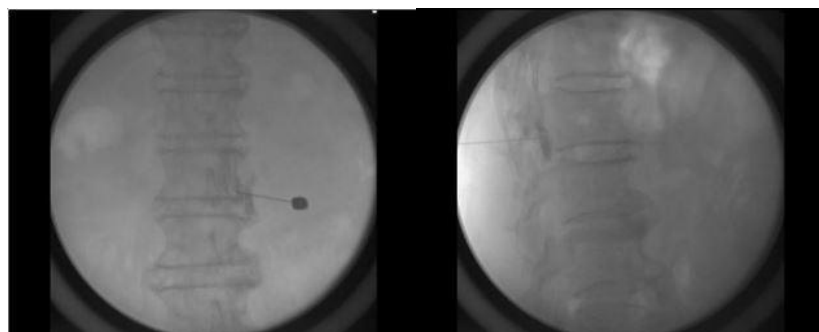numeric rating scale of 3, and thereafter, her pain on the coccyx and the vulva was well controlled with the medication. After 5 months, the pain was almost tolerable with the oral medication and she has gotten follow-up care every month in our clinic.



**Fig-1A: Pudendal nerve block, Anteroposterior view. Fig-1B: Pudendal nerve block, Lateral view**



**Fig-2A: Ganglion impar block, Anteroposterior view. Fig-2B Ganglion impar block, Lateral view**



**Fig-3A L1 transforaminal epidural block, Fig-3B L1 transforaminal epidural block, Anteroposterior view Lateral view.**

## DISCUSSION

Postherpetic neuralgia is the most common complication of herpes zoster. The pathophysiology of postherpetic neuralgia is poorly understood, but it is known that postherpetic neuralgia is developed by 'sensitization' [1]. During an acute episode of herpes zoster infection, the dormant virus becomes activated and propagates along the nerve triggering an inflammatory response which can damage peripheral and central neurons. The damaged peripheral nerve loses its ability to inhibit the nociceptive pain stimuli and generates disproportionate pain with non-painful stimuli, which is known as peripheral sensitization. The inflammation of nerve also impairs the descending

inhibitory pain pathways leading to central sensitization. Normal and excessive impulses from peripheral nociceptors generate an enhanced central response. As a result, peripheral and central sensitization create the spontaneous pain of postherpetic neuralgia [4, 5].

The initial step for management of postherpetic neuralgia is the prevention of herpes zoster with vaccination which can largely decrease the incidence of herpes zoster and postherpetic neuralgia in immunocompetent patients. The medications including tricyclic antidepressants, serotonin-norepinephrine reuptake inhibitors, anticonvulsants, opioids, topical agents are recommended for postherpetic neuralgia [6].

The interventional treatments including epidural block, intrathecal injection, and sympathetic nerve block have some effect on herpes zoster but does not appear to provide long-term effect on postherpetic neuralgia according to the recent randomized control trials [1, 7].

In the present case, authors aimed for reducing pain on the coccyx and vulva. Nerves of coccyx include somatic nerve fibers and ganglion impar which is a cluster of sympathetic nerve cells in front of the joint between the sacrum and coccyx [8]. The pudendal nerve block targets for somatic nerve fibers and the ganglion impar block targets for sympathetic nerve, and authors expected for the synergistic effect of those blocks [9, 10]. However, the pain on the coccyx had been alleviated but the pain on the anterior part of vulva had not been reduced with those nerve blocks. Authors aimed for alleviating pain on the anterior part of the vulva with L1 transforaminal epidural block. L1 nerve provides a sensation to the groin and genital regions by its branches; iliohypogastric, ilioinguinal, and genitofemoral nerves. The iliohypogastric nerve innervates the suprapubic skin and the posterolateral gluteal skin; the ilioinguinal nerve innervates the medial thigh along with the mons pubis and labium majora; and the genitofemoral nerve supplies the sensory innervation of the lateral aspect of the mons pubis and labia majora and the upper anterior part of the femoral triangle [11]. In our case, L1 transforaminal epidural block was effective for alleviating pain on the anterior part of the vulva.

Authors administered six rounds of nerve blocks and assessed her pain status after each block. Nerve blocks were effective and the patient became tolerable only with medication, even though her pain had persisted more than 18 months. In authors' opinion, even though long time had passed, a few cases of postherpetic neuralgia might remain in the reversible state in which the sensitization was not fully established so that the patient could be treated with nerve blocks. The degree and timing of sensitization may vary from person to person. However, further qualified studies are needed to prove the authors' opinion.

## CONCLUSION

Postherpetic neuralgia could be treated with an interventional method not only with the medication despite its long duration. Even though it persists for a long time, the degree of sensitization can differ from

person to person. Therefore, as with other painful condition, physicians could try practices to stop sensitization of nerves expecting reversibility regardless of the duration of postherpetic neuralgia.

## REFERENCES

1. Jeon YH. (2015) Herpes Zoster and Postherpetic Neuralgia: Practical Consideration for Prevention and Treatment. *Korean J Pain*, 28(3):177-84.
2. Mick G, Hans G. 2013 Postherpetic neuralgia in Europe: The scale of the problem and outlook for the future. *Journal of Clinical Gerontology and Geriatrics*, 4(4):102-8.
3. Saguil A, Kane S, Mercado M, Lauters R. (2017). Herpes Zoster and Postherpetic Neuralgia: Prevention and Management. *Am Fam Physician*, 96(10):656-63.
4. Fields HL, Rowbotham M, Baron R. (1998). Postherpetic neuralgia: irritable nociceptors and deafferentation. *Neurobiol Dis*, 5(4):209-27.
5. Fregoso G, Wang A, Tseng K, Wang J. (2019). Transition from Acute to Chronic Pain: Evaluating Risk for Chronic Postsurgical Pain. *Pain Physician*, 22(5):479-88.
6. Mallick-Searle T, Snodgrass B, Brant JM. (2016). Postherpetic neuralgia: epidemiology, pathophysiology, and pain management pharmacology. *J Multidiscip Healthc*, 9:447-54.
7. van Wijck AJ, Opstelten W, Moons KG, van Essen GA, Stolker RJ, Kalkman CJ, et al. (2006). The PINE study of epidural steroids and local anaesthetics to prevent postherpetic neuralgia: a randomised controlled trial. *Lancet*, 367(9506):219-24.
8. Mabrouk A, Alloush A, Foye P. (2021). Coccyx Pain. *Stat Pearls*. Treasure Island (FL): StatPearls Publishing Copyright © 2021, StatPearls Publishing LLC.
9. Gonnade N, Mehta N, Khera PS, Kumar D, Rajagopal R, Sharma PK. (2017). Ganglion impar block in patients with chronic coccydynia. *Indian J Radiol Imaging*, 27(3):324-8.
10. Kinter KJ, Newton BW. (2021). Anatomy, Abdomen and Pelvis, Pudendal Nerve. *Stat Pearls*. Treasure Island (FL): StatPearls Publishing Copyright © 2021, StatPearls Publishing LLC.
11. Kaiser JT, Lugo-Pico JG. (2021). Neuroanatomy, Spinal Nerves. *Stat Pearls*. Treasure Island (FL): Stat Pearls Publishing Copyright © 2021, StatPearls Publishing LLC.